

Case Report

Huge hard palate and nasal septum perforation as a presentation of syphilis: A case report

Shahrjerdi B¹, Mohamad F²

Abstract

A patient presented with septal and palatal perforations imposes a diagnostic challenge because various potential causes need to be established. Therefore, elucidating the cause of the septal perforation requires obtaining a thorough history. In addition, it is very important to perform necessary investigations for the patients to determine and fix the underlying disease which cause these complaints. We report a case of patient presented with palatal and septal perforations which later was confirmed to have syphilis.

Key Words: Septum, palate, perforation, medical disease, syphilis

Introduction

Any insult for instance chemical, physical, surgical, medical or iatrogenic to the normal anatomy in the upper airway passage can lead to the development of a perforation of nasal septum or palate; including cocaine abuse, chemical insult, surgery and trauma. Systemic diseases such as syphilis, tuberculosis, sarcoidosis, Wegner's granulomatosis and cancers are known to cause nasal and septal perforation, even though the incidence is very low.

Case Summary

An 80-year-old female with no known medical illness, presented to Emergency Unit with history of pain over the right cheek and nasal bridge for one week duration. It was associated with blood-stained nasal discharge from both nostrils. She also experienced low grade fever. She claimed that a number of foul smelly maggots came out from both nostrils few days prior to presentation.

Apart from that, she also claimed that she had a big hole connecting the oral and nasal cavity. It has been there for 10 years duration. She was using tissue papers to cover the hole as to prevent foods from entering nasal cavity every time during feeding.

On examination, except a low grade fever recorded her vital signs were stable. She was edentulous, with

normal oral buccal mucosa appearance. There was presence a perforation on hard palate measuring 3 x 4 cm (Figure I). The margin was smooth and healthy looking with no tissue growth, connecting the oral and nasal cavities. Nasal examination showed both sides of nasal cavities were occupied by foul smelling foreign-body liked mass with purulent discharge covering it. The mass, which was removed, consisted of small tissue pieces, pus and few live maggots. Septal perforation was seen, involving most parts of cartilaginous septum, leaving only 5mm of posterior strut of septum (Figure II). The remaining septum was with healthy, smooth margin. Both inferior turbinates were absent and necrotic mucosa of the middle turbinates were identified, covered with slough. Nasopharynx and otoscopic examinations were normal. There was no neck node palpable and the chest radiograph was unremarkable.

She was started on intravenous antibiotics in view of nasal cavity infection secondary to foreign body. Other investigations were ordered to determine primary cause of the palatal and septal perforations. There were negative for tuberculosis and leprosy, with normal erythrocyte sedimentation rate and negative for c-ANCA, p-ANCA, HBS Ag, HCV Ab and HIV. However it was reactive for VDRL/TPHA and biopsy of the lateral nasal cavity revealed just a

1. Behzad Shahrjerdi
2. Irfan Mohamad

Department of Otorhinolaryngology-Head & Neck Surgery, School of Medical Sciences, Universiti Sains Malaysia Health Campus, 16150 Kota Bharu, Kelantan, Malaysia.

Corresponds to: Dr Behzad Shahrjerdi, Department of Otorhinolaryngology-Head & Neck Surgery, School of Medical Sciences, Universiti Sains Malaysia Health Campus, 16150 Kota Bharu, Kelantan, Malaysia. **Email:** irfan@kb.usm.my

Huge hard palate and nasal septum perforation as a presentation of syphilis: A case report

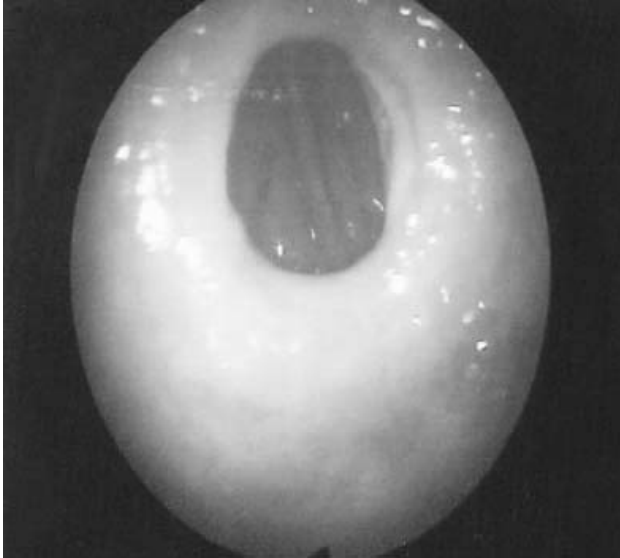

Figure I: A palatal perforation as seen from oral cavity

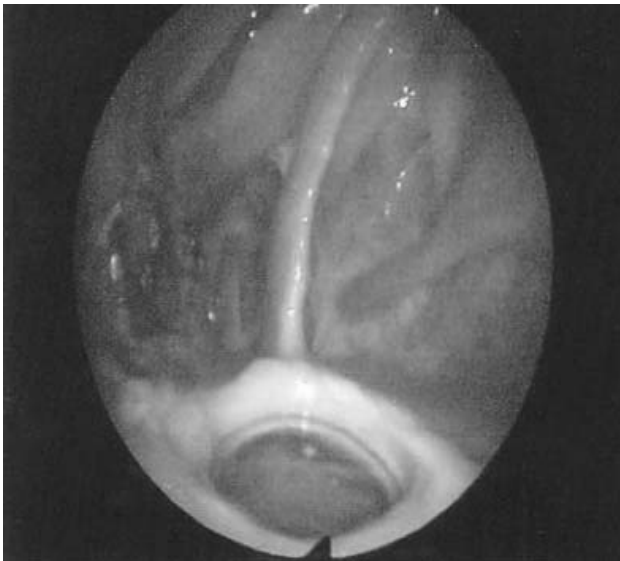


Figure II: Huge septal perforation leaving the posterior strut as seen from the right nostril. Also the absence of normal inferior turbinates on both sides noted.

granulation tissue. She was diagnosed to have latent syphilis and treatment inclusive of Benzathine Penicillin G, 7.2 million units total, administered as 3 doses of 2.4 million units, each at 1-week intervals was commenced. She was planned to be followed up at 3,6 and 12 months after treatment for VDRL test. Besides, prosthesis made for covering the palatal perforation as a part of denture.

Discussion

Nasal septum and palatal perforation are uncommon phenomena, and it is even rarer to occur simultaneously. They tend to present in isolation for example

in case of cleft palate,¹ or chronic granulomatous nasal diseases causing septal perforation.² Unhealthy lifestyle habits such as cocaine use and inhalation of recreational drugs put individuals at increase risk of developing a nasal and palatal perforation³. A thorough medical history is essential in evaluation of patient because septal and palatal perforations could be associated with many systemic diseases. Inflammatory diseases such as collagen vascular diseases, sarcoidosis and Wegener granulomatosis may cause septal and palatal perforations. In addition, infectious processes such as tuberculosis, syphilis and fungal diseases may result in septal and palatal perforations. Rarely, septal perforation is the initial finding of sinunasal malignancy.^{2,4} It has also been reported following intranasal steroid therapy.⁵

Septal or palatal perforations can cause significant morbidity. The symptoms associated with septal perforation include nasal congestion or obstruction, nasal crusting and discharge, recurrent epistaxis, and a whistling sound from the nose.⁶ In palatal perforation it can cause the regurgitation of foods to the nasal cavity during feeding. In addition to symptoms related to septal and palatal perforations, manifestation of the disease process which caused the perforation (e.g. lupus, Wegener granulomatosis) may also carry significant morbidity. In our case, the patient had used tissue paper to cover the hole on the palate. Incidentally, the some part of it had been left and acted as foreign body. This induced foreign body reaction evidenced by foul smelly discharge and presence of live maggots.

The causative organism of syphilis is a spirochete bacterium, *Treponema pallidum*. The spread is by direct contact with a skin ulcer (chancre) of an infected person. This usually occurs through sexual contact with mucous membrane of genital area or mouth, but the disease also can be transmitted via a broken skin on other parts of body and through contact with infected blood. However, Therefore, it can be transmitted non-sexually unlike other venereal disease in that.⁷⁻¹⁰

In our case, the patient has not had any history of common syphilis symptoms. Her husband had passed away about fifteen years ago and there was no case of known syphilis in her family. Besides, she denies any blood transfusion history. Sometimes the presentation of syphilis imitates symptoms mimic those of many other diseases for example; herpes

infection, lymphoma, leprosy, chancroid, meningitis, sarcoidosis, tuberculosis and granulomatous diseases.¹¹ That is why syphilis is known as great imitator.

The natural history of untreated syphilis could be divided into four stages: primary, secondary, latent and tertiary. The primary and secondary stages usually last 1 to 2 years and the patient can spread the disease to others. These stages pass rather quickly and are often unidentified because of painless skin lesions. While the affected individual may think that the disease is cured, the disease actually progressed. Latency may last from a few years to many years before the destructive lesions of tertiary syphilis manifest. The disease is no longer contagious in latent and tertiary stages, as in our patient. However at this stage, serious complications such as damages to internal organs, mental disorders and death can result. The tertiary stage can last many years.⁷⁻¹⁰

Diagnosis of syphilis can be established from blood tests including Venereal Disease Research Laboratory test (VDRL) and Treponemal Pallidum Hemagglutination Assay (TPHA). An increasing number of have become available Treponemal Enzyme ImmunoAssays (EIAs) are very suitable to detect syphilis antibodies. However, if Treponemal

EIA is used for screening, an alternative treponemal test, such as TPHA, must be applied to confirm the diagnosis.¹²⁻¹⁶

Treatment in primary and secondary stages involves a single injection of an antibiotic (penicillin). Most of the treated individuals can no longer transmit the disease after 24 or 48 hours. Sexual activity must be avoided during this time. Partners of patient should also be treated as well. Individuals who have been exposed to syphilis can be treated by an injection of antibiotic immediately to prevent infection by the bacteria. In later stages, longer treatment with antibiotic is needed. Parenteral penicillin continues to be the best of choice for treatment of all stages of syphilis. For the patients with allergy to penicillin, erythromycin, azithromycin, doxycycline or tetracycline can be applied.^{17,18}

After treatment the patient should be followed up by examinations and reaginic tests (VDRL/RPR) at 3, 6 and 12 months and annually thereafter until the test is non-reactive. Treatment failure is defined as failure of titers to decline by 4 fold at 6 months for primary and secondary and 12 months for latent and tertiary syphilis.¹⁹ In these cases, retreatment is required.

References

1. Von Arx DP, Cash AC. Spontaneous palatal fenestration: review of the literature and report of a case. *Br J Oral Maxillofac Surg* 2000;**38**(3):235-7. <http://dx.doi.org/10.1054/bjom.1999.0122> PMID:10864733
2. Fairbanks DN, Fairbanks GR. Nasal septal perforation: prevention and management. *Ann Plast Surg* 1980;**5**(6):452-9. <http://dx.doi.org/10.1097/00000637-198012000-00007> PMID:7469325
3. Seyer BA, Grist W, Muller S. Aggressive destructive midfacial lesion from cocaine abuse. *Oral Surg Oral Med Oral Pathol Oral Radiol Endod* 2002;**94**(4):465-70. <http://dx.doi.org/10.1067/moe.2002.126020> PMID:12374921
4. Cottrell DA, Mehra P, Malloy JC, Ghali GE. Midline palatal perforation. *J Oral Maxillofac Surg* 1999;**57**(8):990-5. [http://dx.doi.org/10.1016/S0278-2391\(99\)90023-X](http://dx.doi.org/10.1016/S0278-2391(99)90023-X)
5. Soderberg-Warner ML. Nasal septal perforation associated with topical corticosteroid therapy. *J Paediatr* 1984;**105**(5):840-1. [http://dx.doi.org/10.1016/S0022-3476\(84\)80320-0](http://dx.doi.org/10.1016/S0022-3476(84)80320-0)
6. Bhattacharyya N. Clinical Symptomatology and Paranasal Sinus Involvement With Nasal Septal Perforation. *Laryngoscope* 2007;**117**(4):691-4. <http://dx.doi.org/10.1097/01.mlg.0000256455.01473.72> PMID:17415140
7. Dupin N, Jdid R, N'Guyen YT, Gorin I, Franck N, Escande J P. Syphilis and gonorrhoea in Paris: the return. *AIDS* 2001;**15**(6):814-5. <http://dx.doi.org/10.1097/00002030-200104130-00026> PMID:11371705
8. Fenton KA, Nicoll A, Kinghorn G. Resurgence of syphilis in England: time for more radical and nationally coordinated approaches. *Sex Transm Infect* 2001;**77**(5):309-10. <http://dx.doi.org/10.1136/sti.77.5.309> PMID:11588268 PMCid:1744387

Huge hard palate and nasal septum perforation as a presentation of syphilis: A case report

9. Hopkins S, Lyons F, Coleman C, Courtney G, Bergin C, Mulcahy F. Resurgence in infectious syphilis in Ireland: an epidemiological study. *Sex Transm Dis* 2004;**31**(5):317-21. <http://dx.doi.org/10.1097/01.OLQ.0000123653.84940.59> PMID:15107636
 10. Hughes G, Paine T, Thomas D. Surveillance of sexually transmitted infections in England and Wales. *Euro Surveill* 2001;**6**(5):71-80. PMID:11679688
 11. Fitzgerald F. The great imitator, syphilis-Medical Staff Conference, University of California, San Francisco. *West J Med* 1981;**134**:424-32. PMID:7257350 PMCid:1272769
 12. Egglestone SI, Turner AJ. Serological diagnosis of syphilis. *Commun Dis Public Health* 2000;**3**(3):158-62. PMID:11014025
 13. Wicher K, Horowitz HW, Wicher V. Laboratory methods of diagnosis of syphilis for the beginning of the third millennium. *Microbes Infect* 1999;**1**(12):1035-49. [http://dx.doi.org/10.1016/S1286-4579\(99\)80521-8](http://dx.doi.org/10.1016/S1286-4579(99)80521-8)
 14. French P, Gomberg M, Janier M, Schmidt B, van Voorst Vader P, Young H; IUSTI: 2008 European Guidelines on the Management of Syphilis. *Int J STD AIDS* 2009;**20**(5):300-9. <http://dx.doi.org/10.1258/ijsa.2008.008510> PMID:19244539
 15. Larsen SA, Steiner BM, Rudolph AH. Laboratory diagnosis and interpretation of tests for syphilis. *Clin Microbiol Rev* 1995;**8**(1):1-21. PMID:7704889 PMCid:172846
 16. Leão JC, Gueiros LA, Porter SR. Oral manifestations of syphilis. *Clinics* 2006;**61**(2):161-6. PMID:16680334
 17. Goh BT, van Voorst Vader PC. European guideline for the management of syphilis. *Int J STD AIDS* 2001;**12**(Suppl. 3):14-26. <http://dx.doi.org/10.1258/0956462011924065> PMID:19244539
 18. Augenbraun MH. Treatment of syphilis, 2001: nonpregnant adults. *Clin Infect Dis* 2002;**35**:S187-90 <http://dx.doi.org/10.1086/342106> PMID:12353205
 19. Romanowski B, Sutherland R, Fick GH, Mooney D, Love EJ. Serologic response to treatment of infectious syphilis. *Ann Intern Med* 1991;**114**:1005-9. PMID:2029095
-