

Original article:

Investigation of the morphology of longus colli among patients with neck pain using ultrasonography – a preliminary study

Hussain RI¹, Henry LJ², Ramli A³, Othman SN⁴, Mohan V⁵, Mohamad HF⁶

Abstract

Objective: Longus colli provides stability to cervical spine during movements. In clinical practice, the clinicians teach exercises to longus colli to manage neck pain. The aim of this study was to investigate differences in thickness or anterior-posterior dimension (APD), shape ratio and contraction ratio of longus colli between subjects with neck pain and healthy controls. **Materials and methods:** A total of 12 subjects (6 with neck pain and 6 healthy controls) were recruited by predefined selection criteria. Ultrasound imaging of bilateral longus colli was conducted at the level C5-C6. Anterior-posterior dimension (APD) and lateral dimension (LD) were measured using Ultrasonography. Shape ratio (LD/APD) and contraction ratio (APD during contraction/APD during rest) were calculated. Mann-Whitney U test was used to compare the thickness of longus colli between healthy and neck pain subjects. **Results and discussion:** The results showed that the subjects with neck pain had smaller APD (Mean Rank=4.83, n=6) than healthy subjects (Mean Rank=8.17, n=6), $U=16.00$, $z=-1.601$ (corrected for ties), $p=0.109$, two tailed. Also, shape ratio showed higher values in neck pain subjects (Mean Rank=7.17, n=6) than normal subjects (Mean Rank=5.83, n=6), $U=14.00$, $z=-0.641$ (corrected for ties) $p=0.522$, two tailed. In addition, contraction ratio was smaller in neck pain subjects (Mean Rank=4.83, n=6) than those healthy subjects (Mean Rank=8.17, n=6), $U=8.00$, $z=-1.601$ (corrected for ties) $p=0.109$, two tailed.

Conclusion: There is a trend of reduced size of longus colli with the median of APD and smaller contraction ratio among patients with neck pain when compared to healthy controls.

Keywords : longus colli, neck pain, ultrasonography, thickness, muscle

Introduction

The cervical spine is surrounded by a complex arrangement of muscles that contribute to static and dynamic control of the head and neck.¹ Deep neck flexor provides stabilization of the cervical spine in anticipation of movements of the cervical spine.¹

Among the deep neck flexor muscles, the longus colli and longus capitis are considered as the primary stabilizers of the neck.² The longus colli muscle consists of three parts which originates from the anterior aspect of the vertebral bodies from C5 to T3, the anterior tubercle of the transverse processes of

-
1. Rizuana Iqbal Hussain, Department of Radiology, Faculty of Medicine, Universiti Kebangsaan Malaysia Medical Centre, Kuala Lumpur, Malaysia
 2. Leonard Joseph Henry
 3. Ayiesah Ramli
 4. Saidatul Nur Othman
Physiotherapy Program, School of Rehabilitation Science, Faculty of Health Sciences, Universiti Kebangsaan Malaysia, Kuala Lumpur, Malaysia
 5. Vikram Mohan Department of Physiotherapy, Faculty of Health Sciences, Universiti Teknologi MARA, Puncak Alam, Selangor, Malaysia
 6. Hanif Farhan Mohamad Occupational Therapy Program, School of Rehabilitation Science, Faculty of Health Sciences, Universiti Kebangsaan Malaysia, Kuala Lumpur, Malaysia

Corresponds to:

Leonard Joseph H, Senior Lecturer in Physiotherapy, Faculty of Allied Health Sciences Universiti Kebangsaan, Malaysia Jalan Raja Muda Abdul Aziz, Kuala Lumpur 50300, Malaysia, Email: leonard-joseph85@hotmail.com

C3-C5 and the sides of T1-T3 vertebral bodies.³ The longus colli muscle inserts on the anterior sides of C2-C4 vertebrae, the anterior tubercle of the atlas and the transverse processes of C5 and C6.³ The longus colli have a high density of muscle spindles, which are clustered and concentrated anterolaterally at the cervical spine.⁴ The dense spindles of longus colli are involved in enhancing stability of cervical spine as well as in maintaining cervical lordosis.⁴

Evidence had suggested that deep neck muscles were associated with neck dysfunction and cervical pain.^{5,6} Approximately 16.5% of women and 10.7% of men reported neck pain at least once a month.⁷ In cervical pain or neck pain, the superficial neck muscles masked the action of deep neck muscles in stabilizing the cervical spine.² This led to inability of the deep neck muscle to counteract the loading imposed by cervical lordosis.^{8,9} A systematic review on low back pain speculated the possibilities of physical deconditioning and disuse of lumbar multifidus muscle.¹⁰ Hence, a similar pattern of disuse muscle atrophy and weakness of longus colli may exist among patients with neck pain.

Previous studies revealed reduced thickness of longus colli on ultrasound imaging.^{11,12} Other studies had reported structural changes and reduced size of deep neck muscle among patients with neck pain.^{12,13} The thickness of longus coli, which is also the anterior-posterior dimension (APD) is defined as the inferior distance from the superior to inferior border of the longus colli.¹⁴ Meanwhile width or lateral dimension (LD) is defined as the distance from the lateral to medial border of the longus colli.^{15,16} Shape ratio which describes muscle shape is calculated as LD divided by APD (LD/APD). Shape ratio describes muscle shape.¹⁷ Contraction ratio is calculated by muscle thickness during contraction divided by muscle thickness during rest. It indicates whether an individual can sustain a stable phase during contraction.¹⁸

About the past studies conducted over longus colli muscle and neck pain, the researchers did not look into contraction ratio, APD and LD of longus colli during contraction.^{12,13,19} Till date, no studies had

investigated the contraction ratio of longus coli among neck pain patients. However, a recent past study explored the contraction ratio of internal oblique and transverses abdominis among low back pain patients and concluded that contraction ratio of the stabilization muscles were reduced among low back pain patients.¹⁸ Thus, the researchers in the current study developed the interest to investigate the contraction ratio values of the longus colli among subjects with neck pain. As longus coli is the muscle involved crucially in providing stability to cervical spine, the findings of the current study would help to interpret the stabilizing role of the muscle in providing stability to cervical spine among subjects with neck pain. Therefore, the current study measured the APD and LD of longus colli during rest and contraction using real time ultrasound imaging.

Nowadays, ultrasound technology is widely used, both in the aspect of diagnostic and rehabilitation purposes.⁶ Ultrasound is cost effective in assessing muscles and related soft tissue morphology,⁶ in the measurement of muscle size of neck extensor muscle,²⁰ to visualize neck muscles and to obtain thickness values at rest and during different states of contraction for cervical multifidus.¹⁷ Study reported that ultrasound has high reliability in taking and interpreting images of longus colli.¹⁷ The objective of the current study is to compare the longus colli between healthy and neck pain subjects during rest and contraction. Thus, contraction ratio of the longus colli can be calculated. This study hypothesized that APD, LD and contraction ratio of the longus colli were significantly reduced in neck pain subjects when compared with matched healthy controls.

Materials and methods

Subjects and Demography Data

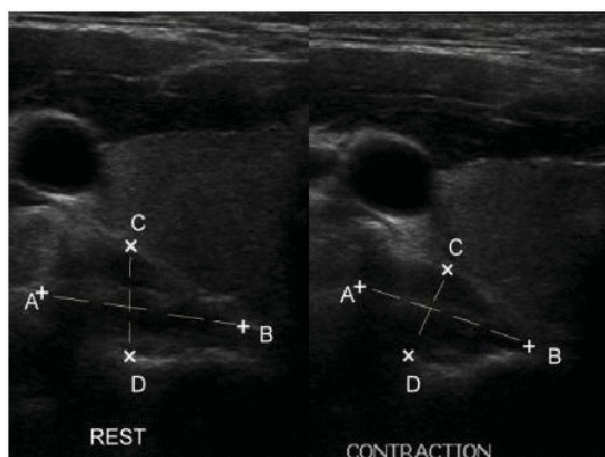
This is a pilot cross sectional study conducted among a total of 12 subjects (six healthy subjects and six neck pain subjects). Subjects with bilateral neck pain were recruited at the physiotherapy department, from university teaching hospital. The subjects with neck pain were included if they were presented with neck pain of more than three months, a history of cervical disc herniation, cervical spondylosis, cervical spine fracture and post surgical conditions of the neck. Subjects were excluded if they presented with lower back pain, migraine and neck pain less than three months for neck pain

group. The healthy subjects matched with age and gender was recruited from the volunteers who accompanied the patients to a university teaching hospital. The subjects completed the written informed consent form. Demography data including name, sex, height, weight, medical history and duration of pain were documented. The research was approved by ethics committee.

Ultrasonography Protocol

This study followed the protocol developed by Javanshir et al to measure the thickness of longus colli using ultrasonography.¹³ The muscle thick-

Fig. 1: Ultrasonogram of longus colli; AB= lateral dimension (LD); CD =anterior-posterior dimension (APD)



ness of longus colli was measured by a real time diagnostic ultrasonography (Philips HD 11 system U/S scanner (Koninklijke Philips Electronics, Netherlands) using 12MHz, B mode, linear probe). Subjects were in full crook lying on an examination table with both arms crossed and head in neutral position. A folded towel was placed under the occiput, so the head lay 3-4 cm higher than the examination table. The top of the thyroid cartilage were palpated, 2 cm below this level was marked. The transducer was placed perpendicular to the vertical axis of the neck. The transducer was moved laterally 1 cm for each side. The image of longus colli were scanned and taken at the C5-C6 level.¹³ There was no overlap between the longus colli and the longus capitis muscle, as the longus capitis muscle runs more laterally and attaches to the anterior tubercle of

C6.¹⁹ The measurement was taken for right and left longus colli because previous study reported neck pain was frequently presented bilaterally or in the dominant arm.²¹ The thickness or APD, width or LD of the longus colli were identified and assessed as the superior to the inferior border for APD and width of the lateral to medial border for LD.¹⁴ The subjects were asked to do cranio-cervical flexion movement to engage contraction of longus colli and three measurements were performed. Figure 1 indicates the anterior-posterior and lateral measurements of longus colli. The average of the three measurements was taken as final measure for data analysis.

Statistical analysis

Data were analyzed with Statistical Package for the Social Sciences version 17.0. Means and standard deviations were calculated. The skewness and kurtosis values revealed that all the data were not in normal distribution. The differences in the thickness and contraction ration of longus colli between healthy and neck pain subjects were assessed with Mann-U Whitney test. Cohen ‘d’ effect size was calculated to understand the clinical effect of the study findings. Level of significance was set at p value less than 0.05.

Results

The demographic characteristics of the study subject are indicated in (Table 1). A total of 12 subjects (six neck pain and six healthy subjects of matched control) participated in this study. Ten subjects were right handed and two were left handed. There was no significant difference in the demographic characteristics of the subjects with neck pain and healthy controls.

Table 1: Demographic characteristics of the subjects in mean and standard deviation (n=12)

	Healthy	Neck pain	P
Age (years old)	34.33±6.50	42.17±8.11	0.170
Weight (kg)	60.42±12.32	68.83±11.23	0.818
Height (cm)	162.75±10.35	166.17±4.54	0.726
BMI (kg/m ²)	22.79±4.21	24.98±4.46	0.134

Comparison of Longus Colli Muscle Size between Healthy and Neck Pain Subjects

The median values (M) and interquartile range (IQR) f of the thickness and contraction ratio of longus colli size were shown in (Table 2). The result indicated that APD during contraction for longus

Structural changes of longus colli in neck pain

colli in neck pain subjects (Mean Rank=4.83, n=6) were lesser than those of the healthy subjects (Mean Rank=8.17, n=6), $U=16.00$, $z=-1.601$ (corrected for ties), $p=0.109$, two tailed. Although the above finding is not statistically significant, the observed effect size can be described as “medium” ($r=0.462$).

Similarly, the measurements of LD during rest and contraction of longus colli in neck pain subjects (Mean Rank=7.17, n=6) was higher than those of the healthy subjects (Mean Rank=5.83, n=6), $U=14.00$, $z=-0.641$ (corrected for ties), $p=0.522$, two tailed with low effect size ($r=0.185$).

Table 2: Anterior-posterior dimension (APD), lateral dimension (LD), shape ratio and contraction ratio in healthy and neck pain subjects

Measurement	Median (IQR)	
	Healthy	Neck Pain
APD rest	0.8385 (0.7383 – 1.0687)	0.8443 (0.7593 – 0.9403)
LD rest	1.4533 (1.2900 – 1.7225)	1.5200 (1.4050 – 1.5983)
Shape ratio rest	1.7889 (1.6317 – 1.8589)	1.8397 (1.5345 – 2.1026)
APD contraction	0.9533 (0.7645 – 1.1043)	0.8233 (0.7178 – 0.8887)
LD contraction	1.5900 (1.4075 – 1.8017)	1.7000 (1.5775 – 1.7525)
Shape ratio contraction	1.6526 (1.5194 – 2.1057)	2.0256 (1.9429 – 2.3466)
Contraction ratio	1.0866 (0.9274 – 1.1302)	0.9365 (0.8632 – 1.0376)

The Mann-Whitney U test was used to compare longus colli muscle between healthy (N=6) and neck pain subjects (N=6) during rest and contraction and the results are shown in (Table 3).

Table 3: Comparison of anterior-posterior dimension (APD), lateral dimension (LD), shape ratio and contraction ratio of longus colli size between healthy and neck pain subjects

Measurement	Group	Mean Rank	p ^a	Z	Effect size ^b
APD ND rest	Healthy	6.83	0.749	-0.320	-0.092 ^b
	Neck pain	6.17			
LD ND rest	Healthy	5.83	0.522	-0.641	-0.185 ^b
	Neck pain	7.17			
Shape ratio ND rest	Healthy	5.83	0.522	-0.641	-0.185 ^b
	Neck pain	7.17			
APD ND contraction	Healthy	8.17	0.109	-1.601	-0.462 ^b
	Neck pain	4.83			
LD ND contraction	Healthy	5.83	0.522	-0.641	-0.185 ^b
	Neck pain	7.17			
Shape ratio ND contraction	Healthy	4.83	0.109	-1.601	-0.462 ^b
	Neck pain	8.17			
Contraction ratio ND	Healthy	8.17	0.109	-1.601	-0.462 ^b
	Neck pain	4.83			

^a The Mann-Whitney test was used for the comparison

^b correlation coefficient

APD = anterior posterior dimension, LD = lateral dimension, D = dominant, ND = non-dominant

Furthermore, results from Mann-Whitney U showed that shape ratio of longus colli during rest among neck pain subjects (Mean Rank=7.17, n=6) was higher than those of the healthy subjects (Mean Rank=5.83, n=6), $U=14.00$, $z=-0.641$ (corrected for ties) $p=0.522$, two tailed with low effect size ($r=0.185$). Similarly, Mann-Whitney U indicated that shape ratio of longus colli during contraction was higher among neck pain subjects (Mean Rank=8.17, n=6) when compared with healthy subjects (Mean Rank=4.83, n=6), $U=8.00$, $z=1.601$ (corrected for ties) $p=0.109$, two tailed. The observed effect size for this finding is described as “medium” ($r=0.462$).

However, Mann-Whitney U test indicated that contraction ratio of longus colli among neck pain subjects (Mean Rank=4.83, n=6) was lesser than those of the healthy subjects (Mean Rank=8.17, n=6), $U=8.00$, $z=-1.601$ (corrected for ties) $p=0.109$, two tailed. This effect can be described as “medium” ($r=0.462$).

Discussion

The current study investigated the changes in APD of the longus colli among patients of neck pain and healthy subjects during rest and contraction. Prior to the commencement of the data collection, the intra rater reliability of the procedure to measure thickness of longus colli was conducted. The reliability test showed excellent reliability for APD (ICC ranging between 0.86 and 0.97) and fair to excellent reliability (ICC ranging between 0.46 and 0.81). The reliability result for the longus colli measurement suggested that ultrasound could be a reliable tool for longus colli imaging. The current study found APD values decreased in neck pain subjects when compared with healthy subjects. During rest, the Median APD values in neck pain patients (Median=0.8443, IqR=0.7593-0.9403) were lesser when compared with healthy subjects (Median=0.8385, IqR=0.7383-1.0687). Similar trend of reduced APD size was also observed during contraction of longus colli in neck pain patients (Median=0.8233, IqR=0.7178-0.8887) when compared with healthy subjects (Median=0.9533, IqR=0.7645-1.1043). The current study findings could be compared with a previous study on APD changes among neck pain patients.^{9,11} The study done by Javanshir et al. also showed reduction in APD values among neck pain patients. However, studies done by Javanshir et al. measured APD during rest only.^{11,13} In this

current study, APD was measured at rest and contraction. Deep neck flexor was shown to be more active in contraction to provide stability to cervical spine.¹² Furthermore, increased size of APD was reported in cervical multifidus among asymptomatic populations during contraction (rest=0, 25% load= 8.11 ± 4.98 , 50% load= 13.52 ± 8.23).⁹ Similarly, in the current study, the size of APD was shown higher in healthy subjects during rest and contraction.

Reduced in APD size might indicate muscle atrophy.¹² Previous research suggested natural ageing process might be associated with physiological ageing of the cervical spine.²² However, the mean age of neck pain subjects for the current study were 42.17 ± 8.11 (Mean \pm SD) years. Hence, in this study, reduced size of APD might be as a result of structural changes in neck pain patients, but not due to physiological ageing. In this study, LD of the longus colli was measured to estimate the shape ratio as the size of LD was higher in neck pain patients than healthy subjects. This increased of LD was also reported earlier.^{11,13} LD of longus colli were found higher in neck pain subjects (Median=1.52) if compared to normal subjects (Median=1.4533) during rest. The study done by Javanshir et al. also demonstrated neck pain subjects (dominant, mean \pm SD=1.25 \pm 0.18; non-dominant, mean \pm SD=1.22 \pm 0.19) has larger LD of longus colli than those in healthy subjects (dominant, mean \pm SD=1.17 \pm 0.22; non-dominant, mean \pm SD=1.06 \pm 0.15).¹¹ One study also found that the lateral boundary of cervical multifidus was not clear on ultrasound imaging.⁶ Moreover, muscle tissues in older adults are partly replaced by fat and connective tissues that caused difficulty in measuring posterior neck muscles.^{23,24} This was reported to affect the echogenicity of the ultrasound because ultrasound has high echogenicity for connective tissues than muscles.¹⁷ However, in the current study, the images of LD were clearly obtained without difficulty.

In addition, shape ratio was found greater in neck pain patients (Median=1.8397) when compared to healthy subjects (Median=1.7889) during rest. The shape ratio was also measured during contraction and it was found greater in neck pain patients (Median=2.0256) than in healthy subjects (Median=1.6526) during contraction. Previous study

presented that the shape ratio of cervical multifidus in neck pain subjects (right, mean±SD=1.70±0.32; left, mean±SD= 1.68±0.15) during rest were larger than healthy subjects (right, mean±SD=1.68±0.19; left, mean±SD=1.58±0.14).⁶ Evidence also supported that the semispinalis capitis muscle shape ratio in wrestlers (right, mean±SD=6.12±0.98; left, mean±SD=5.93±0.50) were smaller than those in control subjects (right, mean±SD=6.38±0.68; left, mean±SD=6.45±0.72).²² Javanshir et al also revealed increased in shape ratio of longus colli in neck pain subjects.^{11,13} Greater values for shape ratio indicate the subject have flatter muscles, while smaller shape ratio indicates the subject have rounder muscles.¹¹ Wrestlers have developed neck muscles and regarded as smaller shape ratio. Thus, neck pain patients have flatter muscles. The result seems to suggest the existence of muscle atrophy in neck pain subjects.

This study found out that there was deficit in contraction ratio among neck pain subjects. Previous study demonstrated reduced contraction ratio of transverse abdominus muscle (1.26 cm – 1.01 cm, p=0.02) and internal oblique muscle (1.42 cm – 1.22 cm, p=0.01) in chronic low back pain patients.²⁵ The current result showed the neck pain subjects exhibited a similar reduced pattern of reduced contraction ratio. There were no other reported studies that had investigated the contraction ratio among neck pain patients. As this is the first study that had investigated contraction ratio among neck pain, the current study findings were not comparable with

past studies. However, the clinical finding of reduction in contraction ratio was in line conceptually with the similar finding observed among patients with low back pain.²⁵

Limitation of the study

The major limitation of the study is the small sample size. However, this study was structured as a pilot study; keeping the fact in mind that contraction ratio was attempted first time among neck pain patients. In the future, this study should be conducted with a larger sample size. Secondly, the subjects did not receive any familiarization in cranio-cervical flexion movements which was used to contract deep neck flexor. Hence, there are possibilities that the subjects used the other muscles around the neck. Future studies may consider to familiarize the cranio-cervical flexion movements and to train deep neck flexor contraction prior to data collection.

Conclusion

This preliminary study shows a trend of reduced size of longus colli and smaller contraction ratio among patients with neck pain when compared to healthy controls. Further study with greater sample size is warranted to confirm the pattern of structural changes in longus colli among neck patients.

Acknowledgements

The authors wish to thank the staff of the radiology department of Universiti Kebangsaan Malaysia Medical Centre for their assistance in completion of this study. The authors also would like to thank the staff of the physiotherapy department for their help in data collection for this research.

References

1. Falla D, Bilenkij G, Jull G. Patients with chronic neck pain demonstrate altered patterns of muscle activation during performance of a functional upper limb task. *Spine* 2004; **29** (13):1436-40 <http://dx.doi.org/10.1097/01.BRS.0000128759.02487.BF> PMID:15223935
2. Jull G, Kristjansson E, Dall'Alba P. Impairment in the cervical flexors: a comparison of whiplash and insidious onset neck pain patients. *Man Ther* 2004; **9** (2):89-94 [http://dx.doi.org/10.1016/S1356689X\(03\)00086-9](http://dx.doi.org/10.1016/S1356689X(03)00086-9)
3. Shuenke M, Schuts M, Schumacher U. THIEME Atlas of Anatomy. New York, NY: Thieme, 2006
4. Boyd-Clark LC, Briggs CA, Galea MP. Muscle spindle distribution, morphology, and density in longus colli and multifidus muscles of the cervical spine. *Spine* 2002; **27** (7):694-701 <http://dx.doi.org/10.1097/00007632-200204010-00005> PMID:11923661
5. Hayashi N, Masumoto T, Abe O, Aoki S, Ohtomo K, Tajiri Y. Accuracy of abnormal paraspinal muscle findings on contrastenhanced MR images as indirect signs of unilateral cervical root avulsion injury. *Radiology* 2002; **223** (2):397-402 <http://dx.doi.org/10.1148/radiol.2232010857> PMID:11997544
6. Kristjansson E. Reliability of ultrasonography for the cervical multifidus muscle in asymptomatic

- and symptomatic subjects. *Man Ther* 2004; **9** (2):83-88 [http://dx.doi.org/10.1016/S1356-689X\(03\)00059-6](http://dx.doi.org/10.1016/S1356-689X(03)00059-6)
7. Chiu TT, Leung AS, Lam P. Neck pain in Hong Kong: A telephone survey on consequences and health service utilization. *Spine* 2010; **35** (21):E1088-95 <http://dx.doi.org/10.1097/BRS.0b013e3181e219fd> PMID:20838266
 8. Kristjansson E, Jonsson H Jr. Is the sagittal configuration of the cervical spine changed in women with chronic whiplash syndrome? A comparative computer-assisted radiographic assessment. *J Manipulative Physiol Ther* 2002; **25** (9):550-5 <http://dx.doi.org/10.1067/mmt.2002.128371> PMID:12466772
 9. Lee JP, Tseng WY, Shau YW, Wang CL, Wang HK, Wang SF. Measurement of segmental cervical multifidus contraction by ultrasonography in asymptomatic adults. *Man Ther* 2007; **12** (3):286-294 <http://dx.doi.org/10.1016/j.math.2006.07.008> PMID:16987692
 10. Smeets RJ, Wade D, Hidding A, Van Leeuwen PJ, Vlaeyen JW, Knottnerus JA. The association of physical deconditioning and chronic low back pain: A hypothesis-oriented systematic review. *Disabil Rehabil* 2006; **28** (11):673-693 <http://dx.doi.org/10.1080/09638280500264782> PMID:16809211
 11. Javanshir K, Rezasoltani A, Mohseni-Bandpei MA, Amiri M., Ortega-Santiago R, Fernández-de-Las-Pe-as C. Ultrasound assessment of bilateral longus colli muscles in subjects with chronic bilateral neck pain. *Am J Phys Med Rehabil* 2011; **90** (4):293-301 <http://dx.doi.org/10.1097/PHM.0b013e31820173e5> PMID:21173685
 12. Jull GA, O'Leary SP, Falla DL. Clinical assessment of the deep cervical flexor muscles: the craniocervical flexion test. *J Manipulative Physiol Ther* 2008; **31** (7):525-33 <http://dx.doi.org/10.1016/j.jmpt.2008.08.003> PMID:18804003
 13. Javanshir K, Mohseni-Bandpei MA, Rezasoltani A, Amiri M, Rahgozar M. Ultrasonography of longus colli muscle: A reliability study on healthy subjects and patients with chronic neck pain. *J Bodyw Mov Ther* 2009; **15** (1):50-6 <http://dx.doi.org/10.1016/j.jbmt.2009.07.005> PMID:21147418
 14. Soltani AR, Kallinen M, Malkia E, Vihko V. Ultrasonography of the neck splenius capitis muscle. Investigation in a group of young healthy women. *Acta Radiol* 1996; **37** (5):647-50 <http://dx.doi.org/10.3109/02841859609177691> PMID:8915268
 15. Rezasoltani A, Ali-Reza A, Khosro KK, Abbass R. Preliminary study of neck muscle size and strength measurements in females with chronic non-specific neck pain and healthy control subjects. *Man Ther* 2010; **15** (4):400-3 <http://dx.doi.org/10.1016/j.math.2010.02.010> PMID:20430684
 16. Rezasoltani A, Mälkiä E, Vihko V. Neck muscle ultrasonography of male weight-lifters, wrestlers and controls. *Scand J Med Sci Sports* 1999; **9** (4):214-218 <http://dx.doi.org/10.1111/j.1600-0838.1999.tb00236.x> PMID:10407929
 17. Rankin G, Stokes M. Ultrasound imaging: normal values in males and females of different ages. *Man Ther* 2005; **10** (2):108-115 <http://dx.doi.org/10.1016/j.math.2004.08.004> PMID:15922231
 18. Pulkovski N, Mannion AF, Caporaso F, Toma V, Gulber D, Helbling D, et al. Ultrasound assessment of transversus abdominis muscle contraction ratio during abdominal hollowing: a useful tool to distinguish between patients with chronic low back pain and healthy controls? *Eur Spine J* 2012; **21** (Suppl 6):750-9 <http://dx.doi.org/10.1007/s00586-011-1707-8> PMID:21451982
 19. Cagnie B, Derese E, Vandamme L, Verstraete K, Cambier D, Danneels L. Validity and reliability of ultrasonography for the longus colli in asymptomatic subjects. *Man Ther* 2009; **14** (4):421-426 <http://dx.doi.org/10.1016/j.math.2008.07.007> PMID:18829376
 20. Rezasoltani A, Ylinen J, Vihko V. Isometric cervical extension force and dimensions of semispinalis capitis muscle. *J Rehabil Res Dev*

Structural changes of longus colli in neck pain

- 2002;**39** (3):423-428 PMID:12173762
21. Walker-Bone K, Reading I, Coggon D, Cooper C, Palmer KT. The anatomical pattern and determinants of pain in the neck and upper limbs: an epidemiologic study. *Pain* 2004;**109** (1-2):45-51 <http://dx.doi.org/10.1016/j.pain.2004.01.008> PMID:15082125
22. Matsumoto M, Okada E, Ichihara D, Watanabe K, Chiba K, Toyama Y, et al. Anterior cervical decompression and fusion accelerates adjacent segmentdegeneration: comparison with asymptomatic volunteers in a ten-year magnetic resonance imaging follow-up study. *Spine* 2010; **35** (1):36-43 <http://dx.doi.org/10.1097/BRS.0b013e3181b8a80d> PMID:20023606
23. Parkkola R, Rytökoski U, Kormano M. Magnetic resonance imaging of the discs and trunk muscles in patients with chronic low back pain and healthy control subjects. *Spine* 1993;**18** (7):830-6 <http://dx.doi.org/10.1097/00007632-199306000-00004> PMID:8316880
24. Tsubahara A, Chino N, Akaboshi K, Okajima Y, Takahashi H. Age-related changes of water and fat content in muscles estimated by magnetic resonance (MRI) imaging. *Disabil and Rehabil* 1995;**17** (6):298-304 <http://dx.doi.org/10.3109/09638289509166650> PMID:7579480
25. Ashton AQ. Lower Back Pain: New Insights for the Healthcare Professional: 2011 edition, ScholarlyBrief
-