

**Original Article**

**Infiltration of Inflammatory Cells in the Ovary Following Oral Administration of Monosodium Glutamate**

*Ilegbedion IG<sup>1</sup>, Onyije FM<sup>2</sup>, Chibuike OO<sup>3</sup>*

**Abstract**

**Background:** Monosodium glutamate (MSG) a sodium salt of naturally occurring (non-essential) L-form of glutamic acid is one of the main flavor enhancer used as an ingredient in various food products. It is widely used in restaurants, packaged food industries and household kitchens, in Nigeria, most communities and individuals often use MSG as a bleaching agent for the removal of stains from clothes. **Materials and Methods:** Twenty (20) female adult wistar rats were used for this experiment. The rats with average weight of 181g were randomly assigned into four groups of five each (Groups A, B, C and D). Group A, B and C served as treatments groups while group D as the control. Each rat in the treatment groups A, B and C received 0.1g/kg, 0.15g/kg and 0.20g/kg of monosodium glutamate respectively in 0.5ml of water orally three times daily for two weeks. **Result:** The histopathological evaluation of the tissues of the ovary showed Infiltration of inflammatory cells in and around the oocyte as well as in the zonal granulosa layer. There was distortion of tissue architecture. **Conclusion:** MSG alters the histology of the ovary, therefore its consumption should be stopped and to work out safe level of consumption further in depth studies are recommended.

**Key words:** Inflammation, Ovary, Histopathology, Food Additive.

**Introduction**

Monosodium glutamate (MSG) a sodium salt of naturally occurring (non-essential) L-form of glutamic acid is one of the main flavor enhancer used as an ingredient in various food products<sup>1,2</sup>. It is widely used in restaurants, packaged food industries and household kitchens<sup>3</sup>, in Nigeria, most communities and individuals often use MSG as a bleaching agent for the removal of stains from clothes. MSG is sold in most open market stalls and stores in Nigeria as "Ajinomoto" marketed by West African Seasoning Company Limited<sup>4</sup> or "Vedan" marketed by Mac & Mei (Nig)<sup>5</sup>. Its palatable and favorite flavor is a must in almost all Chinese and South-Asian dishes, where it is known by the names of Ajinomoto, Sasa, Vetsin, Miwon and Weichaun<sup>2</sup>, Limited is a crystalline sodium salt of glutamic acid<sup>5</sup>. MSG improves the taste of

food which is called "Umami Taste" in Japanese. It potentiates the activity of gustatory nerves<sup>6,7</sup>, in particular those nerves that mediate sweet taste<sup>8,9</sup>. The effect of MSG is attributed to the presence of the sodium ion, although the glutamate ion by itself can also intensify the activity of gustatory nerves<sup>9</sup>. The effect of MSG on sweet taste is enhanced by guanosine 5'-monophosphate (GMP)<sup>10</sup>. MSG is generally synthesized by a method referred to as microbial fermentation<sup>11,12</sup>. MSG has been reported to causes burning sensation at the back of neck, forearms, chest, facial pressure/tightness, chest pain, headache, nausea, palpitation, numbness in back of neck radiating to arms and back, tingling, warmth, weakness in face, temples, upper back, neck and arms, bronchospasm (observed in asthmatics only), drowsiness, weakness<sup>13</sup>.

1. IG Ilegbedion, Department of Medical Laboratory Science,
2. FM Onyije, Department of Human Anatomy, Faculty of Basic Medical Science, College of Health Sciences, Niger Delta University, Wilberforce Island, P.M.B. 071 Yenagoa, Bayelsa State, Nigeria
3. OO Chibuike, Department of Medical Laboratory Science, Faculty of Health Sciences, Madonna University, Elele Campus, Rivers State, Nigeria

**Corresponds to:** Onyije FM Department of Human Anatomy, Faculty of Basic Medical Science, College of Health Sciences, Niger Delta University, Wilberforce Island, P.M.B. 071 Yenagoa, Bayelsa State, Nigeria. Email: [onyijefelix@yahoo.com](mailto:onyijefelix@yahoo.com)

The ovary is a paired, egg producing reproductive organ found in female Organism<sup>14</sup>. The ovaries also function in the production of various steroids and peptide hormones like estrogen and progesterone which sub serve many functions in the reproductive system<sup>15</sup>. The aim of this study is to evaluate the effect of MSG on the ovaries.

**Materials and Method**

**Animals**

The rats were purchased from the Departments of Histopathology Madonna University, Nigeria Elele. The Wistar rats were kept in a clean plastic cages enclosed with wire gauzes cover according to their groups under standard housing conditions at temperature 25<sup>0</sup>C-29<sup>0</sup>C at a 12hour light and dark cycle. They were fed with growers marsh produced by grand cereals and oil mills limited, Bukuru jos, plateau state, Nigeria, which was obtained from chrys ventures limited, owerri Imo state, Nigeria.

**Monosodium glutamate**

The powdered form of monosodium glutamate was bought from Elele Market, Rivers State.

**Experimental Design /Administration of monosodium glutamate to the Animals**

Twenty (20) female adult Wistar rats were used for this experiment. The rats with average weight of 181g were randomly assigned into four groups of five each (Groups A, B, C and D). Group A, B and C served as treatments groups while group D as the control. Each rat in the treatment groups A, B and C received 0.1g/kg, 0.15g/kg and 0.20g/kg of monosodium glutamate respectively in 0.5ml of water orally three times daily for two weeks (fourteen days). The rats were sacrificed on the fifteenth day of the experiment.

**Histopathological Examination**

The rats were sacrificed 24hrs after the last dose, the ovaries were dissected and fixed in 10% formal saline, dehydrated in ascending grades of alcohol, impregnated and imbedded in paraffin wax. Paraffin sections (5 µm thick) were stained with haematoxylin and eosin (H & E) as a routine stain.

This study was approved by local ethical committee.

**Results**

**Weight of Animal**

In group A there was a decrease in weight both in week one and two. Group B, the weight in week one was elevated but dropped in the second week .The group C weight was not altered. There were no significantly differences in all the groups compared with the control.

**Histopathology**

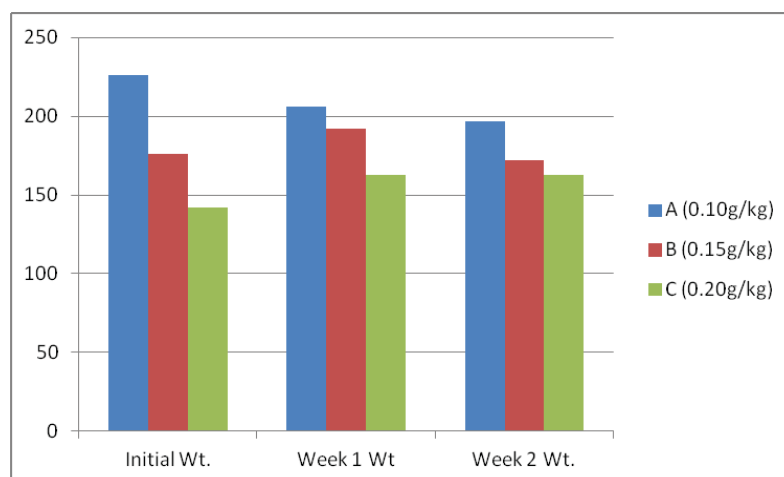
The histopathological evaluation of the tissues of the ovary showed Infiltration of inflammatory cells in and around the oocyte as well as in the zonal granulosa layer. There was distortion of tissue architecture.

**Table 1:** Body weight of the three groups experimental rats administered with different doses of Monosodium Glutamate

Groups	Initial Wt.	Week 1 Wt	Week 2 Wt.
A (0.10g/kg)	226	206	197
B (0.15g/kg)	176	192	172
C (0.20g/kg)	142	163	163

Each value represents the mean±standard deviation (n=5), values are statistically not different from Initial weight. One-way analysis of variance (ANOVA)+ Tukey–Kramer Multiple Comparisons Test

**Fig.1:** Body weight of the three groups experimental rats administered with different doses of Monosodium Glutamate

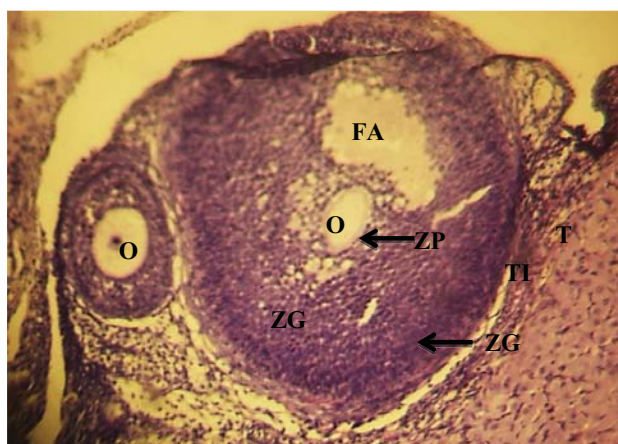


## DISCUSSION

It was reported in 1968, by new England Journal of Medicine that MSG have some adverse effect<sup>16</sup>. In 1969, the first evidence that processed free glutamic acid causes brain lesions and neuroendocrine disorders in laboratory animals, was published<sup>17</sup>. In 1969 and the early 1970s, the safety of using

Fig.2: Control. X100

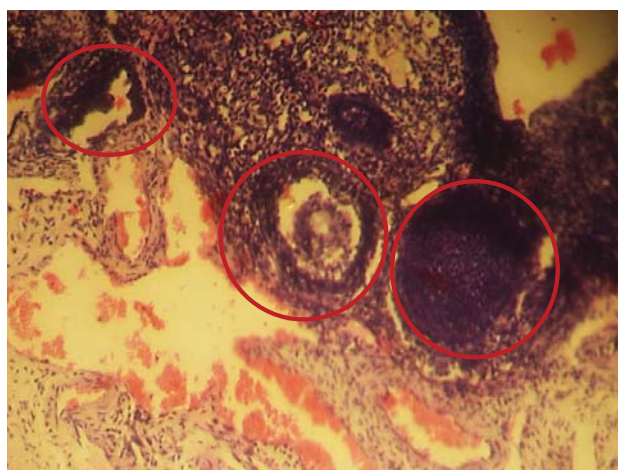
Normal histology of the ovary, O = Oocyte, ZP = Zonal pellucida, ZG = Zonal granulosa, FA = Follicular antrum, TI = Theca interna, TE = Theca Externa



processed free glutamic acid in baby food was questioned<sup>18-20</sup>. In the mid-1970s, epidemiological studies indicated that 25% or more of adults in the United States reacted adversely to MSG<sup>21-24</sup>. The controversy over the use of processed free glutamic acid in baby food continued until 1978 when baby food manufacturers "voluntarily" stopped using any form of processed free glutamic acid<sup>25</sup>. The Directorate and Regulatory Affairs of Food and Drug Administration and Control (FDA&C) in

Fig. 3: (Group A, 0.10g/kg MSG) X100

Infiltration of inflammatory cells in and around the oocyte as well as in the zonal granulosa layer (Red rings)



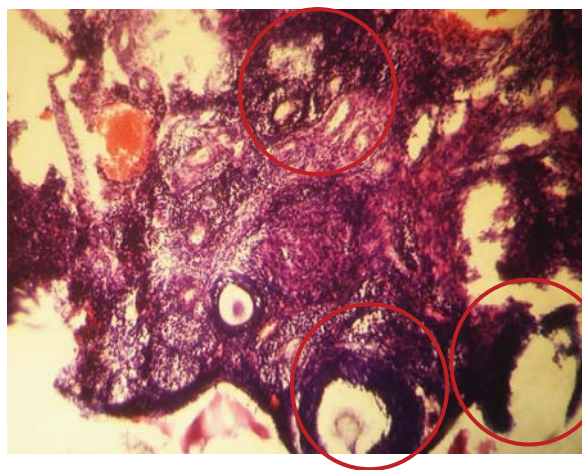
Nigeria, now NAFDAC has also expressed the view that MSG is not injurious to health<sup>26</sup>. The safety of MSG usage has been generated much controversy locally and globally<sup>27,28</sup>, as earlier stated.

Our result indicated that at the various doses administered there were no significantly differences in weight in all the groups compared with the control, which is an indication that MSG has little or nothing to do with the body weight.

Histologically the ovary shows infiltration of inflammatory cells in and around the oocyte as well

Fig. 4: (Group B, 0.15g/kg MSG) X100

Severe infiltration of inflammatory cells around the oocyte on the zonal granulosa layer (ZG), as well as in the theca layer (Red rings). There is distortion of tissue architecture.

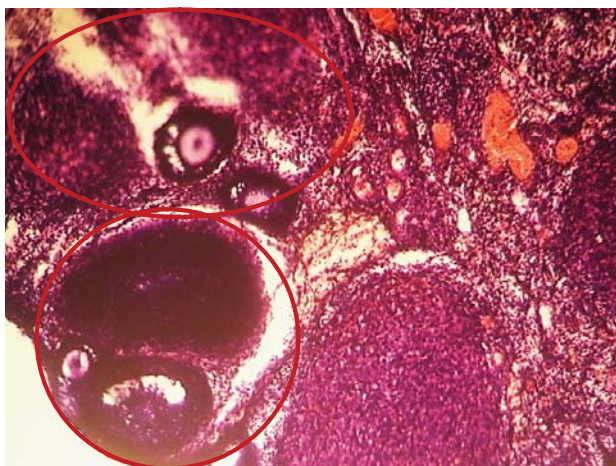


as in the zonal granulosa layer according to their dosage, there was also distortion of tissue architecture. Our results indicate that MSG causes infiltration of inflammatory cells in the ovary, although it may be dose dependent. This study similar to the study carried out by Eweka et al<sup>4</sup> on the histological studies of the effects of monosodium glutamate on the fallopian tubes of adult female Wistar rats, where cellular hypertrophy of the columnar epithelium, distortion of the basement membrane, vacuolations of the fallopian tubes as well as degenerative and atrophic changes, which was attributed to consumption of MSG<sup>27-29</sup>. Although the report of Das and Ghosh<sup>30</sup> on the Long term effects in ovaries of the adult mice following exposure to Monosodium glutamate during neonatal life – a histological study did show any tissue distortion in dosage of 2mg.

Our result is also similar to Eweka A and Om'iniabohs<sup>31</sup> where cellular hypertrophy, degenerative and atrophic changes was reported in animals

administered with 0.08mg/kg of MSG and also the study done on Assessment of DNA Damage in Testes from Young Wistar Male Rat Treated with MSG, where Ismail<sup>32</sup> reported alterations of the seminiferous tubules which included atrophied tubules, exfoliation of spermatocytes, spermatids,

Fig. 5: (Group C, 0.20g/kg MSG) X100  
Severe infiltration of inflammatory cells around the oocyte on the zonal granulosa layer (ZG)



many nuclei of different types of spermatogenesis appeared pyknotic and necrotic, and dilated congested inter tubular blood vessels, while Mohamed<sup>33</sup> reported that the treatment with MSG at short-term exhibited slight to moderate damaged seminiferous tubules, included vacuoles were found inside the cytoplasm of spermatogonia and loss of late spermatids, shrinkage, widening of the spaces between the tubules. Long-term treatment caused severe damage of germ cells and large masses of necrotic cells were present in many tubules. Focusing on exfoliated, sloughing early spermatids and vacuolation in some damage of seminiferous tubules proved the presence of many signs of deterioration of these cells of tubules.

### **Conclusion**

Based on the present and previously reported studies of MSG on the reproductive system of male and female, it is obvious that MSG exerts deleterious effects. Therefore its consumption should be stopped and to work out tolerable dose further in depth studies involving molecular tools are recommended.

### **Reference**

1. Belluardo M, Mudo G and Bindoni M. Effect of early Destruction of the mouse arcuate nucleus by MSG on age Dependent natural killer activity: *Brain Res.* 1990; **534**: 225-333. [http://dx.doi.org/10.1016/0006-8993\(90\)90132-U](http://dx.doi.org/10.1016/0006-8993(90)90132-U)
2. Moore KL. Congenital malformations due to environmental; *Developing Humans.* W.B. Saunders co. Ltd. Philadelphia. 2003; 2nd ed.pp.173-183.
3. Walker R and Lupien JR. The safety evaluation of monosodium glutamate. *J Nutr* 2000; **130**: 1049S-52S. PMID:10736380
4. Eweka AO, Eweka A and Om'Iniabohs FAE. Histological studies of the effects of monosodium glutamate of the fallopian tubes of adult female Wistar rats. *North Am J Med Sci* 2010; **2**: 146-149.
5. Eweka AO and Adjene JO. Histological studies of the effects of monosodium Glutamate on the medial geniculate body of adult Wister rat. *Electron J Biomed.* 2007; **22**: 9-13.
6. Sato M, Yamashita S and Ogawa H. Potentiation of gustatory response to monosodium glutamate in rat chorda tympani fibers by addition of 5'-ribonucleotides. *Jpn. J. Physiol* 1970; **20**: 444-464. <http://dx.doi.org/10.2170/jjphysiol.20.444> PMID:5312071
7. Schiffman SS and Gill JM. Psychophysical and neurophysiological taste responses to glutamate and purinergic compounds. In: Kawamura, Y.; Kare, M. R., eds. *Umami: A basic taste.* New York: Marcel Dekker Inc.; 1987: 271-288.
8. Nishijo H, Ono T and Norgren R. Parabrachial gustatory neural responses to monosodium glutamate ingested by awake rats. *Physiol. Behav.* 1991; **49**(5): 965-971 [http://dx.doi.org/10.1016/0031-9384\(91\)90209-7](http://dx.doi.org/10.1016/0031-9384(91)90209-7)
9. Yamamoto T, Matsuo R, Fujimoto Y, Fukanaga I, Miyasaka A and Imoto T. Electrophysiological and behavioral studies on the taste of umami substances in the rat. *Physiol. Behav.* 1991, **49**(5):919-925. [http://dx.doi.org/10.1016/0031-9384\(91\)90204-2](http://dx.doi.org/10.1016/0031-9384(91)90204-2)

10. Anton B. Steffens, Henri Leuvenink and Anton J. W. Scheurink: Effects of Monosodium Glutamate (Umami Taste) With and Without Guanosine 5'-Monophosphate on Rat Autonomic Responses to Meals. *Physiology & Behavior* 1994;**56** (1): 59-63  
[http://dx.doi.org/10.1016/0031-9384\(94\)90261-5](http://dx.doi.org/10.1016/0031-9384(94)90261-5)
11. Choi DW. Glutamate Neurotoxicity and Diseases of the Nervous System. (A Review) *Neuron*. 1998; **1**:623-634.  
[http://dx.doi.org/10.1016/0896-6273\(88\)90162-6](http://dx.doi.org/10.1016/0896-6273(88)90162-6)
12. Schaumburg HH, Byck R, Gerstil R and Mashnan JH. Monosodium L-glutamate; its pharmacology and role in the Chinese Restaurant Syndrome *Science* 1969; **163**: 826-828.
13. Daniel JR, John MT and Kenneth DF. Executive Summary from the Report: Analysis of Adverse Reactions to Monosodium Glutamate (MSG). Published as a supplement to The Journal of Nutrition, Accessed March 2013.
14. Moze, S and sefcikova Z. Obesity and changes of alkailine phosphotase activity in the small intestine of 40and 80-day old rat subjected to early postnatal overfeeding of monosodium glutamate. *Journal of Medical physiology* 2004;177-186.
15. Inderbir S. General structure of ovary. In: Text book of Human Histology. 5th edition. Jay pee brother medical publisher, New Delhi India. 2012, 286-292.
16. Kwok RHM. The Chinese restaurant syndrome. Letter to the editor. *N Engl J Med* 1968; **278**: 796<http://dx.doi.org/10.1056/NEJM196804042781419>
17. Olney JW. Brain lesions, obesity and other disturbances in mice treated with monosodium glutamate. *Science* 1969; **164**: 719-721.  
<http://dx.doi.org/10.1126/science.164.3880.719> PMID:5778021
18. Senate Select Committee on Nutrition and Health. September, 1969. Accessed March, 2013
19. Baltimore Sun. Nader Says Agency Lied: Claims FDA Falsified Data on Baby-Food Safety.1969. P A12.
20. Senate Select Committee on Nutrition and Human Needs. Part 4A. Food Additives. September 19, 1972. Accessed March, 2013
21. Reif-Lehrer LA. Questionnaire study of the prevalence of Chinese restaurant syndrome. *Federation Proceedings* 1977; **36**:1617-1623. PMID:844607
22. Kenney RA. and Tidball CS. Human susceptibility to oral monosodium L-glutamate. *Am J Clin Nutr.* 1972; **25**:140-146. PMID:5009781
23. Kerr GR, Wu-Lee M, El-Lozy M, McGandy R and Stare F. Food-symptomatology questionnaires: risks of demand-bias questions and population-biased surveys. In: Glutamic Acid: Advances in Biochemistry and Physiology Filer, Lj, et al., eds. New York: Raven Press, 1979.
24. Schaumburg HH, Byck R, Gerstl R and Mashman JH. Monosodium L-glutamate: its pharmacology and role in the Chinese restaurant syndrome. *Science* 1969; **163**:826-828,  
<http://dx.doi.org/10.1126/science.163.3869.826> PMID:5764480
25. Olney JW. Prepared Statement for the Public Meeting Pertaining to Adverse Reactions to Monosodium Glutamate (MSG). April, 1993. FDA Docket #92N-0391, Item #TS7.
26. Okwuraiwe PE. The role of food and Drug Administration and control (FDA&C) in ensuring the safety of food and food Ingredients: A symposium held at Sheraton Hotel, Lagos. 1st Sept.1992: 6-15.
27. Rogers PP and Blundell JE. Umani and appetite: Effects of monosodium glutamate on hunger and food intake in human subjects. *Physiol Behav*1990; **48**(6): 801-804.  
[http://dx.doi.org/10.1016/0031-9384\(90\)90230-2](http://dx.doi.org/10.1016/0031-9384(90)90230-2)
28. Iwase M, Yamamoto M, Iino K, IchikawaK, Shinohara N and Yoshinari F. Obesity induced by neonatal monosodium glutamate treatment in spontaneously hypertensive rats: an animal model of multiple risk factors'. *Hypertens Res* 1998; **43**: 62-28.

## Infiltration of Inflammatory Cells in the Ovary Following Oral Administration of Monosodium Glutamate

29. Gobatto CA, Mello MA, Souza CT and Ribeiro IA. The monosodium glutamate (MSG) obese rat as a model for the study of exercise in obesity. *Res Commun Mol Pathol Pharmacol* 2002; **2**: 116-128.
30. Das RS and Ghosh SK Long term effects in ovaries of the adult mice following exposure to Monosodium glutamate during neonatal life – a histological study *Nepal Med Coll. J* 2011; **13**(2): 77-83 PMID:22364086
31. Eweka A and Om'iniabohs F . Histological studies of the effects of monosodium glutamate on the ovaries of adult wistar rats. *Ann Med Health Sci Res* 2011; **1** (1): 37-43 PMID: 23209953 PMID:23209953 PMCID:PMC3507099
32. Ismail NH. Assessment of DNA Damage in Testes from Young Wistar Male Rat Treated with Monosodium Glutamate *Life Science Journal* 2012; **9** (1) :930-939
33. Mohamed IK. The effects of oral dosage of monosodium glutamate (MSG) applied for short- and long- terms on the histology and ultrastructure of testes of the adult rats. *Journal of Anim. Vet. Adv.* 2012, **11**(1):124-133. <http://dx.doi.org/10.3923/javaa.2012.124.133>
-