

## Case Report

### **Primary dural hemangiopericytoma with xanthomatous change mimicking meningioma: a case report with brief review of literature**

Shetty A<sup>1</sup>, Geethamani V<sup>2</sup>, Kumar SA<sup>3</sup>, Lekha MB<sup>4</sup>

#### **Abstract:**

Hemangiopericytomas of the Central Nervous system present as a distinct clinicopathologic entity, having been categorized as a “mesenchymal-meningothelial tumour”, according to the current WHO classification. Not only is the lesion rare, but it also bears imaging, macro-micro and immunohistochemical similarities to the commoner tumour-meningioma and to the solitary fibrous tumour and has an indolent biological behaviour unlike the other two. We present a case of a 48 year old lady, diagnosed on imaging as meningioma, which turned out to be a dural hemangiopericytoma after complete histological and immunohistochemical work up. Excluding hemangiopericytoma in lesions presenting as intra-cranial tumours is critical, as the tumour is known for recurrence and metastasis, thereby warranting more aggressive treatment by the neurosurgeons, aiding in better patient care. We report this case not only because of its rarity, but also to show the xanthomatous change the tumour showed, not documented in literature so far.

**Keywords:** hemangiopericytoma; meningioma; reticulin stain; recurrence; metastasis

DOI: <http://dx.doi.org/10.3329/bjms.v14i2.16219>

Bangladesh Journal of Medical Science Vol.14(2) 2015 p.206-209

#### **Introduction :**

Hemangiopericytomas are ubiquitous in all types of mesenchymal tissue, majority being found in the musculoskeletal system and skin<sup>1</sup>. Hemangiopericytomas of the central nervous system are rare, and often mimic the more common meningiomas, both in clinical presentation and on imaging. Histopathology and immunohistochemistry is needed for confirmation, recognition of this being important as it a tumour with an indolent course, requiring aggressive treatment and follow up. We report a case of a 48 year old lady, suspected as meningioma on imaging, followed by excision of the tumour, after complete work up of which it was diagnosed as a dural hemangiopericytoma.

We present this case, not only because of its rarity but also because of the xanthomatous change it showed, a new finding, not documented in literature

#### **Case report:**

A 48 year old female presented to the neurology

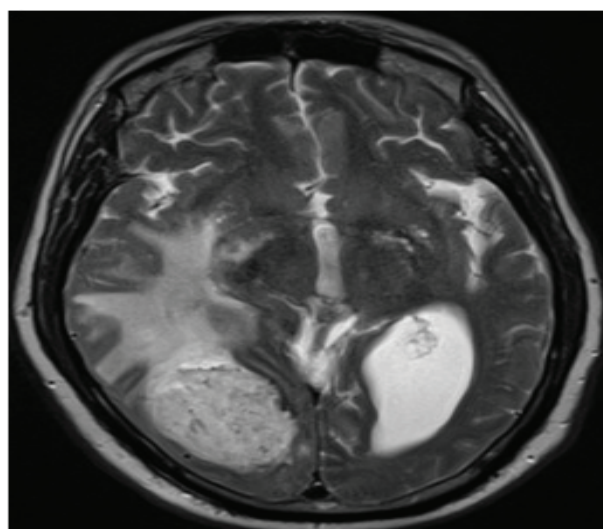


FIG 1 – MRI: Dural lesion appearing hypointense on T1 weighted images with no calcification/ hyperostosis. department with complaints of intermittent seizures and headache since a year. Routine biochemical parameters were within normal limits. MRI done

1. Dr. Archana Shetty, Assistant Professor
  2. Dr. Venkat Geethamani, Professor and Head
  3. Dr.Savitha Anil Kumar, Assistant Professor
  - 4.Dr.Lekha M B, Assistant Professor
- Sapthagiri Institute of Medical Sciences and Research Centre.

**Corresponds to:** Dr. Archana Shetty, Assistant Professor, Sapthagiri Institute of Medical Sciences and Research Centre, Street no.15, Hesaraghatta Main Road, BANGALORE: 560090, Email: [archanashetty2924@gmail.com](mailto:archanashetty2924@gmail.com)

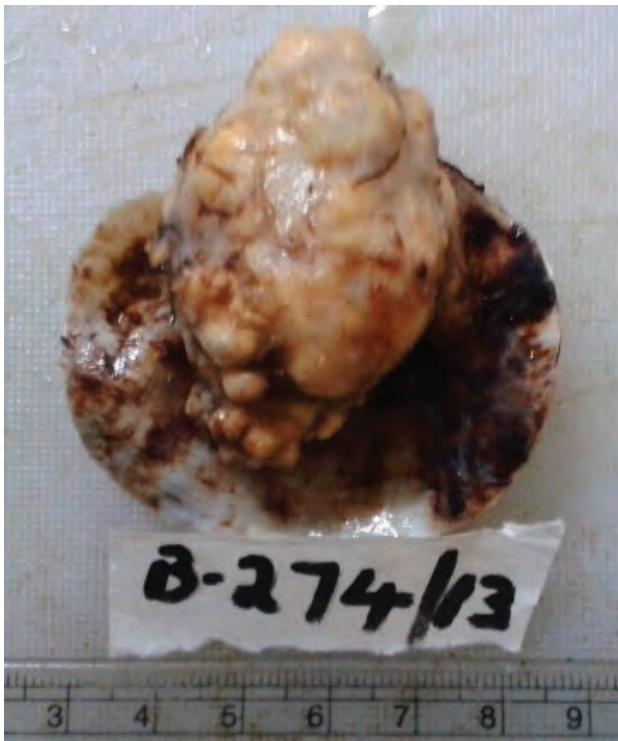


Fig 2A: Excised tumour showing a lobulated surface and narrow dural attachment.

outside showed a temporo- parietal dural lesion, hypointense on T1 weighted images, with mass effect and contrast enhancement. No areas of hyperostosis / calcification were noted.

Suspecting it to be a meningioma the neurosurgeon planned for a wide excision of the lesion. The excised mass was sent for HPE. Gross examination revealed a mass with a narrow dural attachment, measuring 4 x 3 x 2 cms. Cut section of the mass was solid, grey

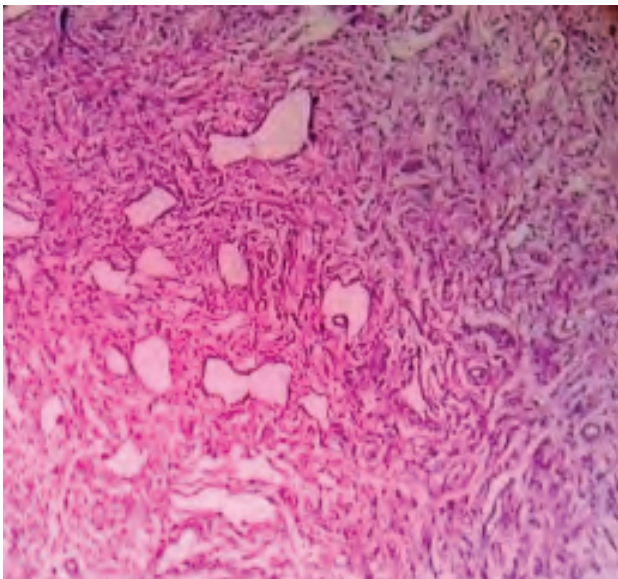


Fig 3A: H and E stain showing short fascicles and whorls of spindle cells

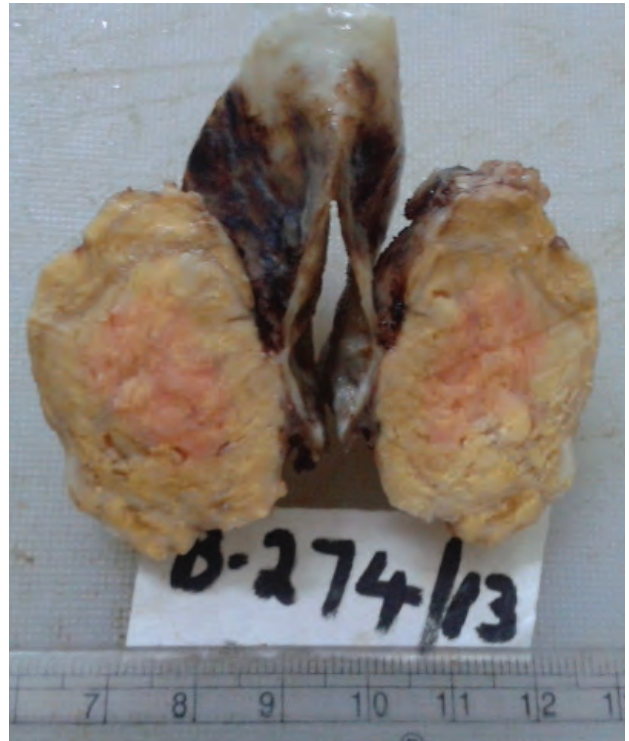


Fig 2B: Cut section showing grey white areas, with foci of yellowish discoloration

white, with yellowish areas

No areas of necrosis/Psammoma bodies/collagen bundles were noted. The IHC panel included EMA, Vimentin, GFAP, S-100, CD 68 and CD 34. EMA, vimentin and GFAP were negative ruling out meningiomas & gliomas. S100 was negative ruling out schwannomas. CD 34 was focally positive only around the vessels. CD - 68 was focally positive in the foamy histiocytes

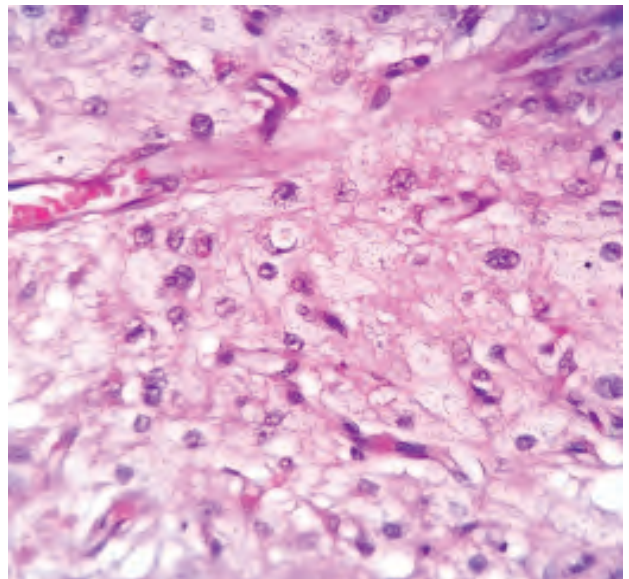


Fig 3B: Hand E stain showing a vascular tumour, with few foamy histiocytes.



A final diagnosis of dural hemangiopericytoma was made. The patient received radiotherapy and is on regular follow up for the past 8 months.

**DISCUSSION:**

Hemangiopericytomas (HPC) are rare intracranial tumours, with a reported incidence of < 1%. Bregg and Garret first reported the intracranial occurrence of HPC and documented its origin from the meninges.[2]. HPC's were earlier considered to be one of the variants of meningioma. Due to its distinct histomorphology, immunophenotype and biological behaviour, WHO in 2007, laid down clear criteria for grading meningeal HPC, making it a distinct entity<sup>2</sup>. The mean age of its diagnosis is 46 years, with most frequent symptoms being headache and dizziness, as seen in the index case It is known to

occur more commonly in males than females unlike meningiomas<sup>1</sup>. Rare cases presenting as intracranial haemorrhage have been reported in literature, and have attributed the same to erosion/distension of the blood vessels by tumour growth, endothelial proliferation and increased vascularity of the tumour<sup>3</sup>. On MRI hemangiopericytomas are lobulated, 2/3rds of cases having a broad dural attachment. They are iso-intense with grey matter on T1 weighted images & enhance heterogeneously after administration of gadolinium. They may show bony erosion, but not hyperostosis or intra-tumoral calcification, commonly associated with meningiomas<sup>4</sup>. Dural tail sign on MRI is not specific for meningiomas, as they can be seen in more than half cases of HPC'S also Histologically it represents hypervascularity

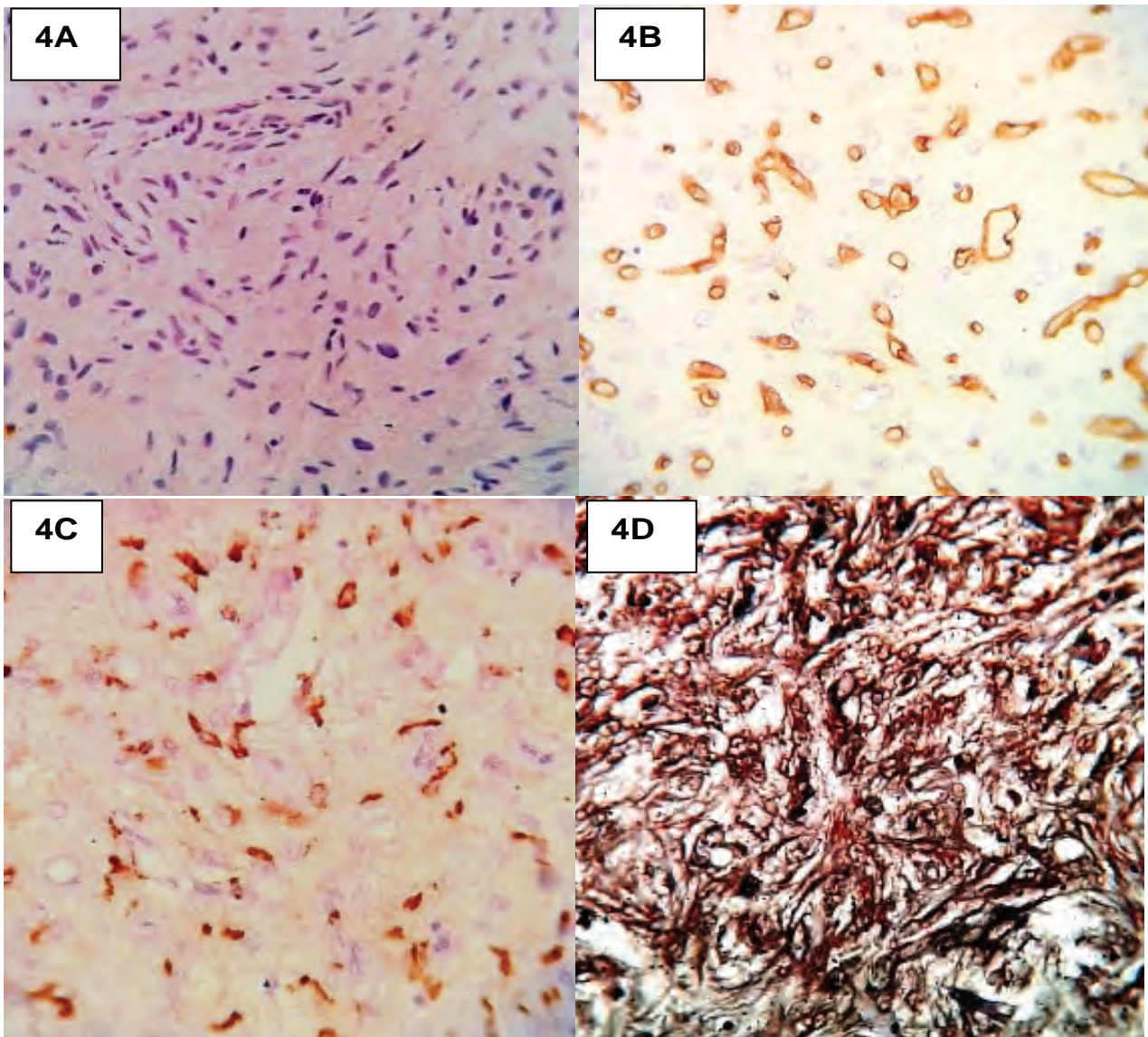


Fig 4A: EMA negative Fig 4B: CD 34 showing focal positivity around vessels FIG 4C: CD68 positive foamy histiocytes . A Lidlaw's reticulin stain highlighted tumour cells, wrapping individual cells. FIG 4D: Lidlaw reticulin stain surrounding individual cells

and non neoplastic dural reaction comprising of proliferating fibroblasts and loose connective tissue<sup>5</sup>. Histologically HPC'S of the CNS must be differentiated from both fibrous meningiomas and solitary fibrous tumours (SFT), as they share overlapping features. SFT – HPC distinction maybe trivial, but there is evidence that the two behave differently in the CNS. Although histologically the stag-horn vasculature is characteristic of HPC, it can occur in many mesenchymal neoplasms, including SFT'S<sup>6</sup>. Although no single marker is 100% sensitive or specific, the immunoprofile of HPC is sufficiently distinct enough to differentiate it from meningioma and SFT. EMA must be the first marker of choice to distinguish HPC'S and SFT'S from meningiomas, as the former are always negative<sup>7</sup>. Typically SFT'S are diffusely and strongly CD 34 positive, and display a poor reticulin network on Lidlaw's reticulin stain. On the contrary, HPC'S are negative or only focally CD34 positive and display a rich, elaborate and delicate network of reticulin wrapping tiny groups of cells<sup>6</sup>. HPC'S of grade II, although have a benign look, Zweckberger et al, in their study have documented metastasis arising from them, stressing the need for more a radical resection<sup>8</sup>.

Lipomatous hemangiopericytomas have been documented in literature<sup>6</sup>, xanthomatous change in them has not been reported. The HPC in our case had

foci of CD68 +ve, xanthomatous cells, indicating a possibility of metaplastic change and a new feature, not documented in literature so far. S-100 and EMA negativity ruled out xanthomatous meningiomas and Langerhan's Cell Histiocytosis respectively.

Excision of hemangiopericytomas can be challenging, as it may lead to substantial blood loss<sup>1</sup>. Surgery remains the mainstay of treatment for HPC'S with extent of resection having a direct bearing on overall survival. However their invasive nature & involvement of dural sinuses may preclude a radical resection, necessitating the use of post-operative radiotherapy<sup>2</sup>. The high incidence of HPC metastases, even after as long as 22 years<sup>9</sup>, & local recurrences call for careful following up of patients, even after surgical resection and additional radiotherapy<sup>10</sup>.

#### **Conclusion:**

A high index of suspicion must be kept in mind for hemangiopericytomas in the CNS, as they not only are rare, but also mimic other commonly encountered tumours like meningiomas. We report foci of xanthomatous changes in the tumour, proven by IHC, a feature which is a new finding. Its diagnosis warrants aggressive treatment and regular follow up, as this tumour is documented to have a high recurrence rate with extra-cranial metastasis in the long run.

#### **References :**

1. Wu W, Shi JX, Cheng HL, Wang HD, Hang CH, Shi QL, Yin HX. Hemangiopericytomas in the central nervous system. *J Clin Neurosci.* 2009;16 (4):519-23. doi: 10.1016/j.jocn.2008.06.011. Epub 2009 Feb 25.
2. Shetty PM, Moiyadi AV, Sridhar E. Primary CNS hemangiopericytoma presenting as an intraparenchymal mass--case report and review of literature. *Clin Neurol Neurosurg.* 2010;112(3):261-4. doi: 10.1016/j.clineuro.2009.12.001. Epub 2009 Dec 29.
3. Maruya J, Seki Y, Morita K, Nishimaki K, Minakawa T. Meningeal hemangiopericytoma manifesting as massive intracranial hemorrhage--two case reports. *Neurol Med Chir (Tokyo).* 2006;46(2):92-7.
4. Johnson MD, Powell SZ, Boyer PJ, Weil RJ, Moots PL. Dural lesions mimicking meningiomas. *Hum Pathol.* 2002;33(12):1211-26.
5. Guermazi A, Lafitte F, Miaux Y, Adem C, Bonneville JF, Chiras J. The dural tail sign--beyond meningioma. *J Clin Radiol.* 2005;60(2):171-88.
6. Tihan T, Kilpatrick S.E. Mesenchymal tumours of the Central nervous system In, Perry A and Brat J.D Practical Surgical Neuropathology- A diagnostic approach. Churchill Livingstone, Elsevier 2010, China pages 220- 225
7. Sundaram C, Uppin SG, Uppin MS, Rekha JS, Panigrahi MK, Purohit AK, Rammurti S. A clinicopathological and immunohistochemical study of central nervous system hemangiopericytomas. *J Clin Neurosci.* 2010;17(4):469-72
8. Zweckberger K, Jung CS, Mueller W, Unterberg AW, Schick U. Hemangiopericytomas grade II are not benign tumors. *Acta Neurochir (Wien).* 2011; 153(2):385-94.
9. Suzuki H, Haga Y, Oguro K, Shinoda S, Masuzawa T, Kanai N. Intracranial hemangiopericytoma with extracranial metastasis occurring after 22 years. *Neurol Med Chir (Tokyo).* 2002;42(7):297-30
10. Hayashi Y, Uchiyama N, Hayashi Y, Nakada M, Iwato M, Kita D, Higashi R, Hirota Y, Kai Y, Kuratsu J, Hamada J. Reevaluation of the primary diagnosis of hemangiopericytoma and the clinical importance of differential diagnosis from solitary fibrous tumor of the central nervous system. *Clin Neurol Neurosurg.* 2009; 111(1):34-8.