

**Original article**

**Femoral neck fracture treatment methods and results evaluation in children in a 5 year period  
Mashhd, Iran**

*Moghadam MH<sup>1</sup>, Shervin HR<sup>1</sup>, Alami M<sup>2</sup>*

**Abstract:**

**Background:** Femoral neck fractures are rare in children. This type of fracture usually originates from high energy traumas. This fracture has serious complications and one of the most disabling one is avascular necrosis. The goal of this research is active follow up of patients in order to decide about the rate of late complications, patient's function after surgery and residual pain. **Methods:** In this five year study 35 patients were evaluated and different parameters studied. These parameters included: age, sex, side of fracture, mechanism of injury, type of reduction, rate and type of complication followed surgery. **Results:** In general, femoral neck fractures are more common between 16 and 20. It is two fold common in females than males and it was more common in left side. The most common mechanism was falling. Treatment methods were open reduction in 88 % and close reduction in 12%. The most common type of fractures was type 3. Following treatment, 60% of patients remained uncomplicated and 40% had complication. In fact limitation in internal and external rotation in 20 to 30 degree was the most common complication. 30% of patients complained of mild pain during walking. **Conclusion:** After appropriate treatment most patients with femoral neck fracture have no complications, however in some cases a vascular necrosis occurs as a serious complication. This study will provide clues and information to design studies with more patients to assess how different treatment methods have impact on outcomes of patients.

**Keywords:** neck fracture; treatment methods; vascular necrosis

DOI: <http://dx.doi.org/10.3329/bjms.v14i2.18208>

Bangladesh Journal of Medical Science Vol.14(2) 2015 p.183-185

**Introduction:**

Femoral neck fractures are rare in children and account for less than 1% of total fractures. Classification of fractures in children is far different from adults. For instance, due to weakness of proximal of femur in children transepiphyseal displacement can occur. Moreover, the mechanism of intertrochantric fractures is same both in children and adults while premature closure of physis can develop in children due to trochantricaphysis involvement in children. In such situation, injuries to proximal physis lead to normal growth, on the other hand, premature closure of great trochantricaphysis leads to advanced coxavalga. Generally, complete remission is expected in children, however, these fractures have paramount importance due to serious complications such as a vascular necrosis, coxavaradeformity, leg length discrepancy

and non union. These complications can progress by growth. Hip fractures in children can occur by axial pressure, torsion, hyper abduction or direct trauma. Almost all fractures in children caused by high energy and intensive traumas. While in elder lies, low energy trauma leads to fracture in osteoprotic bone. Due to hardness of proximal physis in children, it is expected that only high energy traumas such as motor accidents lead to fracture of proximal physis. In such fractures hip pain usually disclosed and there is a limitation in external rotation. However, in fractures without dislocation or in stress fractures, patient may handle weight on just one leg and there is only pain in internal rotation. In order to diagnose a femoral fracture an anteroposterior hip radiography with appropriate resolution show a compression of hip in fractures with displacement. For avoidance of lateral frog-leg

1. Mohammad Hallaj Moghadam
2. Hasan Rahimi Shervin, Associate Professor, Department of Orthopedics, Mashhad University of Medical Sciences, Mashhad, Iran.
3. Masoomeh Alami General practitioner, Mashhad, Iran.

**Corresponds to:** Mohammad Hallaj Moghadam, Associate Professor, Department of Orthopedics, Mashhad University of Medical Sciences, Mashhad, Iran. email: [telehealth.ir@gmail.com](mailto:telehealth.ir@gmail.com).

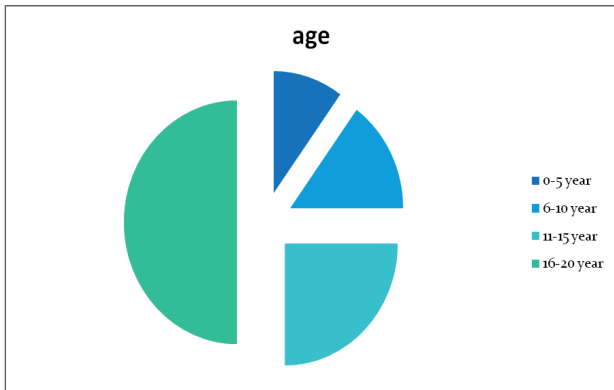


Chart1: Age prevalence in patients with femoral neck fractures

radiography which is painful for patient, a cross table radiography can be performed. There is a point that not all fractures revealed in simple radiography. Bone scan show high absorption in fracture site 48 hours after symptoms. In MRI, fracture appears as a dense line (black) with surrounding edema or hemorrhage. MRI may reveal fracture in first 24 hours. Hip fracture classification performed by Delbet method. It is important that in absence of clear history of trauma child abuse should be considered. In this article we study different treatment methods for femoral neck fractures and their results in order to assist finding the best treatment method with least complications. Actually studies with more patients and longer follow up period should be done to achieve more accurate and practical results.

**Patients and Methods:**

35 patients with femoral neck fracture in our teaching hospital evaluated in a five year period. Data were collected from patient file and radiographies before and after surgery were collected. Characteristics such as age, sex, side of fracture, mechanism of injury and type of fracture and type of reduction were obtained. The follow up period was 5 years. Lateral incision performed in all cases. Most patients classified in 16-20 year old. The prevalence of four age group was as follows: 0-5 year old: 10% -6-10 year old: 15% -11-15 year old: 25% -16-20 year old: 50%

65% of patients were male and 35% were female. 65% of cases had fracture on left side and 35% on the right. The most prevalent mechanism of injury was falling which was reported in 40% of cases. The less common mechanisms include accident and falling on the ground with 20% and 15% respectively. The most common type of fracture based on Delbet classification was type 3 in 50% of patients. Type 1 in 20%, type 2 in 23% and type 4 in 7% were reported. Most patients underwent open reduction which was done in 88%

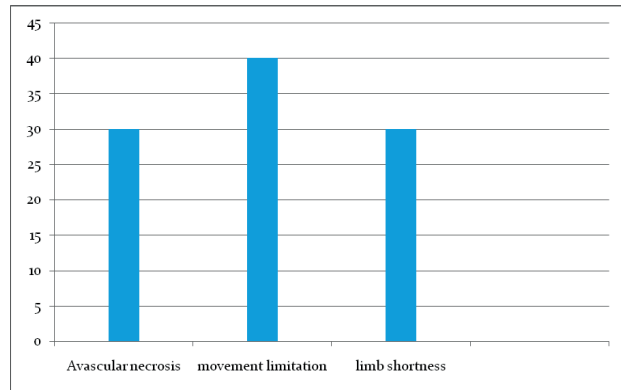


Chart2: Prevalence of complications in patients with femoral neck fracture following surgery

of patients. Close reduction performed only in 12% of cases. Hip screw utilized in all patients. Ethical clearance was taken prior the study.

**Results:**

In this study, 35 patients were studied for a 5 year period in Imam Reza hospital. Femoral neck fracture commonly was seen 16-20 year age group. It is more common in left side and also it was reported in males more than females. The most prevalent mechanism and type of fracture was falling and type 3 respectively. Most cases underwent open reduction and hip screw was used in all patients. In radiographic evaluation following surgery some complications such as avascular necrosis, movement limitation, leg length discrepancy were detected. Considering post surgery pain, only few patients complained of pain during walking.

**Discussion:**

**Table1: Prevalence of various mechanisms of injury and type of fractures in children with femur neck fracture**

Mechanism of injury	Percentage	Type of fracture	Percentage
Falling from height	40%	Type1	20%
Car Accident	20%	Type2	23%
Falling on the ground	15%	Type3	50%
Motor accident	25%	Type4	23%

In this research, 35 patients after surgery for treatment of femoral neck fracture were followed up. Complications such as non union and avascular necrosis were evaluated. Generally, 60% of cases remained without any complication and 40% had some sort of complications. Avascular necrosis accounts for 30% of complications, whereas, movement limitation

and limb shortness accounts for 40% and 30% of complications respectively.

The most common complication was movement limitation in internal and external rotation in 20 to 30 degree. In this study patients were classified in two group according to pain and discomfort after surgery<sup>1</sup>. Patients without any pain or discomfort after surgery 2-Patients who experience mild pain following surgery Actually, 70% of patients had great outcome without any pain or discomfort and 30% of cases complained of pain during walking for a long time.

A vascular necrosis is a serious complication, while it is accompanied by disability especially in children. In a study that was performed in orthopedic department of medical university of Tokyo 6 children with a vascular necrosis following femoral fracture were evaluated. They showed that only non weight bearing methods lead to some sort of remission<sup>2</sup>. Several studies designed so far and evaluated the results of different treatment methods. For instance, Song evaluated 27 cases under 16 years old that underwent two different methods ORIF and CRIF. The results suggested that patients who underwent ORIF had better outcome in comparison to patients treated with CRIF<sup>3</sup>. This fact matches our results that 60% of our patients had no complication due to better outcome of this treatment method.

Yeranosian and colleagues performed a systemic review of about 30 articles that studied almost 935 cases. Their findings revealed that a vascular necrosis has high rates in patients underwent operative treatments and reduction. Moreover, Delbet type 1 & 2 have higher possibilities to lead to open reduction and internal fixation. They also reported that coxavara reduced by operative methods while prevalence of non union was not affected by this type of treatment<sup>4,7</sup>. This fact should be considered that femoral neck fractures also have late complications such as

osteopenia after implant removal. Patman and colleagues studied 16 children after femoral implant removal retrospectively and assessed bone density and Z-score in these cases. According to the results, patients demonstrated up to 15.4% less bone density in femoral neck area (average 4.8%)<sup>8</sup>. This study gives us a clue that children with femoral neck fracture should have longer follow up period after femoral implant removal.

Some rare complications reported following femoral neck fracture in children. For example, Jung and colleagues reported one case of femoral neck fracture who complicated with slipped capital femoral epiphysis which was accompanied by a vascular necrosis and coxavara<sup>9</sup>.

Similar study was done by Bali and colleagues in order to analyze outcomes of different methods of femoral neck fracture. They studied 36 children with femur neck fracture who treated conservatively or by ORIF or CRIF. 7 cases developed a vascular necrosis. Actually this complication is the most common one. However, in our study movement limitation is the most common complications. Other complications in their study included, nonunion, coxavara and arthritic changes which is matched our results to some extent<sup>10</sup>. To wrap it up, operative treatments such as open reduction and internal fixation is preferred in comparison to conservative methods, because these methods lead to less serious complications.

Of course, more studies with more cases and longer follow up periods should perform for achievement more accurate and reliable results.

At the end, we appreciate personnel of Imam Reza hospital that they behaved so cooperative with us. Also we give special thanks to Mashhad University of medical science that helped us in this research by providing resources and facilities.

There was no conflict of interest invaded.

## References:

1. James H. James R. Rockwood and Wilkins Fractures in children. Vol 3; 5<sup>th</sup> ed, 2001 pp913-28.
2. Maeda S, Kita A, Fujii J, Funay K. Avascular necrosis associated with fractures of the femoral neck in children. *Inj* 2003 may; **34**:283-6.
3. Song KS. *J Bone Joint Surg Br*. 2010; **92**(8):1148-51.
4. Mirdad T. Fractures of femoral neck in children: an experience at the Aseer central hospital; Abha; Saud Arabia. *Inj* 2003 Nov; **33**:823-7.
5. Mohammad S. A Montgomery. Transepiphyseal fracture of the femoral neck with dislocation of the femoral head fracture of the posterior column of the acetabulum in a child. *J of bone and joint surgery* 2002; **84**:113.
6. Hurley R. Campbells operative orthopedics. Vol 3; 10<sup>th</sup> ed, mosby; newyork; 2003:1446-8
7. Yeranosian M, Horneff JG, Baldwin K, Hosalkar HS. *Bone Joint J*. 2013; **95**(1):135-42.
8. Patman LJ, Szalay EA. *Orthopedics*. 2013; **36**(4):e468-72.
9. Jung ST, Park GH. *J Pediatr Orthop B*. 2012; **21**(6):579-82.
10. Bali K, Sudesh P, Patel S, Kumar V, Saini U, Dhillon MS. *Clin Orthop Surg*. 2011 ; **3**(4):302-8.