

**Case report**

**A Case of Bilateral Retinal Hemorrhage with Cotton Wool Spot Following Viper Bite**

*Jana S<sup>1</sup>, Chaudhuri SK<sup>2</sup>, Ganguly P<sup>3</sup>, Ghorai S<sup>4</sup>*

**Abstract:**

A 38 years male, admitted in the department of Internal Medicine with a history of snake bite in his left lower leg during agriculture work. He was treated with anti snake venom after admission. He had history of dimness of vision in both eyes. On examination, swelling and subcutaneous hemorrhage was noted in his left leg. His best corrected visual acuity (BCVA) was 6/60 in the both eyes. Fundus examination with 90 D lens and Indirect Ophthalmoscopy of both eyes showed retinal hemorrhage with cotton wool spots. Blood tests revealed increased titers of D-dimer and fibrin degradation products. The patient was followed up regularly at 2 weeks interval and BCVA and Fundus examination was carried out. At the end of 10 weeks, retinal hemorrhages had significantly cleared in both eyes with improvement of vision in both eyes (BCVA of right eye at last follow-up 6/6 and left eye 6/9).

**Keywords:** retinal hemorrhage; cotton wool spot; viper bite.

*Bangladesh Journal of Medical Science Vol.14(3) 2015 p.297-298  
DOI: <http://dx.doi.org/10.3329/bjms.v14i3.18909>*

**Introduction:**

Snake bite is a serious public health problem in India. It is seen that on an average 200,000 people get bitten by snakes and of them 30,000–40,000 die because of the complications annually<sup>1</sup>. Snake venom is heterogeneous compound poison with several effects that may result in haemostatic or neurological dysfunction. Ocular complications are very rare, of which commonly reported entities are blepharoptosis, muscle palsies, haemorrhages into the conjunctiva, anterior chamber, vitreous or retina, lid oedema, conjunctival chemosis, retinal and optic nerve oedema, pupillary changes, optic neuritis and optic atrophy<sup>2</sup>. In this study, we describe a case of bilateral extensive preretinal haemorrhage following Indian Russell viper bite.

**Case report:**

A 38-year-old male from a village of Burdwan district, West Bengal, India, was admitted in the Department of Internal Medicine Burdwan Medical College as a

case of poisonous snake bite. He presented with a history of snake bite in his left leg during agriculture work in the field. The snake was beaten to death by co-workers and was identified them as “Kobra”(Indian Russell viper). He was treated with anti-snake venom at the inpatients department of Internal Medicine. He was referred to the Department of Ophthalmology for evaluation of blurring of vision in both eyes within 24 hours of admission. On examination, swelling and subcutaneous hemorrhage was noted in his left leg. His best corrected visual acuity (BCVA) was 6/60 in both eyes. The intraocular pressure, by Applanation tonometry was 16 mmHg (right eye) and 14 mmHg (left eye). On Slit lamp examination, both eye showed few cells and flare in the anterior chamber. Fundus examination with 90 D lens and Indirect Ophthalmoscopy of both the eye showed profound retinal hemorrhage with cotton wool spots (Fig.1-RE, Fig.2-LE). Blood tests revealed increased titers of D-dimer and fibrin degradation

1. Subhasis Jana, Senior Resident, Department of Ophthalmology, Lions Seva Eye Hospital, Jamalpur, Burdwan, West Bengal, India.
2. Saumen Kumar Chaudhuri, Assistant Professor, Department of Ophthalmology, Burdwan Medical College and Hospital, Burdwan, West Bengal, India.
3. Purban Ganguly, First year Post Graduate Trainee, Department of Ophthalmology, Burdwan Medical College and Hospital, Burdwan, West Bengal, India.
4. Sumi Ghorai, Assistant Professor, Department of Anatomy, Bankura Sammilani Medical College, Bankura, West Bengal, India

**Corresponds to:** Dr. Subhasis Jana, Senior Resident, Department of Ophthalmology, Lions Seva Eye Hospital, Jamalpur, Burdwan, West Bengal, India. Email: [dr.subhasisjana@gmail.com](mailto:dr.subhasisjana@gmail.com)

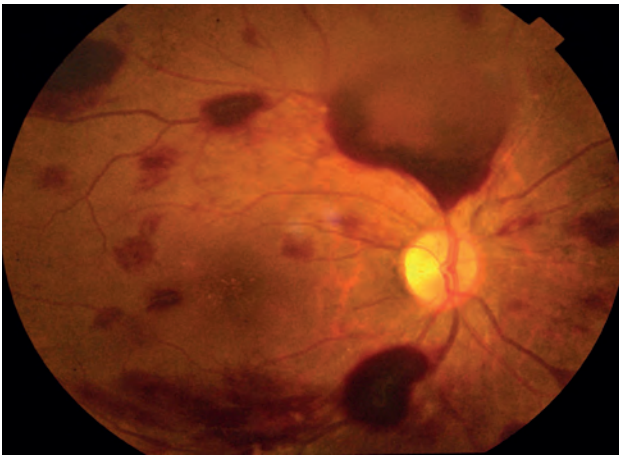


Fig 1: Showed profound retinal hemorrhage in right eye (OD)

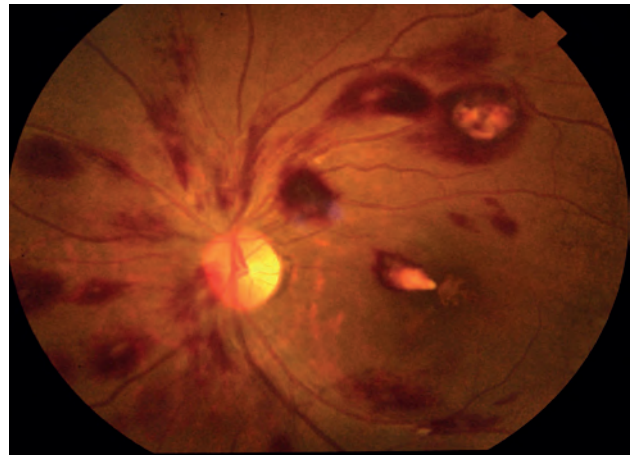


Fig 2: Showed retinal hemorrhage with cotton wool spots

products. Fluorescein angiography was not done, besides blocked fluorescence nothing could have been elicited due to extensive preretinal hemorrhage. External ocular examination was within normal limit. He had no past history of any bleeding disorders. The patient was followed up regularly at 2 weeks interval and BCVA and Fundus examination was carried out. At the end of 10 weeks, retinal hemorrhage had significantly cleared in both eyes with improvement of vision in both eyes (BCVA of right eye at last follow-up 6/9 and left eye 6/6).

#### **Discussion:**

Snake venom is a complex heterogeneous poison. It has multiple effects on the central nervous system<sup>3</sup>. Venoms are composed of proteins and peptides that have specificity for a wide range of tissue receptors<sup>4</sup>. Antihemostatic factors of viper venom can cause acute fibrinolysis, severe reduction in platelet numbers and damage to the vascular endothelium<sup>5</sup>. Viper venom leads to breakdown of endothelial barriers that causes extravasation of

fluid and oedema. It also contains hyaluronidase, collagenase and proteolytic enzymes which are able to disrupt the retinal vascular endothelium with resultant retinal hemorrhage. Snake bite related ocular complications have been rarely reported in the literature, the common problem described after snakebite is in the form of ophthalmoplegia<sup>6</sup>. Other ocular manifestations as effects of snakebite reported as keratomalacia, macular infarction, including haemorrhages into the conjunctiva, anterior chamber, lid oedema, conjunctival chemosis, retinal and optic nerve oedema, optic neuritis, and optic atrophy, globe necrosis and visual loss due to cortical infarction, uveitis and endophthalmitis<sup>7-10</sup>. In this case, vision loss is due to bilateral retinal haemorrhage and cotton wool spot subsequent to the snakebite. Such bilateral retinal hemorrhage with cotton wool spot following snakebite alone has rarely been reported. [Burdwan Medical College Hospital authority gave ethical clearance about publication of this case report]

**Conflict of interest:** None

#### **References**

- Wallace JF. Disorders caused by venoms, bites and stings. In: Isselbacher KJ, Martin JB, Braunwald E, editors. Harrison's principle of internal medicine. New York: McGraw-Hill; 1994. p. 2467–73. Edition required
- Sithole HL. The ocular complications of an envenomous snakebite. *S Afr Fam Pract* 2013; **55**:161-163. <http://dx.doi.org/10.1080/20786204.2013.10874325>
- Srinivasan R, Kaliaperumal S, Dutta TK. Bilateral angle closure glaucoma following snakebite. *J Assoc Physicians India* 2005; **53**: 46-48.
- Dawid AW. Guidelines for the clinical management of snakebites in the south-east Asia region. New Delhi: World Health Organization; 2005.
- Marsh NA. Snake venoms affecting the haemostatic mechanism: a consideration of their mechanisms, practical applications and biological significance. *Blood Coagul Fibrinolysis* 1994; **5**:399–410.
- Takeshita T, Yamada K, Hanada M, Oda-Ueda N. Extra ocular muscle paresis caused by snakebite. *Kobe J Med Sci* 2003; **49**:11–5
- SinghJ, SinghP, SinghR, VigVK. Macular infarction following viperine snake bite. *Arch Ophthalmol* 2007; **125**:1430–1. <http://dx.doi.org/10.1001/archophth.125.10.1430>
- Dhaliwal U. Cortical blindness: an unusual sequela of snake bite. *Indian J Ophthalmol* 1999; **47**: 191–2.
- Nayak SG, Satish R, Nityanandam S, Thomas RK. Uveitis following anti-snake venom therapy. *J. Venom. Toxins incl. Trop. Dis.* 2007; **13**: 130-4.
- Iqbal M, Khan BS, Ahmad I. Endogenous Endophthalmitis Associated With Snake Bite. *Pak J Ophthalmol* 2009; **25**: 114-16.