

Original article

Safety of 0.1% topical tacrolimus in the treatment of vitiligo

Hazra SC¹, Ahmed N², Ghosh JC³

Abstract:

Cure rates for vitiligo are significantly lower because of problems to different studies have reported different response rate and different adverse effect for the treatment of vitiligo. This study was conducted to evaluate the response rate and adverse effect of topical tacrolimus 0.1% ointment in the treatment of vitiligo patients in the department of Dermatology and venereology, Bangladesh Medical college (BMC), Dhaka from January 2010 to July 2010. In this clinical trial, 30 newly diagnosed vitiligo (focal and segmental) patients, aged between 10 to 50 years were assigned for therapy and to observe the response and adverse effect. Each individual lesion was treated with topical tacrolimus 0.1% ointment twice daily for three months. All the patients completed three months treatment and available for statistical analysis. The highest percentage 13(43.3%) was in the age of 11-20 years. Sex ratio revealed higher in case of female 18(60%), with a male-female ratio 1:1.5 and 5(16.67%) patients had vitiligo among their families. Repigmentation was observed in 8 (26.7%) subjects at the end of 4th week, 15 (50.1%) subjects at 8th week and 25 (83.3%) subjects after 12 weeks of therapy. 25 (83.33%) subjects did not complain any adverse effect (like pruritus, burning etc.) and 5 (16.67%) subjects were suffered from different adverse effect of drug, like pruritus observed in 2 (6.7%) subjects and burning in 6 (20%) subjects. This study found that tacrolimus 0.1% ointment to be safe in the treatment of vitiligo, with reduction in the number of vitiliginous spots by increased repigmentation significantly.

Key Words: safety of tacrolimus; treatment of vitiligo

DOI: <http://dx.doi.org/10.3329/bjms.v13i3.1914>

Bangladesh Journal of Medical Science Vol. 13 No. 03 July '14. Page: 255-259

Introduction:

Vitiligo is a common, acquired, discoloration of the skin, characterized by well circumscribed, ivory or chalky white macules which are flush to the skin surface. The hair over the lesion may be either normal or white (poliosis)¹. Vitiligo usually begins in childhood or young adulthood; approximately one half of those with vitiligo acquire the disease before the age of 20 years and the incidence decreases with increasing age². Vitiligo is a multifactorial polygenic disorder with a complex pathogenesis. Although several theories have been proposed to explain the loss of epidermal melanocyte in vitiligo, the exact cause remains unknown³. Phototherapy and applications

of topical steroids are most commonly prescribed. However, these are not always effective and corticosteroids on the face may lead to cutaneous atrophy, telangiectasias and ocular (applied to periorbital region) complications. Successful treatment of vitiligo with topical calcineurin inhibitors has been reported. Tacrolimus, a macrolide immune suppressant that comes from the fungus *Streptomyces tsukuba* is used as novel treatment option for vitiligo^{4,5}. This drug act on T cells and mast cells inhibiting T cell activation the release of pro-inflammatory mediators in mast cells by degranulation. Tacrolimus therapy does not cause atrophy, telangiectasia and ocular side effects like topical steroids, when applied

1. Dr. Samaresh Chandra Hazra, Medical officer, Infectious Diseases Hospital, Mohakhali, Dhaka.
2. Dr. Nafiza Ahmed, Associate Professor, Dept. of Dermatology and Venereology, Dhaka Medical College Hospital, Dhaka.
3. Dr. Jagodish Chandra Ghosh, Senior Consultant, Infectious Diseases Hospital, Mohakhali, Dhaka.

Corresponds to:

Dr.Samaresh Chandra Hazra. Medical officer, Infectious Diseases Hospital Mohakhali, Dhaka.
E-mail: samohazra@yahoo.com

to face and intertriginous areas⁶. In clinical trials, the common adverse effects were burning, pruritus, and erythema of skin. Burning sensation at the site of application is by far the most frequently reported adverse effect and is found in roughly 37 to 46% of adults and children treated with 0.03% tacrolimus, and 26 to 58% of those treated with 0.1% tacrolimus ointment⁷. Particular attention has been paid to skin infections as a potential complication of topical treatment with an immunosuppressive agent. Viral, fungal, and bacterial infections have all been reported⁸. Apart from mild to moderate burning, erythema, and pruritus, the use of tacrolimus ointment can cause folliculitis, acne, Kaposi's varicelliform eruptions, eczema herpeticum and herpes simplex infections. Increased skin sensitivity to hot and cold and alcohol intolerance have also been reported⁹. Occurrence of recurrent skin tags, rosacea like granulomatous eruptions, rosaceaiform dermatitis, mucosal hyperpigmentation, tinea incognito, molluscum contagiosum and verruca vulgaris have recently been reported. The cutaneous viral infection in particular is alarming and may be caused by local immunosuppressions¹⁰. Although there is a theoretic concern that topical immunomodulatory therapy with tacrolimus and pimecrolimus may increase the risk of cancer, there is no evidence to date to suggest an increased risk of cutaneous or visceral cancer. The European Agency for the Evaluation of Medicinal Products has not recommended any change in labeling or approval of these topical agents. There may still be clinical situations where such off-label treatment is seen as a lesser risk than available alternatives such as oral administration of an immunosuppressant, and limited data on safety are emerging¹¹. There are numerous treatment options available for vitiligo but none is universally safe. Very recently topical tacrolimus 0.1% is being produced and marketed in our country but its safety has not been studied in our population yet. This study is designed to observe the safety of using topical tacrolimus 0.1% in patients of vitiligo.

Materials and Methods

A clinical trial was conducted in the department of Dermatology and Venereology, BMC, Dhaka. Study period of the trial was January 2010 to July 2010 and patients with vitiligo (focal and segmental) were the study population. Finally thirty patients, who matched the inclusion criteria, were selected for the

study. Sampling technique was purposive type. History and physical findings were recorded in a structured questionnaire. Ethical approval was taken from ethical Committee of BMC, Dhaka.

Inclusion criteria:

- * Vitiligo patients of both sex and above 2 years of age.
- * Patient who had not received any treatment for vitiligo (both systemic and topical) in the previous 2 months prior to inclusion.
- * Vitiligo of focal and segmental.

Exclusion criteria:

- * Pregnant women and lactating mother.
- * Known case of tacrolimus hypersensitivity.
- * Vitiligo universalis with widespread involvement.

Procedure of data collection:

A total number of thirty subjects of vitiligo were primarily selected from the department of Dermatology and Venereology, BMC, Dhaka and complete history, general physical and dermatological examinations was done for all enrolled subjects. For women of reproductive age reproductive history, menstrual history, lactation and pregnancy plan was carefully judged. Before inclusion in the study, all the participants and parents of children were elaborately informed about the natural history and the prognosis of the disease, proper application procedures for the therapy, possible therapeutic outcomes and adverse effects associated with therapy, so that they can make independent decision about their participation. They were assured of strict privacy and secrecy of information on all occasions as such necessary measures were taken before hand. Photographs of all lesions and clinical assessment at baseline and follow-up visit after three months were taken for subsequent assessment and further comparison. Each individual lesion was treated with tacrolimus 0.1% ointment twice daily for three months. Generally, the repigmentation was recorded every 4 weekly for three months and outcome measures graded as none (no repigmentation), mild (less than 50% repigmentation), moderate (50–75% repigmentation), and complete (more than 75% repigmentation). Observation and results of the clinical study and statistical analysis were presented by suitable chart, tables, graphics and diagram.

Result

This study was carried out on thirty vitiligo (focal

and segmental) patients for a period of 12 weeks at the department of Dermatology and Venereology, BMC, Dhaka. Majority of patients suffering from vitiligo 20(66.6%) were under the age of 40 years. The highest percentage 13(43.3%) was in the age of 11-20 years. Sex ratio revealed higher in case of female 18(60%), with a male-female ratio

Table I: Distribution of the study subjects by age and sex

Age group	Frequency	Percent
<10	1	3.3
11-20	13	43.3
21-30	6	20.0
31-40	4	13.3
41-50	6	20.0
Sex		
Male	12	40.0
Female	18	60.0

Table II: Distribution of the study subject by family history of vitiligo

	Frequency	Percent
Yes	5	16.67
No	25	83.33

1:1.5(table-I). Table II showed 5(16.67%) patients

Table III: Distribution of the study subjects on the basis of repigmentation score in three follow up visits

Repigmentation score	4th week	8th week	12th week
None	22 (73.3)	15 (50.0)	5 (16.7)
Mild (<50%)	5 (16.7)	8 (26.7)	12 (40.0)
Moderate (50-70%)	2 (6.7)	5 (16.7)	7 (23.3)
Complete (>75%)	1 (3.3)	2 (6.7)	6 (20.0)

Values were expressed as number (cent).

Discussion

In this study, 43.3% subjects were within the age group of 11-20 years and 20% were in the age group of 21-30 years which mostly correlates with the findings of many other study, like the percentage of subjects in the age group of 11-20 years was 46% in one study¹² and 29.7% in another study¹³. Sex ratio revealed higher in case of female (60%), with a male-female ratio 1:1.5. According to different previous studies adults and children of both sexes are equally affected although the greater number of reports among females is probably due to the greater

Table IV: Distribution of the study subject's adverse effects (n=6) at base line and 4th and 8th week follow up.

Adverse effects	Base line	4th week	8th week
Pruritus	2 (6.7)	2 (6.7)	0 (.0)
Irritation/burning	3 (10.0)	2 (6.7)	1 (3.3)

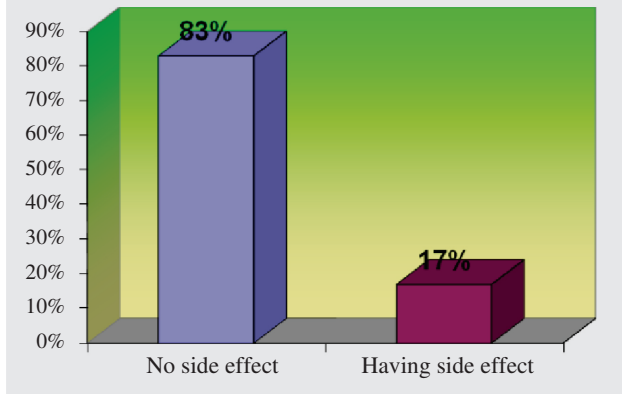


Figure I: Distribution of the subjects by adverse effects. had vitiligo among their families. Repigmentation was observed in 8(26.7%) subjects at the end of 4th week, 15 (50.1%) subjects at 8th week and 25(83.3%) subjects after 12 weeks of therapy. It was seen from figure I that 25(83%) subjects had no adverse effect and 5(17%) subjects were suffered from different adverse effects of the drug. Pruritus observed 2(6.7%)subjects and burning in3(10%) subjects.

social consequences to women and girls affected by this condition^{14, 15, 16}. Family history has variously been reported with a range between 6.25% to 38%¹⁷. However, in our study family history was 5(16.67 %)which corroborates with another study (12%)¹⁸. Though it is very difficult to judge the efficacy of treatment without studying the compliance rate and follow-up for a long time; in this study overall response to topical tacrolimus in the treatment of vitiligo has been observed, which shows 25 (83.3%) subjects had at least some repigmentation at the end of study, which concurs with other similar studies; as

for example 83.3%¹¹, 100%¹⁹, 86.4%²⁰ and 84%²¹. Xu AE et al. treated focal, segmental and generalized vitiligo with 0.1% topical tacrolimus for four months¹¹, but we treated focal and segmental vitiligo for three months with same repigmentation score, so it was faster in our study. Skin typing of Bangladeshi subjects and UVB exposure may stimulate the efficacy of topical tacrolimus, because most of the population of our country is worked in sun light. In this study only two subjects reported pruritus (6.7%), and three mild irritation and burning (10%). These are the clinical adverse effects of topical tacrolimus described in the literature which includes pruritus, irritation, burning and erythema of skin. No serious adverse events occurred during the 12 week study. The symptoms are mild intensity that concurs with the references; as we find burning sen-

sation found in 13.3%¹¹, 3.5%²¹ of cases and pruritus and burning in 12%²⁰ of cases.

Nobody discontinued the therapy for serious adverse effects. In this study dermatological adverse effects were infrequent and mild, so all the patients completed the therapy. This study found that topical-tacrolimus 0.1% ointment to be safe in the treatment of vitiligo, with reduction in the number of vitiliginous spots by increased repigmentation significantly.

Conclusion:

This study reflects that topical tacrolimus ointment 0.1% is a safe topical therapeutic option for the treatment of vitiligo. Proper selection of patient as well as appropriate topical use of drug for adequate duration responds well to reduce the number and size of vitiliginous spots with minimum adverse effects.

Reference:

1. Travis LB, Weinberg JM, Silverberg NB. Successful treatment of vitiligo with 0.1% tacrolimus ointment. *Arch Dermatol* 2003;139:571-74. <http://dx.doi.org/10.1001/archderm.139.5.571>
2. Picardi A, Pasquini P, Cattaruzza MS. Stressful life events, social support, attachment security and alexithymia in vitiligo- A case-control study. *Psychother Psychosom* 2003;72:150-58. <http://dx.doi.org/10.1159/000069731>
3. Passeron T, Ostovari N, Zakaria W, Fontas E, Larrouy JC, Lacour JP. Topical Tacrolimus and the 308 nm excimer Laser: A synergistic combination for the treatment of vitiligo. *Arch Dermatol* 2004;140:1065-69.
4. Falabella R, Arrunategui A, Barona MI, Alzate A. The minigraft test for vitiligo: Detection for stable lesion for melanocyte transplantation. *J Am Acad Dermatol* 1995;32:228-32. [http://dx.doi.org/10.1016/0190-9622\(95\)90131-0](http://dx.doi.org/10.1016/0190-9622(95)90131-0)
5. Halder RM, Talianferro SJ. Vitiligo. In: Wolff K, Goldsmith LA et al editors. *Fitzpatrick's Dermatology in General Medicine*, Newyork: Mcgraw-Hill 2008;7:616-22.
6. Kostoric K, Pasic A. New treatment modalities for vitiligo; focus on topical immunomodulators *Drugs* 2005; 65 (4) : 447 - 59 . <http://dx.doi.org/10.2165/00003495-200565040-00002>
7. Khandpur S, Sharma VK, Sumanth K. Topical immunomodulator in dermatology. *J Postgrad Med* 2004;50(2):131-9.
8. Zabawski EJ, Costner M, Cohen JB. Tacrolimus: pharmacology and therapeutic uses in dermatology. *Int J Dermatol* 2005;39:721-27. <http://dx.doi.org/10.1046/j.1365-4362.2000.00731.x>
9. Skaehill PA. Tacrolimus in dermatologic disorders. *Ann Pharmacother* 2001;35:582-88. <http://dx.doi.org/10.1345/aph.10261>
10. Cather JC, Abramovits W, Menter A. Cyclosporine and tacrolimus in dermatology. *Arch Dermatol* 2001;19:119-37.
11. Xu AE, Zhang DM, Wei XD. Efficacy and safety of tacrolimus cream 0.1% in the treatment of vitiligo. *Int J Dermatol* 2009;48(1):86-90. <http://dx.doi.org/10.1111/j.1365-4632.2009.03852.x>
12. Ostovari N, Passeron T, Lacour JP, Ortonne JP. Lack of efficacy of tacrolimus in the treatment of vitiligo in the absence of UV-B exposure. *Arch Dermatol* 2006;142(2): 252-53. <http://dx.doi.org/10.1001/archderm.142.2.252>
13. Shegal VN and Srivastava G, Vitiligo. *IJDVL* 2007;73:149-56.
14. Van Den Bossche K, Naeyaert JM, Lambert J. The quest for the mechanism of melanin transfer. *Traffic* 2006;7:769. <http://dx.doi.org/10.1111/j.1600-0854.2006.00425.x>
15. Huang CL, Nordlund JJ, Boissy R. Vitiligo: A manifestation of apoptosis? *American Journal of Clinical Dermatology* 2002;3(5): 301-08. <http://dx.doi.org/10.2165/00128071-200203050-00001>
16. Smith DA, Tofte SJ, Hanifin JM. Repigmentation of Vitiligo with topical tacrolimus. *Dermatology* 2002; 205(3): 301-03. <http://dx.doi.org/10.1159/000065845>
17. Plettenberg H, Assmann T, Ruzicka T. Childhood Vitiligo and tacrolimus: immunomodulating treatment for an autoimmune disease. *Arch Dermatol* 2003;139(5):651-54. <http://dx.doi.org/10.1001/archderm.139.5.651>
18. Back LA. The efficacy and safety of tacrolimus ointment: a clinical review. *J Am Acad Dermatol* 2005; 53 : 165 - 70 <http://dx.doi.org/10.1016/j.jaad.2005.04.059>
19. Lo YH, Cheng GS, Huang CC, Chang WY, Wu CS. Efficacy and safety of tacrolimus for the treatment of face and neck vitiligo. *J Dermatol* 2010;37(2):125-29. <http://dx.doi.org/10.1111/j.1346-8138.2009.00774.x>
20. Kanwar AJ, Dogra S, Parsad D. Topical tacrolimus for treatment of childhood vitiligo in Asians. *Clin. Exp. Dermatol* 2004;29(6):589-92 <http://dx.doi.org/10.1111/j.1365-2230.2004.01632.x>
21. Silverberg NB, Lip P, Travis, et al. Tacrolimus ointment promotes repigmentation of vitiligo in children; a review of 57 cases. *Pediatrics, Naval Medical Center, San Diego, CA. J Am Acad Dermatol* 2004;51:760-66. <http://dx.doi.org/10.1016/j.jaad.2004.05.036>