

## Case Report

### Tooth in the nose

Koosha M<sup>1</sup>, Balasubramanian A<sup>2</sup>, Mohamad I<sup>3</sup>, Rahman WFWA<sup>4</sup>

#### Abstract

The finding of intranasal ectopic or supernumerary tooth although have been reported in the past, is still considered a rare presentation. It may remain silent for a long period of time, before manifesting with nasal symptoms. We report the case of a 33-year-old lady with an ectopic premolar tooth in the floor of her right nostril, presenting with intermittent epistaxis and foul-smelling nasal discharge. She was referred for a rhinolith in her nose. The tooth was successfully extracted via intranasal endoscopic approach.

**Key words:** nose; tooth; supernumerary; ectopic

DOI: <http://dx.doi.org/10.3329/bjms.v13i3.19157>

Bangladesh Journal of Medical Science Vol. 13 No. 03 July '14, Page: 336-339

#### Introduction

One of the common referrals to the Otorhinolaryngology unit is for nasal mass symptoms. Patients may present with rhinorrhea, epistaxis, foul-smelling discharge and nasal block. Among the diagnoses entertained are allergic rhinitis, malignancies and foreign bodies. Very rarely a tooth is found in the nose, especially one with caries, and the clinical presentation mimics a rhinolith, such as in this case.

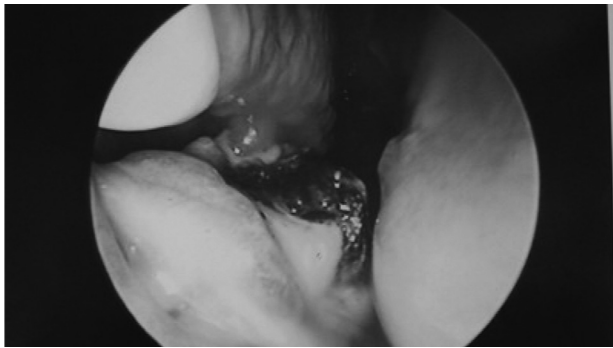


Figure 1: Rhinolith-like material visible during nasal endoscopy

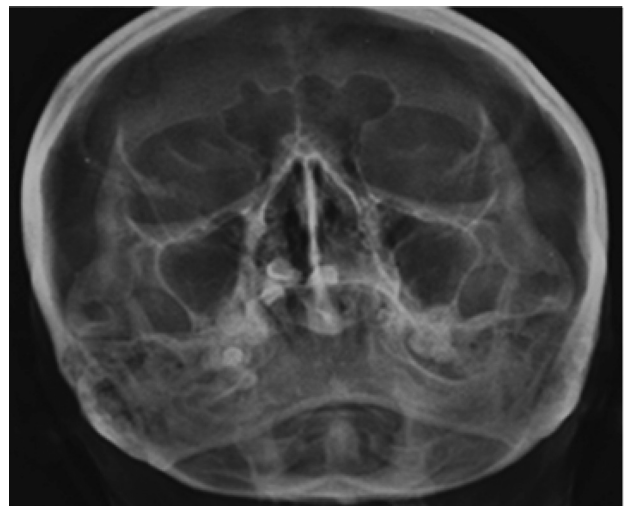


Figure 2: Preoperative radiograph showing a radio-opaque lesion within the right nasal cavity

#### CASE REPORT

A 33-year-old Malay lady, was under follow up for allergic rhinitis for 5 years in our clinic but defaulted in between for the last 2 years when she felt well. She presented with 3-month history of right nasal

1. Maryam Koosha, Department of Otorhinolaryngology-Head & Neck Surgery, School of Medical Sciences, Universiti Sains Malaysia Health Campus, 16150 Kota Bharu, Kelantan, Malaysia
2. Anusha Balasubramanian, Department of Otorhinolaryngology-Head & Neck Surgery, School of Medical Sciences, Universiti Sains Malaysia Health Campus, 16150 Kota Bharu, Kelantan, Malaysia
3. Irfan Mohamad, Department of Otorhinolaryngology-Head & Neck Surgery, School of Medical Sciences, Universiti Sains Malaysia Health Campus, 16150 Kota Bharu, Kelantan, Malaysia
4. Wan Faiziah Wan Abdul Rahman, Department of Pathology, School of Medical Sciences, Universiti Sains Malaysia Health Campus, 16150 Kota Bharu, Kelantan, Malaysia

**Correspond to:** Dr Irfan Mohamad, Department of Otorhinolaryngology-Head & Neck Surgery, School of Medical Sciences, Universiti Sains Malaysia Health Campus, 16150 Kota Bharu, Kelantan, Malaysia.

Email : [irfan@kb.usm.my](mailto:irfan@kb.usm.my)




Figure 3: The extracted tooth

rhinorrhea, and subsequently blood-stained foul smelling discharge and 2 episode epistaxis. There was no anosmia, or nasal block. She claimed to have had all her deciduous teeth and although she vaguely recalled that her permanent set of teeth might be complete. In later adult life, she was informed by a dentist based on dental radiographic findings that one or two of her teeth was absent or may not be housed in their proper location. She has also had a few extractions for unhealthy teeth due to caries.

The patient was a mouth breather with hyponasal speech. There was a reduced cold spatula test on the right side otherwise there was no swelling at columella or cheek region. Endoscopic nasal examination revealed a calcified, brownish rhinolith hard in consistency during probing and no contact bleeding (Figure 1). Pre-operative radiographs (occipito-mental view) showed the presence of a radio-opaque lesion at the lateral wall of right inferior turbinate with a tooth-like appearance (Figure 2). It measured 0.9cm x0.7cm. Oral cavity examination revealed multiple teeth absence (molars, premolars and incisors).

Intraoperatively, the mass was hard in nature. Upon clearing the secretion, it appeared to be a tooth lying horizontally on the floor of the nose. The chewing surface of the enamel had caries and

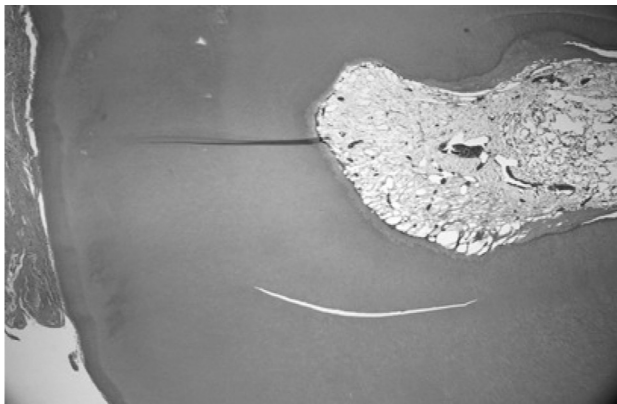


Figure 4a: The tooth is composed of dentine, covered by predentine with central pulp cavity

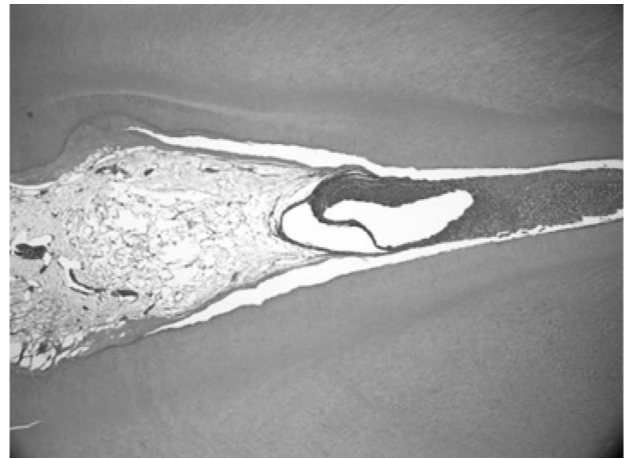


Figure 4b: Pulp cavity with microabscess in root canal

appeared brown-to-black in color, which was probably the material thought to be a rhinolith. The remaining surface of the crown was visible, whereas the neck and root were embedded within mucosa. The mucosa surrounding the tooth was incised and the tooth gently dislodged in a rocking manner from the floor of the nose. It was successfully extracted endoscopically. It appeared to be a premolar (Figure 3). The hard palate was intact post extraction, hence alleviating the possibility of an oro-nasal fistula.

The specimen was sent for pathology review. Grossly the specimen was a tooth, an adult premolar evidenced by small pulp cavity and longer root. Histopathological examination showed a premolar tooth structures evidenced by a dentine, covered by well-organized enamel, central pulp cavity and root canal with neutrophilic accumulation within it, forming a microabscess (Figures 4a-c). The mucosa of the floor of the nose had completely healed well at 6 weeks post surgery. A repeat radiograph showed no abnormality.



Figure 4c: Note the microabscess formation within the root canal

## Discussion

Rhinoliths are calcified petrification formed by the deposition of salts on an intranasal foreign body. A foreign body which acts as a nucleus for calcification can be either endogenous or exogenous in origin. Dried blood clots, ectopic teeth, and bone fragments are examples of endogenous matter. Exogenous materials include cotton wool, fruit seeds, plant material and beads. Cherry pits are commonest reported foreign bodies<sup>1</sup>.

Before permanent teeth erupt into the oral cavity and are visible, they move through the bone along their 'path of eruption'<sup>2</sup>. The tooth will erupt in the mouth in a wrong position when the eruption path is incorrect. This uninvited eruption is called 'ectopic eruption'. It often occurs when there is insufficient space in the jawbones for the teeth. A tooth is called supernumerary if it is an extra tooth, regardless of shape or size. In the primary dentition, the incidence is said to be 0.3% to 0.8% and in the permanent dentition 1.5% to 3.5%<sup>3</sup>.

Mechanisms of ectopic eruption are not completely understood. Nevertheless, some theories have been suggested, including a developmental return to the dentition of primates with three pairs of incisor teeth<sup>4</sup>, defect in migration of neural crest derivatives to reach the jaw<sup>5</sup>, or a multi-step epithelial-mesenchymal interaction<sup>5,6</sup>. Ectopic eruption of teeth may happen nearby the orbit, chin, maxillary sinus, palate and even nose<sup>7</sup>. The ectopic eruption of the teeth into the nasal cavity is a rare phenomenon.

Most cases of supernumerary teeth are asymptomatic and usually discovered with routine examination and radiographs. Sometimes ectopically erupted teeth cause unilateral or bilateral nasal obstruction, epistaxis, a purulent or blood-stained nasal discharge, facial pain, chronic localized ulceration, deviated nasal septum, necrotic or granulation tissue in the nasal cavity, a rhinolith, paranasal sinusitis, or a nasal oral fistula<sup>8-10</sup>. However, when complications are anticipated including retained or

delayed eruption of permanent teeth, displacement, rotation, crowding, root resorption, periodontal lesions, or pulp necrosis of adjacent teeth and odontogenic cyst, removal of the supernumerary tooth is indicated<sup>11</sup>.

The diagnosis of an ectopic or supernumerary tooth is based on clinical and radiological findings. Clinically, intranasal teeth noted most often on the floor of the nasal cavity, and looks like a white mass without any covering, or a tumor-like lesion surrounded by granulation and necrotic tissue. Differential diagnoses that can bring up include a foreign body, rhinolith, benign or malignant tumor, inflammatory change with calcification, tuberculosis, fungal infection, osteoma, exostosis, odontoma, or a cyst lesion<sup>10,12</sup>. Radiological investigations help to differentiate between these possibilities. Water's or Caldwell's views, a lateral view of the skull panoramic radiography may be helpful in diagnosis and management, perhaps even showing a specific, radio-opaque and well-differentiated tooth.

Transnasal and transpalatal approaches are the most common surgical approaches. Involvement of structures next to the tooth and potential complications due to extraction of tooth detect operative methods<sup>9,10</sup>. Trans-nasal endoscopic approach is recommended for extraction of nasal teeth since it suggest clear visualization, good illumination, precise dissection and decrease injury to adjacent structures<sup>10,13</sup>.

## Conclusion

An ectopic nasal tooth may be mistaken for a rhinolith. It is wise to bear in mind of the possibility of an intranasal tooth especially so in a patient with abnormal dentition. The diagnosis of nasal tooth can be determined from clinical and radiographic examinations. Clinically, nasal tooth presents itself as hard white masses, located in the nasal cavity and surrounded by granulation tissue and debris. Removal of nasal teeth is generally advocated to alleviate the symptoms and prevent complications.

## REFERENCES

1. Ishwar Singh, Geeta Gathwala, Yadav SPS, Singh I. Rhinolith. *Indian J Otolaryngol Head Neck Surg.* 2003;**55**(4): 243–245. <http://dx.doi.org/10.1007/BF02992429>
2. Syed Mohammed Yaseen, Saraswati Naik, Uloopi KS. Ectopic eruption - A review and case report. *Contemp Clin Dent.* 2011; **2**(1): 3–7. <http://dx.doi.org/10.4103/0976-237X.79289>
3. Mason C, Azam N, Holt RD, Rule DC. A retrospective study of unerupted maxillary incisors associated with supernumerary teeth. *Br J Oral Maxillofac Surg.* 2000;**48**: 6–8. <http://dx.doi.org/10.1054/bjom.1999.0210>
4. Thawley SE, Ferriere KA. Supernumerary nasal tooth. *Laryngoscope* 1977;**87**:1770–1773. <http://dx.doi.org/10.1288/00005537-197710000-00025>
5. Ray B, Singh LK, Das CJ, Roy TS. Ectopic supernumerary tooth on the inferior nasal concha. *Clin Anat* 2006;**19**: 68–74. <http://dx.doi.org/10.1002/ca.20161>
6. Büyükkurt MC, Tozoglu S, Aras MH, Yolcu Ü. Ectopic eruption of a maxillary third molar tooth in the maxillary sinus: a case report. *J Contemp Dent Pract* 2005;**3**(6):104–110.
7. Di Felice R, Lombardi T. Ectopic third molar in the maxillary sinus. Case report. *Aust Dent J.* 1995;**40**(4): 236–237. <http://dx.doi.org/10.1111/j.1834-7819.1995.tb04802.x>
8. Smith RA, Gordon NC, De Luchi SF. Intranasal teeth. Report of two cases and review of the literature. *Oral Surg Oral Med Oral Pathol.* 1979;**47**:120-122. [http://dx.doi.org/10.1016/0030-4220\(79\)90163-4](http://dx.doi.org/10.1016/0030-4220(79)90163-4)
9. Murty PS, Hazarika P, Hebbar GK. Supernumerary nasal teeth. *Ear Nose Throat J* 1988;**67**:128-129.
10. Lee FP. Endoscopic extraction of an intranasal tooth: a review of 13 Cases. *Laryngoscope* 2001;**111**:1027-1031. <http://dx.doi.org/10.1097/00005537-200106000-00017>
11. Arun K, Ritu N, Lokesh B, Samir D. Supernumerary teeth: Report of four unusual cases. *Contemp Clin Dent.* 2012; **3**: S71–S77. <http://dx.doi.org/10.4103/0976-237X.95110>
12. Chen A, Huang JK, Cheng SJ, Sheu CY. Nasal teeth: report of three cases. *A JNR Am J Neuroradiol.* 2002;**23**: 671-673.
13. Spencer MG, Couldery AD. Nasal tooth. *J Laryngol Otol.* 1985;**99**:1147-1150. <http://dx.doi.org/10.1017/S0022215100098327>