

Case report

**Duplication unilateral femoral vein**

*Ferreira Arquez H*

**Abstract:**

**Background:** The purpose of this paper is to describe a case of duplication of unilateral femoral vein, with a complete extension of duplicated veins with similar diameters which is an uncommon condition, noticed in fewer than 10% of lower limb. The venous anatomy is highly variable, only 1/6 patients are exempt of these anomalies. One is the duplicity of the femoral vein. The classic anatomic venous in the lower limb is found in only 16% of subject. **Methods:** Anatomical variation in the lower limb was found during routine dissection in a 75-year-old male cadaver in the Morphology Laboratory at the University of Pamplona. **Result:** In the adductor canal femoral vein was divided into two veins: one medial and other lateral, which ascended in parallel until the femoral triangle, at this level 6.5 cms below the inguinal ligament the femoral vein- lateral ramus received to the lateral circumflex femoral vein, and received to the medial circumflex femoral vein, followed the femoral veins lateral ramus binds to the femoral veins medial ramus forming common femoral vein. Both Femoral Veins extend from the adductor canal to the femoral triangle had a length of 18 cms. The caliber of the femoral vein and the caliber of common femoral vein was 30 mm. The caliber of the femoral artery at the femoral triangle was 24 mm. The caliber of the femoral medial and lateral venous component was 20 mm. The common femoral vein received posterolateral to the deep femoral vein; The common femoral vein received anteromedial at the great saphenous. **Conclusion:** Knowledge of the truncular venous variations is important for the investigation of the venous network. It is also important to recognize and avoid potential errors in diagnosis of deep venous thrombosis of the femoral vein, in the case of an occluded duplicated trunk.

**Keywords:** femoral vein; duplication; common femoral vein; anatomical variation; lower limb; deep vein thrombosis

*Bangladesh Journal of Medical Science Vol.14(3) 2015 p.292-296  
DOI: <http://dx.doi.org/10.3329/bjms.v14i3.19482>*

**Introduction**

The femoral vein accompanies the femoral artery, beginning at the opening in adductor magnus as the continuation of the popliteal vein, and ending at the level of inguinal ligament, by becoming the external iliac vein. In the lower part of the adductor canal it is posterolateral to the femoral artery; in the upper part of the canal, and in the lower part of the femoral triangle, it is behind the artery. At the base of the femoral triangle it is medial to the artery. The femoral vein has numerous muscular tributaries. The deep femoral vein joins the femoral vein posteriorly 4–12 cm distal to the inguinal ligament, and the great saphenous vein then enters anteriorly. Lateral and medial circumflex femoral veins are usually tributaries of the femoral vein<sup>1</sup>. The complex embryologic development of the vascular system often results in a myriad of clinically relevant

variants. It has been stated that the classic anatomic venous pattern in the lower extremity is found in only 16 percent of patients<sup>1</sup>. One of the most common anatomical variations is the duplicity of the femoral vein. This duplicity favours the vein thrombosis in one of its branches with special clinical features such as the absence of symptoms in the affected limb and the early triggering of the pulmonary embolism<sup>2,3</sup>. The femoral region of the thigh is utilized for various clinical procedures, both open and closed, particularly with respect to arterial and venous cannulations. Femoral vein catheterization is the easiest and safest method for obtaining temporary vascular access in hemodialysis patients, deep vein transposition reconstruction surgery of the opposite limb. Venous pattern particularly in the lower limbs is of great clinical importance, while ligating the veins to prevent the spread of deep vein thrombosis

**Corresponds to:** Humberto Ferreira Arquez, Morphology Laboratory Coordinator & Professor Human Morphology, Medicine Program, University of Pamplona, University Campus-Kilometer 1 - Via Bucaramanga, Pamplona, Norte de Santander- Colombia- Suramérica, Email: [humfear@unipamplona.edu.co](mailto:humfear@unipamplona.edu.co)

<sup>1</sup>. The purpose of this paper is described a case of duplications unilateral of femoral vein, with a complete extension duplicated veins with similar diameters which is an uncommon conditions, noticed in fewer than 10% of lower limb.

### **Materials and methods**

The described anatomic variation were found in the right side of a male cadaver of 75 years of age during routine lower limb dissection in the Morphology Laboratory at the University of Pamplona developed by training medical students. The history of the individual and the cause of death are not known. The topographic details were examined by casual dissection and the variations were recorded and photographed.

### **Results:**

Right lower limb:

The femoral vein on the right side was posterolateral to the femoral artery as it entered the adductor canal at the adductor hiatus. In the adductor canal it divided into two veins, one medial ramus and other lateral ramus, which ascended perpendicular until the femoral triangle, at this level 6.5 cms below the inguinal ligament the femoral vein- lateral ramus received to the lateral circumflex femoral vein, and received to the medial circumflex femoral vein, followed the femoral veins lateral ramus binds to the femoral veins medial ramus forming a common venous trunk (CFV: common femoral vein) located posterior to the femoral artery. Both femoral veins extend from the adductor canal to the femoral triangle had a length of 18 cms. The caliber of the femoral vein at nivel of adductor canal and the caliber of common femoral vein at nivel of femoral triangle was 30 mm. The caliber of the femoral artery at the femoral triangle was 24 mm. The caliber of the femoral vein at the femoral triangle was much larger that the femoral artery. The caliber of the medial and lateral component venous was 20 mm. Four (4) cms below the inguinal ligament the common femoral vein received posterolateral to the deep femoral vein; three (3) cms below the inguinal ligament the common femoral vein received anteromedial at the great saphenous. (Figure 1).

The femoral vein on the left side showed no variations.

### **Discussions**

The reported incidence of multiple femoral veins has varied between 6% and 38% depending on the study population and the employed modalities <sup>2,4-9</sup>. The duplex ultrasonography (US) studies have consistently demonstrated lower rates (6-25%) of multiple

femoral veins compared to that of the venographic studies, which have reported rates of 31% and 33% <sup>2,6</sup>. Park et al. (2011) using CT venography, multiple femoral veins were found in 27% of the limbs, and 29% of the limbs had either multiple femoral veins or popliteal veins, also demonstrated that 40% of the patients had multiple femoral veins and 43% of the patients had multiple femoral veins or Popliteal veins in either leg<sup>10</sup>. Per-patient results of Park et al.<sup>10</sup> are similar to that of Screamon et al.<sup>3</sup>, who examined 381 venograms and found that 46% of their patients had duplicated or multiple femoral veins. With respect to the length of the duplicated femoral veins, the results of Park et al.<sup>10</sup> are in concordance with those of Quinlan et al.<sup>2</sup>, who reported that 6-15 cm was the most common length found in 62% of the duplicated femoral veins. Uhl et al.(2010) in their dissection study on fresh non-embalmed cadavers reported that venous malformations (truncular forms) occurring during the late development of the embryo produce several anatomical variations in the number and caliber of the main venous femoral trunks at the thigh level <sup>11</sup>. They concluded that the modal anatomy of the femoral vein was found in 308 of 336 limbs (88%). Truncular malformations were found in 28 of 336 limbs (12%); unitruncular configurations in 3% (axo femoral trunk 1% and deep femoral trunk 2%). Bitruncular configurations were found in 9% (bifidity of the femoral vein (2%), femoral vein with axio-femoral trunk (5%), and femoral vein with deep femoral trunk 2%). Though truncular venous malformations of the femoral vein are not rare (12%), their knowledge is important for the investigation of the venous network, particularly the venous mapping of patients with cardiovascular disease <sup>1</sup>.

Casella et al. (2010) observed that the most common isolated anatomic pattern was the presence of a single femoral vein. However, all forms of femoral veins duplicity together were seen in more than half of all limbs; only 28 (8.9%) limbs had fully symmetric duplicated femoral veins <sup>12</sup>, very distinct results of venous duplicity in comparison with other reports<sup>4,9</sup>. The clinical importance of identifying duplicated femoral veins and their possible impact on deep vein thrombosis diagnosis has been previously pointed out by other authors. It is also important to recognize a bitruncular configuration to avoid potential errors for the diagnosis of deep venous thrombosis of the femoral vein, in the case of an occluded duplicated trunk. Screamon et al (1998) observed that in patients presenting femoral vein duplication, duplex scan misdiagnosis for deep vein thrombosis was higher

than in individuals with a single femoral vein, in your retrospective review of 381 venograms obtained after initial ultrasound findings were considered negative for thigh or popliteal thrombosis in patients in whom deep vein thrombosis was suspected<sup>3</sup>. False-negative ultrasound findings occurred in four (2%) of 204 patients with single femoral veins and in 10 (6%) of 177 patients with duplicated femoral veins. They made an important inference that the frequency of missed proximal thrombosis at ultrasound appears to be increased when duplicated superficial femoral veins are present, and imaging studies are insufficient to support the adoption of a totally noninvasive imaging strategy.

Liu et al.<sup>6</sup> in a venographic study of 337 limbs in 256 patients found that the incidence of deep vein thrombosis was two times higher than that in the limbs with a single femoral vein, observed a higher

prevalence of deep vein thrombosis in individuals with multiple femoral veins. There were also a higher proportion of asymptomatic deep vein thrombosis patients presenting duplicated veins, which could be explained by the collateral pathways provided by the accessory veins and their natural relief for blood congestion. That author suspected that the higher prevalence of deep vein thrombosis in individuals with multiple femoral veins could be explained by an increased blood volume in the venous limb pool, resulting in a slower flow rate and a predisposition to thrombosis. Dona et al. designed a study to determine the incidence of duplications in individuals presenting for venous incompetence studies, and whether their presence could, in theory, act as a predisposing factor to deep vein thrombosis formation<sup>9</sup>. Duplex ultrasound examinations were performed in which venous duplications were actively searched for

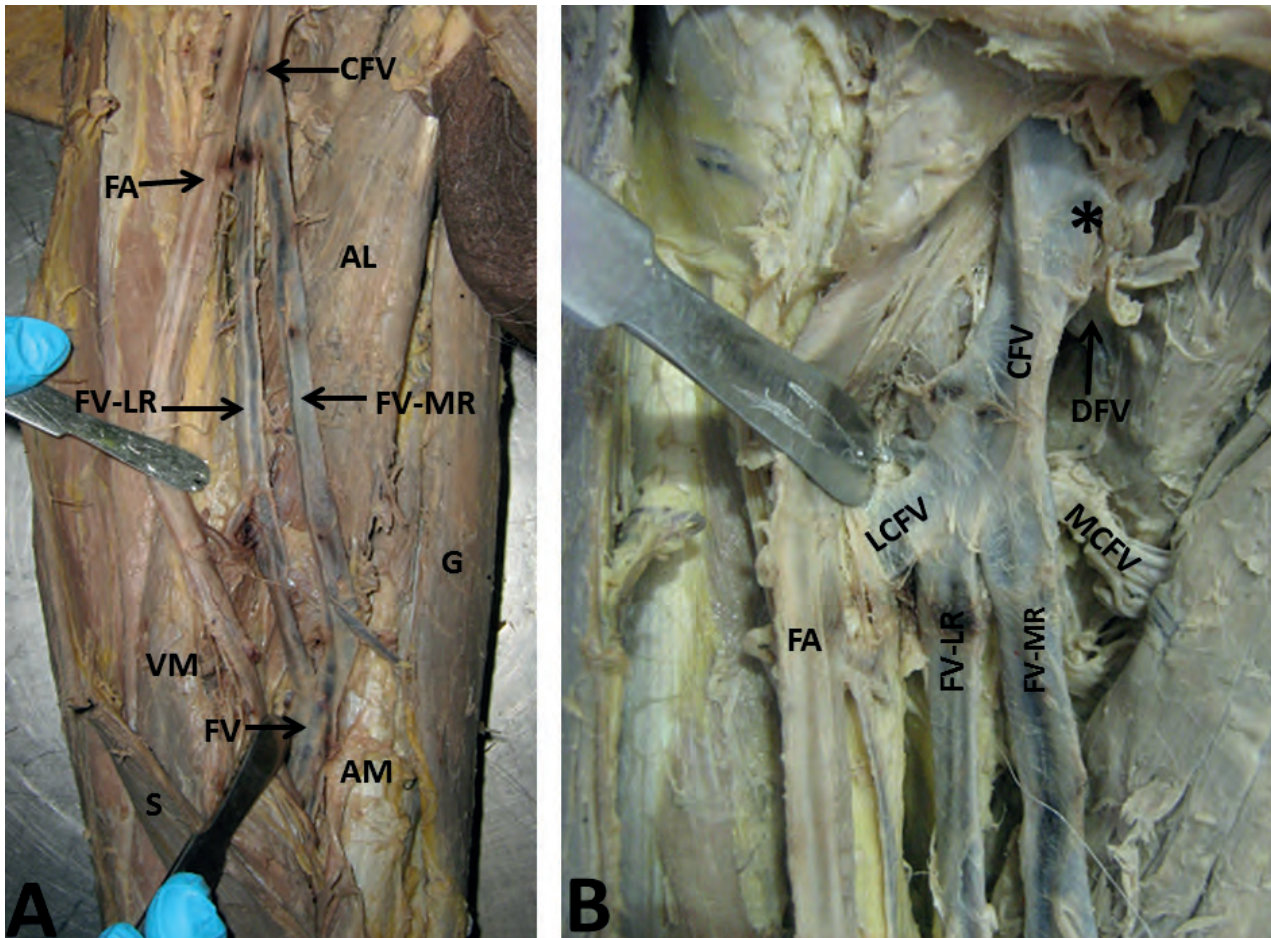


Figure 1. Right lower limb. A. Dissection of the adductor canal and view anterior of thigh: AM: adductor magnus muscle; VM: vastus medialis muscle; G: gracilis muscle; AL: adductor longus muscle; S: sartorius muscle; FA: femoral artery; CFV: common femoral vein; FV: femoral vein; FV-MR: femoral vein- medial ramus; FV-LR: femoral vein- lateral ramus. B. Dissection of the femoral triangle: asterisk: common femoral vein received at the great saphenous vein (cut); LCFV: lateral circumflex femoral vein; MCFV: medial circumflex femoral vein; DFV: deep femoral vein; FV-MR: femoral vein- medial ramus; FV-LR: femoral vein- lateral ramus.

and recorded. The diameters of both limbs of any duplicated system and the single vessel immediately distal to it were recorded. Using these measurements, the changes in total cross-sectional area associated with these variants was calculated. In addition, with the knowledge that the volume flow rate must remain constant, the velocity changes associated with such systems were calculated. Short-segment femoral vein duplications were used to calculate the percentage change in total cross-sectional area and therefore blood flow velocities. Of the 13 (33%) suitable for such calculations, and calculating for each individual duplicated system, a mean increase in the vessel's total cross-sectional area of 42%, which corresponded to a theoretical decrease in blood flow velocity of 36%, was found. The study confirmed the significantly high incidence of duplications of the popliteal vein and femoral vein and the increase in the possibility of the potential for deep vein thrombosis formation secondary to changes in flow velocities. Perhaps the high incidence of deep vein thrombosis in multiple femoral veins can be explained by increased blood volume in the venous pool and conversely a decrease flow rate, which probably predisposes the limb to deep vein thrombosis<sup>1,9,13,14</sup>. The majority of pulmonary emboli arise from the proximal deep venous system of the lower limbs<sup>15,16</sup>, and therefore, accurate assessment of this area is of particular importance, more so when the incidence of duplication of the superficial femoral vein is as high as (30%)<sup>2</sup>. The femoral vein also described by the inaccurate term "superficial femoral vein"<sup>17</sup>.<sup>18</sup> Duplication of the superficial femoral vein is a recognized antecedent of missed proximal thrombus at Ultrasonography<sup>3,6,19</sup>, with the incidence being twice as high in patients with a duplicated superficial femoral vein compared with those with a single superficial femoral vein<sup>6</sup>. In a review of 269 cases of acute lower limb proximal deep venous thrombosis, Maki et al<sup>20</sup> showed that 22% of thrombi were isolated to the superficial femoral vein, with the remaining 78% having thrombus extending into the common femoral or popliteal veins or both. Thus, assessment of the superficial femoral vein is often of great importance in the establishment of more than 20% of all lower limb deep venous thrombosis<sup>6</sup>. Therefore, like other authors<sup>20,21</sup>, cannot support

the suggestion that it is safe to exclude superficial femoral vein in Ultrasonography assessment of the lower limb<sup>2</sup>. Femoral veins have been widely used as vascular substitutes, especially in delicate situations. Since initial reports, femoral vein has been the first, if not the only, choice of substitute for in situ reconstruction of the aortoiliac tree when prosthetic infection is present. Casella et al<sup>22</sup> observed, 99.0% of the main femoral veins and 25.4% of the accessory veins presented diameters superior to 6 mm, a suitable value for iliac substitution. Infrainguinal bypass surgery is another possible application for femoral vein as substitutes when the conventional options are depleted<sup>23</sup> or infection is present. Diameters between 3 mm and 7 mm were observed in 17.2% of the main femoral veins and 79.1% of the accessory veins. Since these vessels are usually short for complete substitution in infrainguinal bypass procedures, they could be used in combination with saphenous or arm veins to cover the necessary extension. Theoretically, main femoral vein harvesting for use as a substitute would be more tolerated in patients with duplicated systems, as venous flow originating from leg veins would naturally be redirected to accessory femoral veins<sup>22</sup>.

### Conclusion

Femoral vein duplication is a common anatomical variant of the lower limb deep venous system. The presence of anomalies in the deep vein system can be the underlying cause of silent thrombosis that present with pulmonary embolism as the first clinical manifestation. It should also be noted that a thrombus is more likely to be seen in one canal of a duplicated femoral vein than in the usual anatomy. Thus, a thrombus in that canal could be easily missed on ultrasound. Furthermore, for the surgeon, femoral vein duplication could provide the opportunity to use one of the trunks for deep vein transposition reconstruction surgery of the opposite limb.

### Acknowledgements

The author, on behalf of the University of Pamplona thanked to the Erasmo Meoz University Hospital for the donation of cadavers identified, unclaimed by any family, or persons responsible for their care, process subject to compliance with the legal regulations in force in the Republic of Colombia.

## References

- 1- Sharma P, Salwan. Duplication of femoral vein and its significant clinical implications. *IJAV* 2011; **4**: 188–191.
- 2- Quinlan DJ, Alikhan R, Gishen P, Sidhu PS. Variations in LowerLimbVenousAnatomy:ImplicationsforUSDiagnosis of Deep Vein Thrombosis. *Radiology* 2003; **228**: 443-8 <http://dx.doi.org/10.1148/radiol.2282020411>
- 3- Screation NJ, Gillard JH, Berman LH, Kemp PM. Duplicated Superficial Femoral Veins: A Source of error in the Sonographic Investigation of Deep Vein Thrombosis. *Radiology* 1998; **206**: 397- 401. <http://dx.doi.org/10.1148/radiology.206.2.9457192>
- 4- Gordon AC, Wright I, Pugh ND. Duplication of the superficial femoral vein: recognition with duplex ultrasonography. *Clin Radiol* 1996;**51**:622-624 [http://dx.doi.org/10.1016/S0009-9260\(96\)80055-9](http://dx.doi.org/10.1016/S0009-9260(96)80055-9)
- 5- Kerr TM, Smith JM, McKenna P, Lutter KS, Sampson MG, Helmchen RH, et al. Venous and arterial anomalies of the lower extremities diagnosed by duplex scanning. *Surg Gynecol Obstet* 1992;**175**:309-314
- 6- Liu GC, Ferris EJ, Reifsteck JR, Baker ME. Effect of anatomic variations on deep venous thrombosis of the lower extremity. *AJR Am J Roentgenol* 1986;**146**:845-848 <http://dx.doi.org/10.2214/ajr.146.4.845>
- 7- May R. Surgery of the legs and veins of the leg and pelvis. Philadelphia, PA: Saunders, 1979:4
- 8- Thomas ML. Phlebography of the lower limb. New York, NY: Churchill Livingstone, 1982:162-163
- 9- Dona E, Fletcher JP, Hughes TM, Saker K, Batiste P, Ramanathan I. Duplicated popliteal and superficial femoral veins: incidence and potential significance. *Aust N Z J Surg* 2000;**70**:438-440. <http://dx.doi.org/10.1046/j.1440-1622.2000.01855.x>
- 10- Park EA, Chung JW, Lee W, Yin YH, Ha J, Kim SJ, Park JH. Three-dimensional evaluation of the anatomic variations of the femoral vein and popliteal vein in relation to the accompanying artery using CT venography. *Korean J Radiol* 2011 May-Jun;**12**(3):327-40. <http://dx.doi.org/10.3348/kjr.2011.12.3.327>
- 11- Uhl JF, Gillot C, Chahim M. Anatomical variations of the femoral vein. *J Vasc Surg* 2010; **52**: 714–719. <http://dx.doi.org/10.1016/j.jvs.2010.04.014>
- 12- Casella IB, Presti C, Yamazaki Y, Vassoler AA, Furuya LA, Sabbag CD. A duplex scan-based morphologic study of the femoral vein: incidence and patterns of duplication. *Vasc Med* 2010 Jun;**15**(3):197-203. <http://dx.doi.org/10.1177/1358863X09358918>
- 13- Sigel B, Edelstein AL, Felix WR Jr, Memhardt CR. Compression of the deep venous system of the lower leg during inactive recumbency. *Arch Surg* 1973; **106**: 38–43. <http://dx.doi.org/10.1001/archsurg.1973.01350130040009>
- 14- Sevitt S. Etiology and pathogenesis of deep vein thrombosis. *Lancet* 1960; **275**: 384–385. [http://dx.doi.org/10.1016/S0140-6736\(60\)90312-3](http://dx.doi.org/10.1016/S0140-6736(60)90312-3)
- 15- Hull RD, Hirsh J, Carter CJ, et al. Pulmonary angiography, ventilation lung scanning, and venography for clinically suspected pulmonary embolism with abnormal perfusion lung scan. *Ann Intern Med* 1983; **98**:891–899. <http://dx.doi.org/10.7326/0003-4819-98-6-891>
- 16- Girard P, Musset D, Parent F, Maitre S, Phlippoteau C, Simonneau G. High prevalence of detectable deep venous thrombosis in patients with acute pulmonary embolism. *Chest* 1999; **116**:903–908. <http://dx.doi.org/10.1378/chest.116.4.903>
- 17- Caggiati A, Bergan JJ, Gloviczki P, Jantet G, Wendell-Smith CP, Partsch H; International Interdisciplinary Consensus Committee on Venous Anatomical Terminology. Nomenclature of the veins of the lower limbs: an international interdisciplinary consensus statement. *J Vasc Surg* 2002; **36**: 416–422. <http://dx.doi.org/10.1067/mva.2002.125847>
- 18- Federative International Committee on Anatomical Terminology. Terminologia Anatomica. Stuttgart: Thieme, 1998.
- 19- Quinn KL, Vandeman FN. Thrombosis of a duplicated superficial femoral vein: potential error in compression ultrasound diagnosis of lower extremity deep venous thrombosis. *J Ultrasound Med* 1990; **9**:235–238.
- 20- Maki DD, Kumar N, Nguyen B, Langer JE, Miller WT Jr, Gefter WB. Distribution of thrombi in acute lower extremity deep venous thrombosis: implications for sonography and CT and MR venography. *AJR Am J Roentgenol* 2000; **175**:1299–1301. <http://dx.doi.org/10.2214/ajr.175.5.1751299>
- 21- Ascani A, Radicchia S, Parise P, Nenci GG, Agnelli G. Distribution and occlusiveness of thrombi in patients with surveillance detected deep vein thrombosis after hip surgery. *Thromb Haemost* 1996; **75**:239–241.
- 22- Casella IB, Presti C, Yamazaki Y, Vassoler AA, Furuya LA, Sabbag CD. A duplex scan-based morphologic study of the femoral vein: incidence and patterns of duplication. *Vasc Med* 2010 Jun;**15**(3):197-203. <http://dx.doi.org/10.1177/1358863X09358918>
- 23- Wozniak G, Görtz H, Akintürk H, Dapper F, Hehrlein F, Alemany J. Superficial femoral vein in arterial reconstruction for limb salvage: outcome and fate of venous circulation. *J Cardiovasc Surg (Torino)* 1998; **39**: 405–411.