

**Case report**

**Foreign Body in abdomen**

Alam Z<sup>1</sup>, Aziz M<sup>2</sup>

**Abstract:**

A 19 years old married female presented with severe upper abdominal pain, repeated vomiting having history of swallowing a knife 7 months ago was admitted in Mordern Clinic and Diagnostic center, Joypurhat, Bangladesh. USG abdomen & X-ray (fig-1) abdomen were done when presence of a large foreign body (knife fig-3) in abdomen was made which latter on confirmed by Endoscopy of upper GIT (fig-2). Surprisingly the patient kept it in her abdomen for 7 months without any symptoms until the symptoms got worse and compelled her to seek medical help. The knife was removed by laparotomy, gastrotomy with uneventful recovery.

DOI: <http://dx.doi.org/10.3329/bjms.v14i2.22775>

Bangladesh Journal of Medical Science Vol.14(2) 2015 p.210-212

**Introduction**

Accidental ingestion of foreign bodies like needles, pin, safty pin, blade, fish/meat bones, coins are not uncommon. There are many evidences world wide and reported in medical books, journals, booklets etc<sup>1-4</sup>. Children are the usual victims<sup>3</sup>. Prisoners, patient with anorexia nervosa, psychiatric illness are also reported. Majority would pass Spontaneously

without any complications. Occasionally large and sharp foreign bodies may get stuck and give rise to complications like perforation of gut wall and migration, peritonitis, obstruction even fixation at ano-rectal regions<sup>1,7,8</sup> which are removed by endoscopy, laparotomy and laparoscopy.

**Case Report:**

Mrs. Nurun Nahar - a 19 years married good looking lady , daughter of Md.Lutfar Rahman ,Punchbibi, Jopurhat was admitted in Mordern Clinic

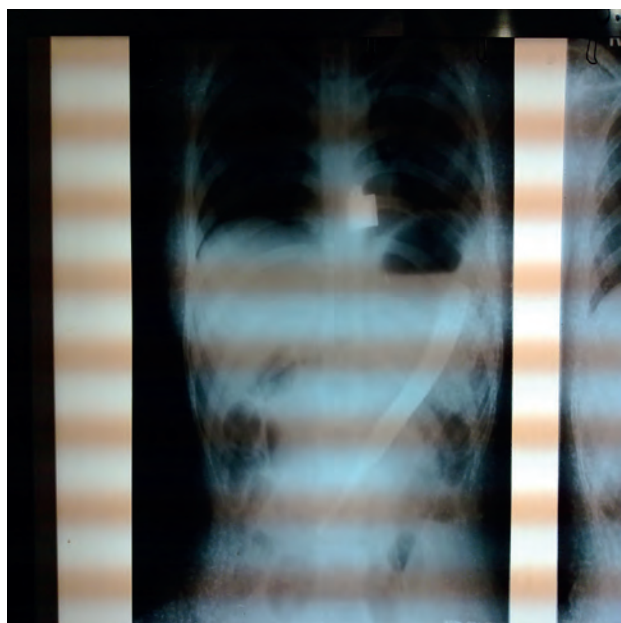


Fig-1: X-ray abdomen showing radio-opaque foreign body in upper abdomen.

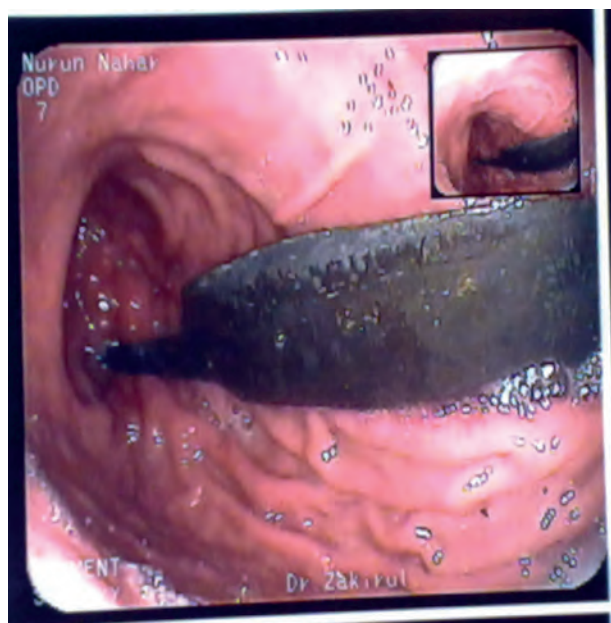


Fig-2: Endoscopic view showing knife in the stomach.

1. Dr. Md. Zakirul Alam, Senior consultant, surgery, 250 Beded hospital, Mohammad Ali Hospital, Bogra, Bangladesh. Email: [drzakirul.alam@yehoo.com](mailto:drzakirul.alam@yehoo.com)
2. Prof. Mohibul Aziz, Professor & Head, Department of Surgery, Ibn Sina Medical College

**Corresponds to:** Dr. Md. Zakirul Alam, Senior consultant, surgery, 250 Beded hospital, Mohammad Ali Hospital, Bogra, Bangladesh. Email: [drzakirul.alam@yehoo.com](mailto:drzakirul.alam@yehoo.com)



Fig-3: Knife removed from stomach measured about 7.5×1.5 inches with one edge sharp cutting and one end pointed.

and Diagnostic Center Joypurhat, Bangladesh on 20.11.2009 with the complaints of severe abdominal pain repeated vomiting for five days. She had history of repeated epigastric pain with infrequent vomiting and was treated by local doctors with omeprazole without further tests. USG abdomen & X-ray abdomen showing doubts about the presence of a large foreign body in abdominal cavity.

She has history of psychiatric illness and mentioned that she had swallowed a solid knife about 7 months back but nobody believed that story. She was treated conservatively for her Mental Disorder.

On examination she was well built patient with average nutrition, pulse-90/min, BP- 130/80 mm of Hg normal temperature having no anemia, jaundice, oedema clinically. There was tenderness muscle guard and rigidity in her upper abdomen with ill define lump around her umbilicus. X-ray abdomen(fig:1) showed a solid curved radio-opaque foreign body in upper abdomen. Upper G I Endoscopy confirmed a large cutting knife in stomach floating in the stomach and other end (pointed) being fixed with penetrating the antral wall of stomach(fig:2).

After initial resuscitation and assessing her fitness for anesthesia laparotomy was done through an upper midline incision. At laparotomy there was feeling of a hard elongated foreign body within the cavity of stomach. The pointed end of the knife had penetrated the antrum and was congested with formation of lump by the adjacent omentum. Gastrotomy was done at

the body of the stomach when a large sharp cutting rigid knife made by local blacksmith was taken out .abdomen was closed after through Peritoneal toileting with a drain. The patient was discharged from the clinic on 10th POD with rapid recovery and advised follow up after one month.

Fig-2: Endoscopic view showing knife in the stomach.

Fig-3: Knife removed from stomach measured about 7.5×1.5 inches with one edge sharp cutting and one end pointed.

#### **Discussion:**

Ingestion of foreign bodies is a common occurrence<sup>4</sup>. Accidental ingestion is frequently caused by dietary foreign bodies like fish bone and chicken bone. Predisposing factors include patient with dentures, patient with history of psychosis<sup>5,8,10</sup>, alcohol abuse and jail inmates(9). But swallowing of large, rigid, sharp knife is unusual. In many cases, a definite history of such foreign body ingestion is not obtained causing no harm to the patients without producing any symptoms.( A writing ball pen in stomach for 25 years<sup>1</sup>. Complication like perforation of gut, peritonitis, migration, liver abscess and intestinal obstruction- common sites being distal ileum, sigmoid colon, rectum. Majority of the foreign bodies pass spontaneously(90%), only 10-20% would require intervention<sup>4</sup>. Management of ingested foreign bodies varies according to the type, size, location and patient age. Removal of the large , sharp, cutting foreign body is recommended due to their potential danger. Various options available include endoscopic, laparoscopic, surgical and laparo-endoscopic removal of foreign bodies from stomach<sup>5,6,12</sup>. Endoscopic removal is successful in children for short duration of impaction. Surgery is required for failed endoscopic procedure. Removal of foreign body from the abdomen gains a popular method now a days<sup>5,6</sup>.

#### **Conclusion:**

Accidental swallowing of foreign bodies like pin, saftypins, needle is not unknown but swallowing of such a large sharp rigid cutting knife is extremely rare and surprising in medical history. The story of keeping such a large rigid sharp knife in stomach for 7 months leading reasonable normal life with minimal symptoms is definitely extraordinary event in medical history. This also highlights the need for eliciting a good medical history even in patient with psychiatric illness.

References:

1. Kota L. Chandrasekhara. Swaminath K. Lyer. And salvatore J.A. Scalafani Foreign Body Perforation of stomach. *J Natt Med Assoc* 1981, **73**(8). 756-758. PMID. PMC 2552678. Journal of National Medical Association(NMA).
2. Golffer C. Holguin F. Kobayashi A. Duodenal perforation because of swallowed ball point pen and its laparoscopic management report of a case. *J pediatr surg* 2009; **44**:634-6[cross ref] [medicine] goole scholar.
3. Abdullah Al –Reesi,MD, Mostafa Ashour MBCH. Foreign body(pen) in the stomach and lower oesophagus, Received: January 12, 2011: Received in revised form :March 12,2011; Accepted: June 2, 2011; Published online: October 10,2011. The Journal of Emergency Medicine( Official Journal of American Academy of Emergency Medicine).
4. Golash Vishwanath. Laparoscopic removal of large and sharp Foreign bodies from Stomach. *Oman Med J. Jan* 2008; **23**(1): 42-45 PMID: PMC 3338989. Oman Medical Journal.
5. Schenk C, Mugomba G, Dabidian RA, Scheuerecker H, Glaser F. Laparoscopic extraction of a swallowed fork in a patient first diagnosed with bulimia nervosa. *Surg Endosc* 2002; **16**(2):36110.1007/s00464-001-4213 [PubMed] [Cross Ref] [PubMed][Cross Ref]
6. Caratozzolo E, Massani M, Antoniutti M, Basso S, Monica F, Jelmoni A, et al. Combined endoscopic and laparoscopic removal ingested large foreign bodies. Case report and decisional algorithm. *Surg Endosc* 2001. ;**15**(10):1226[PubMed]. [PubMed]
7. Stricker T, Kellenberger CJ, Neuhaus TJ, Schwoebel M, Braegger CP. Ingested pins causing perforation. *Arch Dis Child* 2001; **84**(2);165-166 10.1136/adc.84.2.165 [PMC free article] ] [PubMed][Cross Ref] [PMC free article] ] [PubMed][Cross Ref]
8. Rygl M, Pygha K, Perforation of stomach by a foreign body in a girl with anorexia nervosa- case report. *Rozhl Chir* 2002;**81**(12): 628-630[PubMed]. [PubMed]
9. Bisharat M, O'Donnel ME, Gibson N, Mitchell M, Refsum SR, Carey PD,etal. Foreign body ingestion in prisoners – the Belfast experience. *Ulster Med J* 2008; **77**: 110-4.
10. Burhan, Teoman, Erhan, Hasan, Mutlu, Nuri Aydin. Surgically treated foreign body ingestion in a psychiatric patient. *T Klin J Med Sci* 1998; **18**:136-7.
11. Chalk SG, Faucher H. Foreign bodies in the stomach. *Arch Surg* 1928; **16**: 494-500.
12. Wishner JD, Rogers AM. Laparoscopic removal of a swallowed toothbrush. *Surg Endosc* 1997;**11**(5): 472-473 10.1007/s004649900393] [PubMed][Cross Ref] ] [PubMed][Cross Ref]