

Original article:**Morphometry of the glenoid cavity and its correlation with selected geometric measurements of the scapula***Aigbogun (Jr) EO¹, Oladipo GS², Oyakhire MO³, Ibeachu PC⁴***Abstract**

Introduction: An understanding of the normal glenoid cavity morphometry is important in corroborating the basis of luxation at the glenohumeral joint (GHJ). This study was carried out to determine the morphometric relationship of the glenoid cavity to joint stability and device models to estimate glenoid cavity dimensions of the scapular bone of Nigerian origin in a post-mortem skeletal state using selected angles and dimension **Methods:** A total of 200 well-macerated unpaired scapulae bone (96 right and 104 left) with complete ossification were used for this study. Geometric measurements were taken using standard procedures. SPSS (IBM® version 20) was used to analyze the data and the results of all measured parameters (for both sides and total) were presented. Correlation was determined from the summation of the bilateral measurement of; the superior (SSA), inferior (ISA) and medial (SVA) angles of the scapulae, maximum height of the scapula (MHS), and maximum glenoid height and width (MGH and MGW). Glenoid index (GI) was calculated by dividing MGW by MGH. Regression formulae for estimation the glenoid cavity parameters were derived. Significance level was set at 95% ($P \leq 0.05$ was considered significant). **Result:** The mean GI was calculated as $68.18 \pm 5.93\%$ (with min. and max. ratio of 54% and 87% respectively). Of the predictor variables for estimating MGH and MGW, SSA was weakly (-) correlated ($r < 0.2$; $R^2 < 0.1$), MSH was averagely (+) correlated ($r < 0.55$; $R^2 < 0.3$), while a strong (+) correlation was observed between the inter-glenoid cavity dimensions ($r = 0.785$; $R^2 = 0.617$). **Conclusion:** Indices below 50% and above 89% are indications of possible GHJ problems. Using single measurements of various scapular parts to estimate the glenoid cavity is possible. Distortion of the morphometric relationship that exists between MGW and MGH is a clear pointer for glenohumeral luxation syndromes.

Keywords: Correlation, Glenoid cavity; Geometric measurement; Morphometry; Scapular

Bangladesh Journal of Medical Science Vol. 16 No. 04 October '17. Page : 572-579

Introduction

The glenoid cavity (G. socket) is a shallow pear shaped¹, articular fossa located on the lateral angle of the scapula which provides articular surface and sitting for the head of the humerus. The shape of the glenoid cavity and the glenoid labrum which deepens it² gives it its most remarkable feature; as it precisely stabilizes the humeral head in the center of the cavity as well as allowing a vast range of movements³. This balance of stability and mobility achieved by glenoid cavity is as result of a combination of mechanisms particularly its articulation; with its morphological as

well as morphometric arrangements playing a vital role. In spite of the glenoid cavity's lack of a deep socket or isometric ligaments, the normal shoulder accurately constrains the humeral head to the center of the glenoid cavity throughout most of the arc of movement³⁻⁶. However, its small articulating surface areas correlate with greater probability of dislocation^{7,8}. The morphological implication of the glenoid cavity in shoulder stability has been extensively researched^{3,9,10}. There have also been various findings about the scapular anthropometry, kinanthropology and kinematics¹¹⁻¹³. Extensive

1. Eric O. Aigbogun (Jr.), Email: eric_aigbogun@uniport.edu.ng
2. Dr. Gabriel S. Oladipo, E-mail: oladipogabriel@yahoo.com
3. Dr. Mike O. Oyakhiree, Ag. Head of Department, Email: ovbiadolor@gmail.com
4. Dr. (Mrs.) Chinagorom P. Ibeachu, E-mail: chinacute4christ@yahoo.com

Department of Anatomy, College of Health Sciences, University of Port-Harcourt, Port-Harcourt, Rivers State, Nigeria

Correspondence to: Aigbogun e (jr), Department of Anatomy, College of Health Sciences, University of Port-Harcourt, Nigeria, E-mail: eric_aigbogun@uniport.edu.ng <mailto:kyeric007@gmail.com>

investigations have been carried on the shape, size and movements of the scapular in relation to the movements at the shoulder joint^{9,12}, its correlation to body size and stature^{10,14} as well as upper limb geometric measurements¹⁵⁻¹⁷. An understanding of the normal glenoid cavity morphometry is important; since restoration of normal anatomy is the goal in orthopedic surgery. Its basis in injury is of great significance to sports medical professionals and its anthropometry cannot be overlooked by anatomist and medico-legal forensic experts. This knowledge can provide insight into the medical basis of shoulder dislocations and the anthropometric relationship between the glenoid cavity and other scapular geometric measurements will be useful in software remodeling and reconstruction of damaged or missing parts. This study was therefore carried out to determine the morphometric relationship of the glenoid cavity to joint stability and to also device models to estimate measurements of the glenoid cavity of the scapular bone of Nigerian origin in a post-mortem skeletal state using selected angles and dimension.

Materials and methods

The study included 200 well-macerated unpaired scapulae bone (96 right and 104 left) with complete ossification; belonging to the Anatomy Museum of selected Southern Nigerian Universities. The age and sex of the donors of the specimens were not determined and upon careful examination, the scapulae did not present with any external deformity. The glenoid cavity (Figure 1) and selected scapulae angles and distance (Figure 2) were studied.

Data collection

Dimensions of the glenoid cavity

To take the glenoid cavity dimensions, the scapulae were tightly held in anatomical position by a standing clamp; with the lateral border and the glenoid cavity facing anteriorly. Using a sliding digital caliper calibrated to 0.01mm, data were collected in line with measurements protocol by Solanki⁹, Campobasso *et al*¹⁰ and Oladipo *et al*¹⁸. Two (2) anthropometric parameters were measured from the glenoid cavity; maximum glenoid height (MGH), maximum glenoid width (MGW) and the glenoid index (GI) was calculated by dividing MGW by MGH.

Selected scapulae angles and distance

In taking the angular and linear measurements, the scapulae were placed on a plane A4 paper and strategic edges of the scapula pinned on the drawing board in anatomical position (that is; the dorsal surface facing superiorly). The various points pinned

were the superior angle (SSA), inferior angle (ISA) and the sharpest edge at the origin or root of the scapula spine (the spinovertebral angle - SVA) (Fig. 2a&b). Lines (A-B, A-D, B-C, C-D and A-C) were traced from the various pinned points on the paper using a graphite HB pencil and the resultant angles formed were measured using a protractor (Fig. 2a). Guaranteeing minimal error margin, the measurements were repeatedly taken and the average used as the value for each measured parameter.

Landmarks and guide for measurements

1. **MGH:** Maximum height of glenoid fossa (Fig 1. pt. G-H); formed from the maximum distance between the superior border and the inferior border of the glenoid fossa. The MGH is an adjoining line from G-H.
2. **MGW:** Maximum breadth of glenoid fossa (Fig 1. pt. K-L); formed from the maximum distance between the ventral border and the dorsal border of the glenoid, usually around the midpoint of the glenoid fossa. The MGW is an adjoining line from K-L.
3. **SSA:** The angle (\hat{BAD}) formed from the lines (AD and AB) joining most superior point of the scapular to the most medial point of the medial border of the scapula (D); forming the superior-medial border of the scapulae and an adjoining line from the most inferior point of the glenoid cavity (B) to the most pointed edge of the medial border of the scapula (A) (Fig. 1a & b).
4. **IVA:** The angle (\hat{BCD}) formed from the lines (BC and CD) joining the points at the inferior edge of the scapula (C) to the most medial point of the medial border of the scapula (D); forming the inferior-medial border of the scapulae and an adjoining line from the most inferior point of the glenoid cavity (D) to the most pointed inferior part (C) (Fig. 1a & b).
5. **SVA:** The angle (\hat{BDD}) formed from the line (AD and CD) joining most superior point of the scapular to the most medial point of the medial border of the scapula (D) and an adjoining line from the most inferior point of the scapular (C) to the edge of the medial border of the scapula (D) (Fig. 1a & b)¹⁸.
6. **MSH:** (Fig 2 pt. A-B) maximum distance between the most superior point and the most inferior point of the scapula (that is; superior angle to inferior angle).

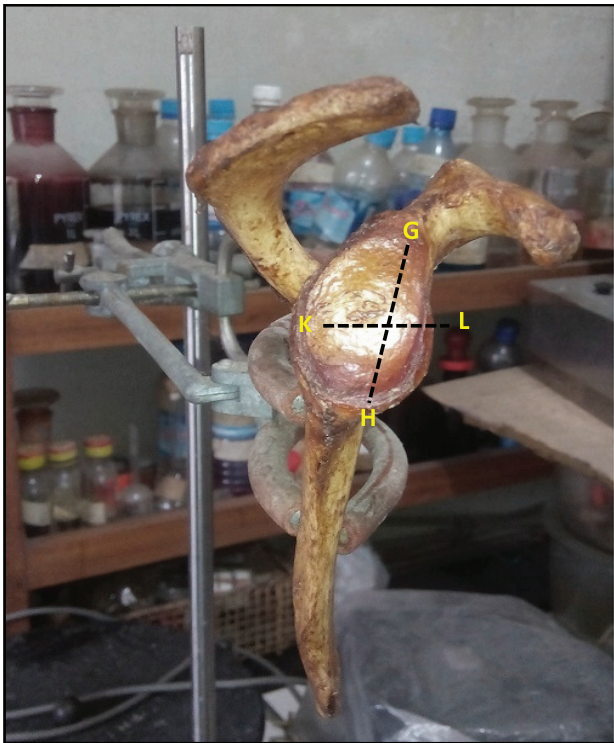

Figure 1: The landmark of the measured glenoid dimensions (line **GH**; Maximum glenoid Height, **KL**; Maximum Glenoid Width. Glenoid Index (GI) = $\frac{KL}{GH}$




Figure 2: a. The measured angles; SVA (\hat{ADC}) SSA (\hat{BAD}) ISA (\hat{BAD}) and MSH (AC) landmarks **b.** Borders of the scapula forming the various angles (line **AB**; superior border, **BC**; lateral border, **AD**; superiormedial border, **DC**; inferior medial border and **AC**; Maximum height).¹⁸

Data analysis

The Data obtained from the measurements were analyzed using Statistical Package for Social Sciences (SPSS IBM®) version 20 and the following analytical methods were employed.

I. **Descriptive statistics:** Use of central tendency and deviations to describe the basic features of the data in this study. The data from this analysis is represented in mean (\bar{x}), standard deviation (S.D) and standard error (S.E).

II. **Analysis of mean difference:** Z-test of was used to test the probability that an observed variable is different from and/or dependent on another variable.

III. **Correlation Analysis:** Pearson's correlation was used to determine the relationship between a dependent variable and one or more independent variables. A model of the relationship was hypothesized, and estimates of the parameter values were used to develop an estimated regression equation.

Ethical Considerations

Ethical clearance was sort from the Research Ethical Committee of the University of Port Harcourt. Authentication of anatomical models obtained from the various institutions were also sort. Other statutory research standards were strictly adhered to.

Results

Measurements related to glenoid cavity dimensions and the scapular geometry were documented in Table 1. The values observed were presented as mean \pm S.D for both sides of the scapula with significant differences indicated as asterisks.

Side comparison

The mean \pm S.D of the SSA was observed to be $94.02 \pm 7.68^\circ$ ($R = 94.36 \pm 8.01^\circ$ and $L = 93.76 \pm 7.45^\circ$), ISA; $52.21 \pm 4.10^\circ$ ($R = 51.23 \pm 4.04^\circ$, $L = 52.70 \pm 5.21^\circ$), and SVA; $136.88 \pm 7.70^\circ$ ($R = 138.13 \pm 7.06^\circ$: $L = 135.92 \pm 8.05^\circ$), MSH; $143.80 \pm 13.84\text{mm}$ ($R = 144.54 \pm 11.84\text{mm}$, $L = 143.24 \pm 15.24\text{mm}$), MGH; $36.87 \pm 3.94\text{mm}$ ($R = 37.71 \pm 4.24\text{mm}$, $L = 36.22 \pm 3.58\text{mm}$), MGW; $25.15 \pm 3.60\text{mm}$ ($R = 26.20 \pm 3.30\text{mm}$, $L = 24.35 \pm 3.64\text{mm}$). The glenoid index was calculated as 69.59 ± 5.53 ($R = 67.11 \pm 6.03$, $L = 68.18 \pm 5.93$). The difference between the left and right sides of the scapula was significant for ISA, MGH, MGW and GI ($P < 0.05$). No significant difference was observed for SVA, SSA and ($P > 0.05$).

Side distribution of the glenoid index (GI)

In Table 2, significant difference in distribution of GI with respect to sides (left and right sides of the scapula) were observed; with the right having a significant higher GI (70-79%) by proportion ($P < 0.01$) while the left was dominant with a lower GI (60-68%). The GI index between 50-59% and 80-89% were also unevenly distributed; but the observed differences were not significant ($P > 0.05$). In total, 87% of the studied glenoid cavity seemed to have index of 60-80% which could be regarded as the morphometric safe index (MSI).

Correlation of scapula measurements with glenoid dimensions

In Table 3, Correlation indexes were not statistically significant for ISA and SVA ($P > 0.05$). Of the predictor variables evaluated for estimating MGH and MGW, SSA was weakest (negatively correlated) with MGH ($r = -0.192$, $R^2 = 0.037$; $P = 0.011$) and MGW ($r =$

0.184 , $R^2 = 0.034$; $P = 0.015$); MSH was averagely (+) correlated with MGH ($r = -0.518$, $R^2 = 0.268$; $P < 0.001$) and MGW ($r = -0.485$, $R^2 = 0.235$; $P < 0.001$), while a strong (+) correlation between the inter-glenoid cavity dimension (MGH vs MGW) was recorded ($r = 0.785$; $R^2 = 0.617$; $P < 0.001$).

Table 1: Descriptive Statistics of the measured parameters of the scapulae

PARAMETERS	R MEAN±SD	L MEAN±SD	TOTAL MEAN±SD
Maximum glenoid height (MGH) (mm)	37.71±4.24**	36.22±3.58	36.87±3.94
Maximum glenoid width (MGW) (mm)	26.20±3.30**	24.35±3.64	25.15±3.60
Glenoid Index (GI) (%)	69.59±5.529**	67.11±6.031	68.18±5.93
Spinovertebral angle (SVA) (°)	136.80±14.70	135.92±8.05	136.30±11.39
Superior scapula angle (SSA) (°)	94.36±8.01	93.76±7.45	94.02±7.68
Inferior scapula angle (ISA) (°)	51.23±4.04	52.70±5.21*	52.21±4.10
Maximum scapula height (MSH) (mm)	144.54±11.84	143.24±15.24	143.80±13.84

*Note: the side with the asterisk is significantly greater than the other; at * $P < 0.05$, ** $P < 0.01$*

Table 2: Percentage distribution of the glenoid index

Glenoid Index (GI)	RIGHT SIDE (RT)		LEFT SIDE (LT)		TOTAL		SAFE PERCENTAGE
	N	%	N	%	N	%	
49%	-	-	-	-	-	-	-
50-59%	5	5	11	11	16	8	8% (N.S)
60-69%	39	41	58*	56	97	48.5	87% (S)
70-79%	47**	49	30	29	77	38.5	
80-89%	5	5	5	5	10	5	5% (N.S)
≥90%	-	-	-	-	-	-	-
TOTAL	96	100%	104	100%	200	100%	

*Note: Side with the asterisk is significantly greater than the other; at * $P < 0.05$, ** $P < 0.01$. N.S, Not Safe; S, Safe*

Table 3: Pearson’s correlations analysis

Geometric measurements	Maximum glenoid height (MGH)				Maximum glenoid weight (MGW)			
	r	R ²	P-value	Inference	r	R ²	P-value	Inference
Superior angle (SSA)	-0.192	0.037	0.011	Sig	-0.184	0.034	0.015	Sig
Inferior angle (ISA)	-0.146	0.021	0.056	Not Sig	-0.146	0.018	0.056	Not Sig
Spinovertebral angle (SVA)	0.067	0.005	0.380	Not Sig	0.121	0.015	0.111	Not Sig
Maximum scapular height (MSH)	0.518	0.268	<0.001	Sig	0.485	0.235	<0.001	Sig
Maximum glenoid width (MGW)	0.785	0.617	<0.001	Sig	-	-	-	-

Note: r = Pearson’s correlation coefficient; R² = Coefficients of determination

Regression formula for estimation of MGH and MGW

Predictor 1 (SSA)

- I. $MGH(mm) = 46.127 - 0.0985 SSA (^\circ)$
($R^2 = 0.037$)
- II. $MGW(mm) = 33.261 - 0.0863 SSA (^\circ)$
($R^2 = 0.034$)

Predictor 2 (MSH)

- I. $MGH(mm) = 15.693 + 0.1472 MSH (mm)$
($R^2 = 0.268$)
- II. $MGW(mm) = 7.004 + 0.1262 MSH (mm)$
($R^2 = 0.235$)

Inter-glenoid dimension prediction

- I. $MGH(mm) = 15.271 + 0.8586 MGW (mm)$
($R^2 = 0.617$)

Discussion

The present study geometrically investigated the scapular with kin interest in the glenoid cavity morphometry in the bid to explain glenohumeral joint (GHJ) stability and predict the glenoid cavity dimensions form some selected scapular measurement.

Asymmetric observation and implication

In the present study, the observed side difference in some morphometric and geometric measurements of the scapula is an indicator of asymmetry; which may proffer anthropometric explanations to the theories of limb/hand preference or dominance. Although various authors such as Steele¹⁹, Cashmore²⁰ and Corballis²¹ have associated limb reference to brain lateralization, Bracciniet al²² and Hopkins²³ explained handedness as an evolutionary trends (transition from quadrupedalism to bipedalism) with a 90% right hand bias. However, some neuroanatomist; Pascual-Leone²⁴, Laughlin and Sejnowski²⁵ and Pascual-Leone et al²⁶ believed that the brain has the capability to adjust (brain plasticity) to the choice of the limb or hand. Form observations in this study, it will not be overambitious to state that the preferred scientific explanation to handedness points at anthropometry. Also, the findings of this present study contradict the suggestion of Buikstra and Ubelaker²⁷; on the assumption of equality of the sides of the scapula in the event that any of the sides is absent.

Glenoid cavity dimension and scapular geometry

The mean glenoid height documented in this study fell within the range (35.1 to 39 mm) reported by Iannotti et al.²⁸, Sharkey et al.²⁹, Checrounet al.³⁰ and Kwon et al.³¹; while other authors reported widths ranging from 23.6 to 28.3 mm^{15,31,32} which still accommodated the mean values observed in this study.

From investigation of the relationship between human anatomical parts, irregularly shaped structures do provide significant estimate for other regular anatomical parts. Therefore it is scientifically greeted to document as much as possible; any significant correlation that exists between these structures. In this study, the best predictor; MSH had a low positive correlation whereas the inter-glenoid correlation (between MGH and MGW) was significantly high. The significant positive correlation suggests that MGW should increase with a proportionate increase in the MGH. Positive correlation between the glenoid cavity dimensions and scapular geometry have been reported by Polgujet al.¹⁷ These relationships are essential for

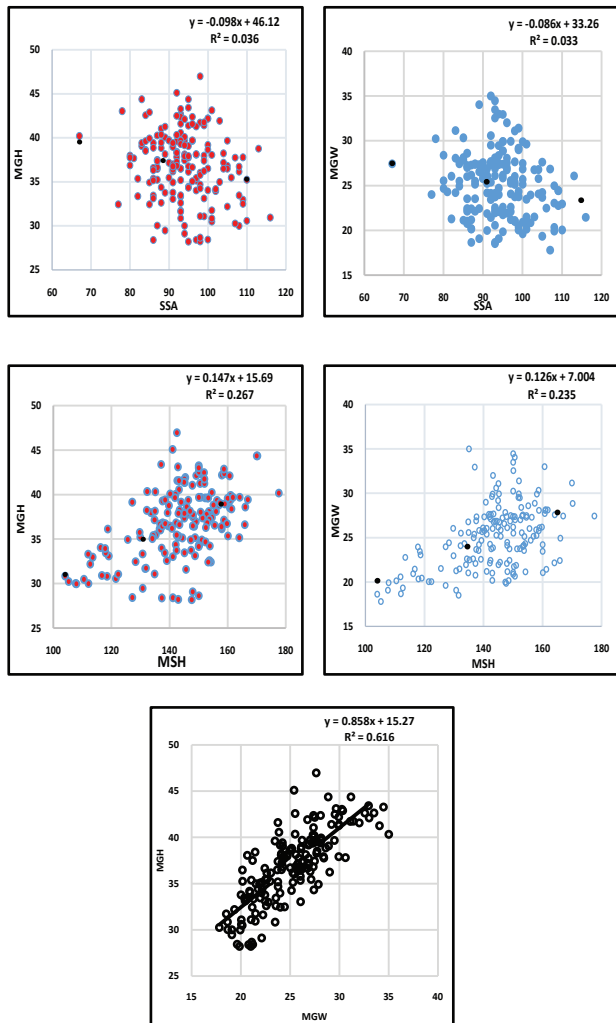


Figure 3A-E: Scatter plot of the glenoid cavity dimensions and scapula geometric measurements with regression equations. **A**, MGH against SSA; **B**, MGW against SSA; **C**, MGH against MSH; **D**, MGW against MSH; and **E**, MGH against MGW

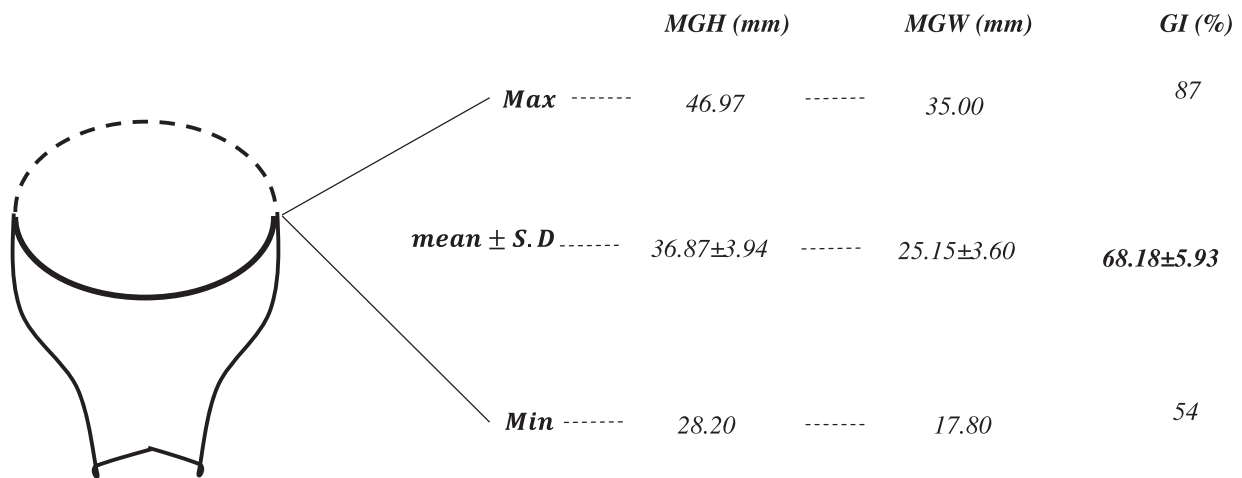


Figure 4: Morphometric description and relationship of the glenoid cavity. **MGH**, Maximum Glenoid Height, **MGW**, Maximum Glenoid Width, **GI**, Glenoid Index.

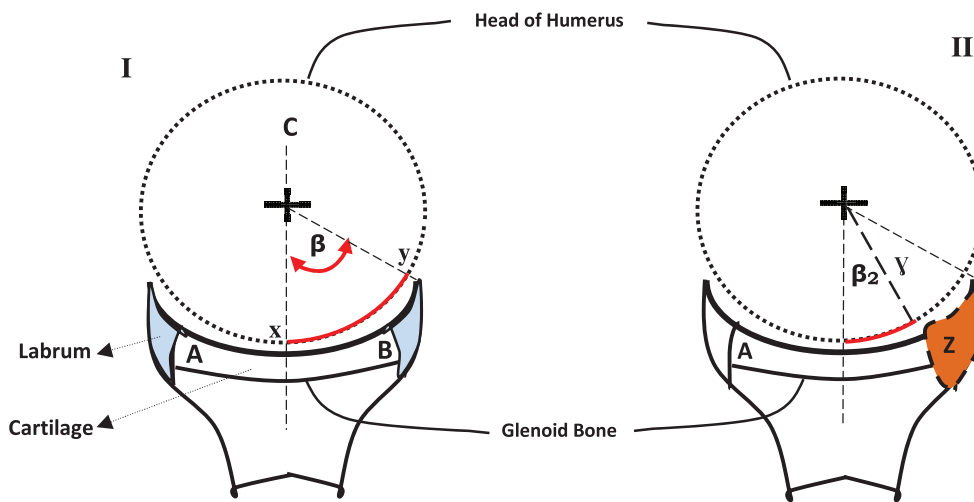


Figure 5: Schematic illustration of glenohumeral morphometry (I) β Balance Stability Angle; C, Glenoid Center line; line xy, Effective Glenoid Arc; line AB, Glenoid Width; (II) β_2 Reduced Stability Angle; γ , Lost Angle; Z, Lost portion of glenoid cavity and reduced glenoid arc

part reconstruction and comparison.

Glenoid cavity morphometry and its functional significance

The positive correlation that exists between the MGH and MGW ($R^2=0.617$) is indicative of the structural design for proper fitting of the labrum and maximum placement of the humeral head at its center. The relationship between the glenoid cavity dimension and shape is very crucial in understanding physiologic and pathological luxation of the glenohumeral joint (GHJ). It could be deduced that the higher the difference between the MGH and MGW (that is; $MGH \geq 2.5 \times MGW$) the lower the glenoid index (GI) and the narrower the cavity; thus

a suggestion of possible GHJ problems. GI towards 50% and lower implies a smaller MGW to MGH ratio and the balance arc of glenoid cavity would be distorted and may not properly accommodate the humeral head. On the other hand, G.I towards 80-89% and above is an indication of rounded glenoid cavity which would be a deviation from the oval shaped cavity; consequently altering the upper margin of the cavity which give room for attachment of the long head of the bicep tendon and thus creating susceptibility to upward luxation. Nevertheless, this postulation would take a different toll if the humeral head dimensions correlate highly with the glenoid cavity morphometry; thereby compensating

for the marked index difference. However, one may be careful to also observe that the humeral head is hemispheroidal² in shape and any marked deviation would have been associated with clinical or pathological condition(s).

There is no doubt that the glenoid labrum may enhance glenoid fossa depth to about 50%³³. However, glenohumeral stability is the ability to maintain the humeral head centered in the glenoid fossa and this to a large extent is dependent on the relationship of the glenoid cavity dimensions and not the labrum as often postulated. The labrum (static mechanism) provides only about 10 to 20% of stabilization forces^{34,35} while the dynamic (active) mechanisms compensate for the remaining 80-90%³³. With reference to the schematic illustration in Fig. 5(I), it is assumed that the non-pathological glenoid cavity (MGW) had an initial measurement from point A to B. However, with some clinical conditions and injuries such as; congenital deficiency (glenoid hypoplasia), Bankart defects³⁶ or excessive wear^{37,38}, the balance stability angle decreased with narrowed width (as illustrated in Fig. 5(II)) of the glenoid cavity, resulting to glenoid insufficiency. The glenoid index and correlation is the proportionate relationship that exists between the MGH and MGW; and therefore

very significant in understanding the morphometric role of glenoid cavity in GHJ stability.

Conclusion

This study has successfully documented the possibility of estimating the glenoid cavity dimensions from other geometric measurement of the scapular. It has also postulated that the glenoid cavity stability is to a reasonable extent associated with the relationship between glenoid cavity dimensions (glenoid index) than to the labrum. Indices below 50% and above 89% are indications of possible GHJ luxation.

Recommendation

This study strongly recommends further investigations be carried out in other populations with the inclusion of 3-D morphometric relationship between the humeral head and the glenoid cavity dimensions. This will broaden the knowledge of GHJ stability from an anthropometric perspective.

Acknowledgement

The authors wish to acknowledge the following universities: Madonna University, Niger Delta University (NDU), NnamdiAzikiwe University, University of Uyo (UNIUYO), and University of Benin (UNIBEN), for their cooperation and provision of the bone models used in this study.

References

1. Moore KL, Dalley AF, and Agur AMR. Moore's Clinical Anatomy. United States of America: Lippincott Williams & Wilkins 2010; Pp 843-980.
2. Gray H. Anatomy, Descriptive and Surgical. 15th ed. T. Pickering Pick and Robert Howden, Eds. New York: Bounty Books, 1977.
3. UW Medicine. Mechanics of glenohumeral instability. The University of Washington Department of Orthopaedics and Sports Medicine 2013. Available at <http://www.orthop.washington.edu/?q=patient-care/articles/shoulder/mechanics-of-glenohumeral-instability.html>. Accessed; 23 July, 2015.
4. Graves WW. The Types of Scapulae. A Comparative Study of Some Correlated Characteristics in Human Scapulae. *Am J Phys Anthropol* 1921; 4: 111-128.
5. Howell S, Galiant B. The glenoid - Labral socket; a constraint articular face. *Clin. Orthop* 1989; 243: 122-125.
6. Poppen NK, Walker PS. Normal and abnormal motion of the shoulder. *J Bone Joint Surg Am* 1976; 58(2): 195-201.
7. Luime JJ, Verhagen AP, Miedema HS, Kuiper JI, Burdorf A, Verhaar JA, Koes BW. Does this patient have an instability of the shoulder or a labrum lesion? *JAMA* 2004; 292(16): 1989-1999.

8. Zumstein V, Kraljević M, Hoechel S, Conzen A, Nowakowski AM, Müller-Gerbl M. The glenohumeral joint - a mismatching system? A morphological analysis of the cartilaginous and osseous curvature of the humeral head and the glenoid cavity. *J OrthopSurg Res* 2014; 9: 34.
9. Solanki BS. The Angles of Scapula. *J AnatSoc India* 1979; 28(1):16-21.
10. Campobasso CP, Di Vella G, Introna (Jr.) F. Using Scapular Measurements in Regression Formulae for the Estimation of Stature. *Boll Soc Ital BiolSper* 1998; 74(7-8):75-82.
11. Lehtinen JT, Tingart MJ, Apreleva M, Warner JJP. Quantitative Morphology of the Scapula: Normal Variation of the Superomedial Scapular Angle, and Superior and Inferior Pole Thickness. *Orthopedics* 2005; 28(5):481-86.
12. Sharma, R., Singla, R.K, Kullar, J.S., Sharma, R., and Sharma, T. (2013). A Cadaveric Study of Different Angles of Scapula and their Role in Kinesiometrics and Muscle Morphology. *Journal of Nepal Medical Association*; 52(191):494-9.
13. Sangam MR, and Devi, SS. Morphometry of Suprascapular Notch and its Correlation with that of Scapula. *J ClinDiagn Res* 2014; 8(4): AM01–02.
14. Kreierhoff, L Knuckle-walking signatures in hominoid scapulae (An MSc thesis). Kent State University, 2014.
15. Mallon WJ, Brown HR, Vogler (III) JB, Martinez S. Radiographic and geometric anatomy of the scapula. *ClinOrthopRelat Res* 1992; 277: 142-54.
16. McPherson EJ, Friedman RJ, An YH, Chokesi R, Dooley RL. Anthropometric study of normal glenohumeral relationships. *J Shoulder Elbow Surg* 1997; 6 (2): 105-112.
17. Polguj M, Jędrzejewski KS, Podgórski M, Topol M. Correlation between morphometry of the suprascapular notch and anthropometric measurements of the scapula. *Folia Morphologica*2013; 70(2): 109–115.
18. Oladipo GS, Aigbogun EO Jr., and Akani GL. Angle at the Medial Border: The Spinovertebra Angle and Its Significance. *Anat Res Int*2015; 2015: 986029.
19. Cashmore L. Can hominid handedness be accurately assessed? *Ann Hum Biol* 2009; 36: 624-641.
20. Corballis MC Human Laterality. London: Academic Press, 1983.
21. Steele J, Mays S. Handedness and directional asymmetry in the long bones of the human upper limb. *Int J Osteoarchaeol* 1995; 5: 39-49.
22. Braccini S, Lambeth S, Schapiro S, Fitch WT. Bipedal tool use strengthens chimpanzee hand preferences. *J Hum Evol* 2010; 58: 234-241.
23. Hopkins WD, Phillips KA, Bania A, Calcutt SE, Gardner M, Russell J, Schapiro SJ. Hand preferences for coordinated bimanual actions in 777 Great Apes: Implications for the evolution of handedness in Hominins. *J Hum Evol* 2011; 60(5): 605–611.
24. Pascual-Leone A. Reorganization of cortical motor outputs in the acquisition of new motor skills. In *Recent Advances in Clinical Neurophysiology*, ed. J Kinura, H Shibasaki, Amsterdam: Elsevier Sci. 1996; 304–8.
25. Laughlin SB, Sejnowski TJ. Communication in neuronal networks. *Science* 2003; 301:1870-73.
26. Pascual-Leone A, Amedi A, Fregni F, and Merabet LB. The plastic human brain cortex. *Annu Rev Neurosci* 2005; 28: 377-401.
27. Buikstra JE, Ubelaker DH. Standards for Data Collection From Human Skeletal Remains. *Arkansas Archaeological Survey Research Series* 1994; No. 44.
28. Chercroun AJ, Hawkins C, Kummer FJ, Zuckerman, JD. Fit of current glenoid component designs: an anatomic cadaver study. *J Shoulder Elbow Surg*2002; 11(6): 614–7.
29. Iannotti JP, Gabriel JP, Schneck SL, Evans BG and Misra, S. The normal glenohumeral relationships. An anatomical study of one hundred and forty shoulders. *J Bone Joint Surg Am* 1992; 74(4): 491–500.
30. Sharkey NA, Marder RA. The rotator cuff opposes superior translation of the humeral head. *Am J Sports Med* 1995; 23(3): 270–5.
31. Kwon YW, Powell KA, Yum JK, Brems JJ, and Iannotti JP. Use of three-dimensional computed tomography for the analysis of the glenoid anatomy. *J Shoulder Elbow Surg* 2005; 14(1):85–90.
32. Churchill RS, Brems JJ, Kotschi H. Glenoid size, inclination, and version: an anatomic study. *J Shoulder Elbow Surg* 2001; 10(4):327–32.
33. Armfield DA, Stickle RL, Robertson DD, Towers JD, Debski RE. Biomechanical basis of common shoulder problems. *Seminars in musculoskeletal radiology* 2013; 7(1): 5-18.
34. Halder AM, Kuhl SG, Zobitz ME, Larson D, An KN. Effects of the glenoid labrum and glenohumeral abduction on stability of the shoulder joint through concavity-compression: an in vitro study. *J Bone Joint Surg Am* 2001; 83-A(7): 1062-9.
35. Lippitt S, Matsen F. Mechanisms of glenohumeral joint stability. *ClinOrthop* 1993; 291:20–28.
36. Bankart A. Recurrent or habitual dislocation of the shoulder-joint. *Bri Med J* 1923; 2(3285): 1132-3.
37. Altchek DW, Warren RF, Skyhar JM, Ortiz G. T-Plasty modification of the Bankart procedure for multidirectional instability of the anterior and inferior type. *J Bone Joint Surg Am* 1991; 73(10): 105-112.
38. Cooper RA, Brems JJ. The inferior capsular-shift procedure for multidirectional instability of the shoulder. *J Bone Joint Surg Am*. 1992; 72(10): 1516-1521.