

Original article

A retrospective clinico-pathological study of hysterectomy cases in a tertiary care hospital in India – a review of 950 cases.

Subrata P¹, Srabani C², Anuradha S³, Prakash PJ⁴, Kingshuk B⁵, Mrinal S⁶

Abstract:

Introduction: Hysterectomy is the most commonly performed gynaecological surgery in India as well as in abroad. It is frequently done in myometrial and endometrial pathologies and rarely for other causes. Hysterectomy is definitive management for diseases like fibroid, adenomyosis, dysfunctional bleeding, prolapsed uterus and malignant lesions of uterus and adenexa. We aimed our study to observe incidence of different pathologies of uterus and other reproductive organs in hysterectomy specimens and retrospective correlation between clinical diagnosis and histopathological finding of hysterectomy cases. **Materials and Methods:** Retrospective data were collected from our routine histopathological laboratory. Detailed history, clinical examination and operative findings and provisional diagnosis of all 950 hysterectomy cases were recorded during study period of 2 years. Histopathological diagnosis was correlated with clinical and preoperative diagnosis. **Observations:** Abdominal hysterectomy (734 cases, 77.26%) was the most common route of approach during surgery. Common pre-operative diagnoses were fibroid uterus (32%), dysfunctional uterine bleeding (28.95%), uterine prolapsed (22.74%). Other causes included uterine polyps (1.6%), complications of pregnancy (2.74%), ovarian tumours (8.42%), cervical carcinomas (2.97%) etc. Common pathologies on histology were leiomyoma (32%), adenomyosis (20.32%), atrophic endometrium (17.26%) and endometrial pathology (8.95%). **Discussion:** Our study has been correlated with other studies of India and other south Asian countries. Most common indication of hysterectomy in our study is dysfunctional uterine bleeding (32%) but Gupta et al and Jha R et al found utero-vaginal prolapse as most common indication. Leiomyoma was the most common histology diagnosed in the present series. Clinical diagnosis was possible in 67.57% cases in our study similar to Khan et al (70.51%). **Conclusions:** Histopathological examination of hysterectomy specimens helps to detect the exact causes and underlined pathology.

Keywords: Hysterectomy; uterine pathology; endometrium.

DOI: <http://dx.doi.org/10.3329/bjms.v17i1.35287>

Bangladesh Journal of Medical Science Vol. 17 No. 01 January'18. Page : 88-92

Introduction:

Hysterectomy is most common gynaecological operation in India and also in the world¹. Charles Clay performed first subtotal hysterectomy in 1843 and first total hysterectomy in 1929 in England^{1,2}. Hysterectomies are done for definitive treatment of multiple pathologies of female reproductive

organs like fibroids, uterine prolapsed, abnormal uterine bleeding, adenomyosis, endometriosis and malignancy of female reproductive organs³. Other less common indications are endometrial hyperplasia, malignancy of reproductive organs, post partum haemorrhage etc. It is done in two approach- abdominal and vaginal route. Vaginal route is

1. Pal Subrata, Demonstrator, Department of Pathology. College of Medicine and Sagore Dutta Hospital
2. Chakrabarti Srabani. Associate Prof, Dept of Pathology, Calcutta National Medical College
3. Sinha Anuradha, Asst Professor, Dept of Pathology. B S Medical College
4. Phukan Jyoti Prakash, Assistant Professor, Dept of Pathology.
5. Bose Kingshuk, Assistant Professor, Dept of Pathology. BS Medical College
6. Sikder Mrinal, Post graduate trainee, Culcutta National Medical College.

Department and institution: Dept of Pathology, Bankura Sammilani Medical College

Correspondence to: Dr Subrata Pal, Demonstrator, Department of Pathology. College of Medicine and Sagore Dutta Hospital, address: Gobindanagar, PO- Kenduadihi, Bankura, West Bengal. PIN- 722102, E-mail address: subratapal1985@gmail.com

preferred in prolapsed uterus. Abdominal route is used in pathology of endomyometrium and other reproductive organs. It may or may not be associated with unilateral or bilateral salpingo-oophorectomy.

Materials and Methods:

This retrospective study was conducted in department of Pathology, Bankura Sammilani Medical College, Bankura over a period of two years from January, 2011 to December 2012. Ethical clearance was obtained from institutional ethical committee. All the hysterectomy specimens sent to our department during this study period, included in the study as sample. Clinical data about age, reproductive status, history, clinical diagnosis, type of surgical intervention was recorded retrospectively. All the specimens were fixed in 10% formalin and tissue sections were taken for processing and paraffin block preparation. The paraffin blocks were sectioned and stained by H & E stain. Microscopical examination was performed for histopathological diagnosis. Histopathological diagnosis were analysed and compared with clinical diagnosis.

Results:

We have studied 950 hysterectomy cases in our study period of two years (Jan 2011- Dec 2012). Among 950 cases 734 cases (77.26%) were undergone abdominal hysterectomy and vaginal hysterectomy were done in 216 cases (22.74%). Laparoscopic method has been used in 64 cases (6.74%). 26 cases were subtotal hysterectomy and all were either at peripartum or postpartum period. Total abdominal hysterectomy without oophorectomy was done in 267 cases (28.10%). Unilateral oophorectomy was associated in 186 cases (19.58%). Total abdominal hysterectomy with bilateral salpingo-oophorectomy was done in 255 cases (26.84%). Distribution of cases according to the type of operation has been shown in table no1.

Table1: Distribution of cases according to type of hysterectomy performed

Type of hysterectomy	No of Cases	Percentage
Subtotal hysterectomy	26	2.73%
Total abdominal hysterectomy (TAH)	267	28.10%
Total abdominal hysterectomy with unilateral salpingo-oophorectomy (TAH+USO)	186	19.58%

Total abdominal hysterectomy with bilateral salpingo-oophorectomy (TAH + BSO)	255	26.84%
Vaginal hysterectomy	216	22.74%

We have encountered patients of wide age range varying from 19 years (lowest age) to 74 years (highest age). Average age of hysterectomy patients in our study is 45.78 years. Highest percentage of patients is among 40-49 years (48.31%). Age distribution of patients in our study has been elaborated in Figure1.

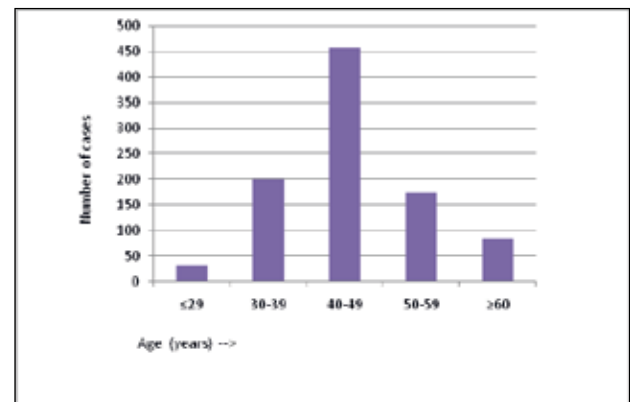


Figure 1: Bar diagram shows the age distribution of hysterectomy cases.

Most common pre-operative clinical indication of hysterectomy in our study was fibroid uterus in 304cases (32%). Dysfunctional uterine bleeding was diagnosed in 275 cases (28.95%) and prolapsed uterus was the indication of hysterectomy in 216 cases (22.74%). All the 26 subtotal hysterectomy (2.74%) were done due to complications of pregnancy such as post partum haemorrhage, ruptured uterus and adherent placenta. Clinical diagnosis of polyp was encountered in 16 cases (1.6%). Ovarian tumor was the indication of hysterectomy in 80 patients (8.42%). Clinical diagnosis of cervical carcinoma was done in 28 cases (2.95%). Other rare indications like chronic pelvic pain and malignancy of non-gynaecological malignancy were found in three (0.31%) and two (0.21%) cases consecutively. Pre operative clinical diagnosis has been shown in table no2.

Table2: Pre-operative clinical diagnosis of hysterectomy cases.

Preoperative clinical diagnosis	No of cases	Percentage
Fibroid uterus	304	32%
Abnormal uterine bleeding	275	28.95%

Uterine prolapse	216	22.74%
Uterine polyp	16	1.6%
Complications of pregnancy	26	2.74%
Ovarian cysts and tumors	80	8.42%
Cervical carcinoma	28	2.95%
Chronic pelvic pain	3	0.31%
Malignancy of other non-genital organ	2	0.21%

In histopathological diagnosis leiomyoma was the most common pathology identified comprising of 304 cases (32%). Adenomyosis was encountered in 193 cases (20.32%). Histological evidence of atrophic uterus was found in 164 cases (17.26%). Most of the prolapsed uterus had atrophic endometrium and hyperkeratinisation of cervical squamous epithelium. But in 54 cases (5.68%) we found normal secretory or proliferative endometrium.

We diagnosed 85 cases (8.95%) of endometrial hyperplasia in our study period. Among this spectrum disordered proliferative endometrium was encountered in 22 cases (25.88%). 48 patients (55.29%) had simple endometrial hyperplasia without atypia. Simple endometrial hyperplasia with atypia was found in 8 cases (9.41%). Among 8 cases of complex endometrial hyperplasia, 6 cases (7.05%) were complex hyperplasia without atypia (Figure 2) and 2 cases (2.35%) were of complex hyperplasia with atypia. Uterine polyps (figure 3) had been diagnosed in 47 cases (4.95%). Leiomyomatous polyp is most common subtype found in 24 cases (51.06% of all uterine polyps). Endometrial polyp was diagnosed in 16 cases (34.04%). 3 cases (6.38%) of adenomatous polyp and 4 cases (8.51%) of cervical polyp were diagnosed in histopathological examination.

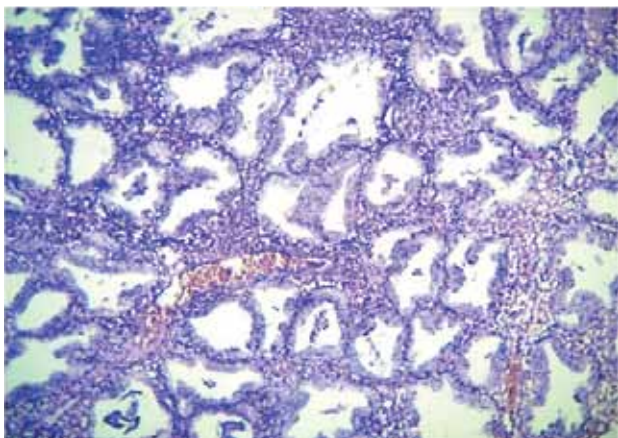


Figure 2: Section shows microscopical image of complex endometrial hyperplasia without atypia in a case of prolonged per vaginal bleeding (H & E stain, 10 X view).

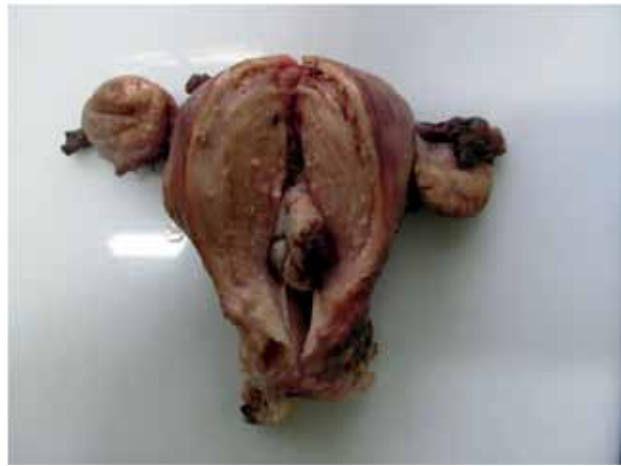

Figure 3: Figures show gross image of a cut open of uterus showing endometrial polyp inside.

In our study 26 cases of peripartum or postpartum hysterectomy were listed. 16 cases were clinically diagnosed as postpartum haemorrhage due to atonic uterus. In histology all the cases show decidual change of endometrium and myometrial hyperplasia. Four cases of ruptured uterus were diagnosed clinically and also proved in gross and microscopy. Adherent placenta was found in 6 cases among which 3 cases were diagnosed as placenta accreta, 2 cases were placenta increta (figure 4) and one case was placenta percreta.

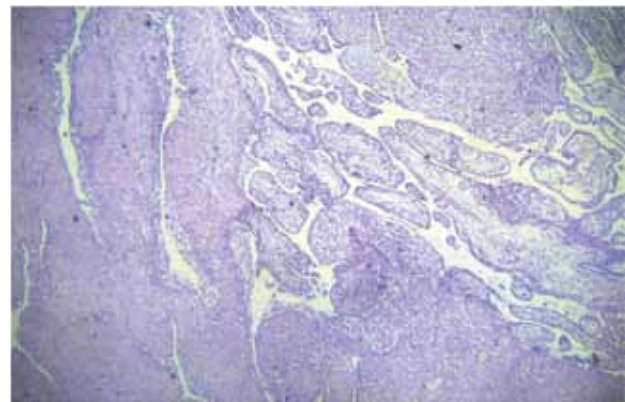


Figure 4: Sections show placental invasion into myometrium in a case of placenta increta (H & E stain, 10 X view).

We diagnosed only 13 cases (1.37%) of malignant lesions in uterine corpus in this study. Among these 11 cases (84.61%) were primary uterine lesions and two secondary involvement were noted, one from serous adenocarcinoma of ovary and another by squamous cell carcinoma of cervix. Of 11 primary malignant lesions of corpus, 6 cases (46.16%) were endometrial carcinoma, two were gestational choriocarcinoma (15.38%) and leiomyosarcoma, carcinosarcoma, and adenosarcoma were comprised one case each. 80 cases of diagnosed ovarian tumour were undergone

hysterectomy with salpingo-oophorectomy. Histopathological examination revealed 50 cases were benign lesions (62.5%). 26 cases (32.5%) were malignant ovarian tumours and 4 cases (5%) were diagnosed as borderline ovarian tumours.

Among 28 cases (2.95%) of cervical carcinoma most common was squamous cell carcinoma (25cases) and three cases (10.71%) were of adenocarcinoma. Endometritis was diagnosed in 7 cases (0.74%) and granulomatous endometritis (tubercular) was reported in one case.

Endometritis was diagnosed in 7 cases (0.74%). One case of granulomatous endometritis of tubercular origin was diagnosed. Endometriosis was found in 3 cases (0.31%). Two cases of ovarian and one case of tubal endometriosis were diagnosed. In 56 cases (5.89%) combined pathology were detected. Leiomyoma with adenomyosis is most common type encountered in 32 cases (3.36%).

All histopathological findings were correlated with clinical diagnosis. Among 304 histopathologically proven leiomyoma clinical diagnosis was possible in 275cases (90.46%). Other 29 cases (9.54%) were clinically diagnosed as DUB. All cases of clinically diagnosed prolapsed uterus, carcinoma cervix and hysterectomy of gestational causes are concordant with histopathological findings. Among 47 cases of uterine polyp (figure3), only 16 cases (34%) were clinically diagnosed. Rest 31 cases were presented as DUB (66%). All isolated cases of adenomyosis, endometrial hyperplasia, endometritis, and endometrial carcinoma were presented with abnormal uterine bleeding. Among 80 cases of ovarian tumour, 4 clinically diagnosed benign ovarian tumours appear as borderline lesion and two clinically malignant solid ovarian mass proved benign in histopathology.

Table3: Histopathological diagnosis of hysterectomy cases

Histopathological diagnosis	Cases	Percentage
Leiomyoma	304	32%
Adenomyosis	193	20.32%
Atrophic endometrium	164	17.26%
Endometrial hyperplasia	85	8.95%
Endometrial polyp	47	4.95%
Endometritis	7	0.74%
Uterine malignancy	13	1.37%
Gestational uterus	26	2.74%
Ovarian tumor	80	8.42%
Cervical carcinoma	28	2.95%
Endometriosis	3	0.31%
Normal uterine histology	54	5.68%

Discussion:

Hysterectomy is most common gynaecological surgery in India as well as in world². Hysterectomy can be either done through abdominal route or through vaginal route. Laparoscopic approach is also being used progressively in recent times. Abdominal hysterectomy is still favoured all over the world due to training habits, practice and performance of gynaecologist². Abdominal hysterectomy leads to longer hospital stay and also have greater complication rate. Vaginal hysterectomy commonly done in prolapsed uterus and pathology where weight of the uterus is less than 280gm⁴. Abdominal route is favourable in large fibroid, bulky uterus, suspected malignancy, emergency hysterectomy for obstetric reason. In the present study, vaginal route have been used in 216 cases (22.74%) where in previous study by Charyssiopoulos et al and Abdullah et al it were 13.4% and 14.67% respectively^{5,6}. Large trials showed that hysterectomy is definitive management for diseases like fibroid, adenomyosis, DUB, prolapsed uterus and malignant lesions of uterus and adenexa^{3,7}. Mean age of patients in our study was 45.78 years, similar to study by Ranabhat et al (45.6years)¹ and Gupta et al (45.6 years)². Most common clinical indication of hysterectomy in our study is dysfunctional uterine bleeding (32%) but in study by Gupta et al and Jha R et al it was utero-vaginal prolapse^{2,10}. Khan et al and Khaniki et al reported fibroid was most common indication in their study^{8,11}. Abdullah et al reported previous or present malignancy as most common clinical indication of hysterectomy in his study⁵.

Most common lesion in our study is leiomyoma, accounting 32% of all cases in histopathology. Our finding correlates with Gupta et al², Khan et al⁸, Qamar-Ur-Nisa et al⁹ and Khaniki et al¹¹. Adenomyosis is diagnosed in 193 cases (20.32%). In other series in India it was reported 24.20% by Gupta et al². In Nepal it is 28%, reported by Ramabhat et al¹. In Italy, Verecillini et al reported adenomyosis in 24.9% and in West Indies Raju et al reported it in 16% of hysterectomy cases¹². Endometrial hyperplasia was diagnosed in 8.95% cases in this study where Nisa et al reported 6.9% in Pakistan, Khaniki et al reported 2.3% in Iran and Ranabhat et al reported 16% in Nepal^{1,9,11}.

Ovarian tumours were encountered in 8.42% of hysterectomy cases in our study. Most of lesions are benign (62.5%) like in other studies by Ranabhat et al (53.3%)¹. In one case we got metastasis of ovarian serous adenocarcinoma into the endometrium which

suggests hysterectomy should be included in surgery for ovarian malignancy whenever possible. But in nulliparous patients of ovarian malignancy of early stage, surgeons always try to preserve uterus and contra-lateral ovary. Malignancy of uterine corpus has been encountered in 1.37% hysterectomy cases. In other studies, it was 1.8% in Nepal by Ranabhat et al, 0.6% in Pakistan by Nisa et al, 7.3% in Iran by Khaniki et al^{1,9,11}. In 54 cases (5.68%) endometrium and myometrium show normal histology. This finding could be explained by prolapsed uterus in reproductive age where endometrium shows normal physiological changes. In prolapsed uterus cervix usually show hyperkeratosis and squamous hyperplasia.

Pre-operative clinical diagnosis always may not be possible because in many cases histopathological examination of endometrium is the key for pathological evaluation. Clinical examination and

radiological evaluation may diagnose fibroid uterus, polyps, prolapsed uterus, cervical and ovarian pathology, pregnancy related complications. But abnormal uterine bleeding due to adenomyosis, endometritis, hyperplasia, early stage malignant uterine lesions are quite difficult to diagnosis clinically. Clinical diagnosis was possible in 67.57% cases in our study. Khan et al showed clinico-pathological concordance in 70.51% cases⁸. Lee NC reported 80% of pre-operative diagnosis was confirmed by histopathological examination¹³. After all most of the lesions are benign and only 7.68% are malignant lesions among large number of hysterectomy cases. In other studies by Gupta et al and Ranabhat et al reported 4% and 6% malignant lesions in their study^{2,1}. In other study by Ojeda et al reported malignant lesions were 12.33% in hysterectomy cases.

Conflicting Interest: None

References:

1. Ranabhat SK, Shrestha R2, Tiwari M, Sinha DP, Subedee LR. A retrospective histopathological study of hysterectomy with or without salpingoophorectomy specimens. *www.cmc.edu.np*,24-29.
2. G. Gupta, D.S. Kotasthane, V.D. Kotasthane: Hysterectomy: A Clinico-Pathological Correlation Of 500 Cases. *The Internet Jour of Gyneco and Obst* 2010;**14**(1). DOI: 10.5580/141b.
3. Nausheen F, Iqbal J, Bhatti F A et al. Hysterectomy: The patient's perspective. *Annals Gynecol* 2004;**10**:339-41.
4. Kovac Sr. Hysterectomy outcomes in patients with similar indications. *Obstet Gynecol* 2002; **95**:787-93.
5. Layla S Abdullah. Hysterectomy: A clinicopathologic correlation. *Bahrain Medical Bulletin* 2006;**28**(2):1-6.
6. Chryssipoulos A, Loghi SC. Indications and results of total hysterectomy. *Int Surg* 1986;**71**(3):188-94.
7. Donnez O, Jadoul P, Squifet J, Donnez J: A series of 3190 laparoscopic hysterectomies for benign disease from 1990 to 2006: evaluation of complications with vaginal and abdominal procedures. *BJOG* 2008; DOI: 10.1111/j.1471-0528.2008.01966.x.
8. Khan R, Sultana H. How dose histopathology correlate with clinical and operative findings in abdominal hysterectomy? *JAFMC Bangladesh* 2010;2.
9. Qamar-Ur-Nisa, Habibullah, Tanweer A S, Hemlata, Fatima M, Zehra M. Hysterectomies; an audit at a tertiary care hospital. *Prof Med J* 2011;**18**(1):46-50.
10. Jha R, Pant Ad et al. Histopathological analysis of hysterectomy specimens. *J of Nep Med Assoc* 2006;**45**(163):283-90.
11. Mahmoud K, Masha S, Azam M T. Histopathological study of hysterectomy operation in a university clinic in Tehran from 2005 to2009. *Jour of Family and Repro Health* 2011;**5**(2):53-7.
12. Raju GC, Narayan Singh V. Adenomyosis uteri: A study of 416cases. *Aust N Z J Obstet Gynaecol* 1988;**28**(1):72-3.
13. Lee NC, Dicker RC, Rubin G, Oray HW. Confirmation of the pre-operative diagnosis for hysterectomy. *Am J Obstet Gynecol* 1984;**150**(3):283-7.
14. Ojeda VJ. The pathology of hysterectomy specimens. *Z Med J* 1979;**89**(631):169-71.