

Original article:

Handmade endoloop knotting technique without knot pusher for appendicular stump closure in laparoscopic appendectomy- personal experience

Sajid I¹, Malhotra MK², Singh M³, Tabassum S⁴.

Abstract:

Aim: to devise a handmade endoloop knotting technique without the use of knot pusher thereby reducing the overall cost of laparoscopic appendectomy. **Material and methods:** This prospective study was conducted in MMIMSR Ambala from January 2015 to August 2017. All operations were performed by the same surgical team. Mesoappendix was coagulated with bipolar cautery and cut with scissors. Two handmade Meltzer loops were placed on base of appendix and tightened using conventional graspers. **Results:** 53 patients were included in the study. The time spent for preparing and tying one loop was approximately 20-25 seconds. None of the patients had leakage from the appendicular stump. Only one polyglactin suture was used to make three loops. Knot pusher was not used in any of the patients. **Conclusion:** handmade endoloop used in this prospective study for securing appendicular stump using conventional laparoscopic graspers was found to be equally safe and can be easily mastered by any laparoscopic surgeon, which will reduce his dependency upon preformed endoloops making the procedure cost effective.

Keywords: laparoscopy; appendectomy; endoloop

*Bangladesh Journal of Medical Science Vol. 17 No. 02 April'18. Page : 255-257
DOI: <http://dx.doi.org/10.3329/bjms.v17i2.35880>*

Introduction:

Laparoscopic appendectomy offers advantages of being safer with fewer chances of infection, early recovery and minimal scarring. However, a steep learning curve, difficult hand eye coordination, 2 dimensional vision, and limited freedom of movements makes laparoscopic approach challenging. In addition, intra abdominal suturing and knot tying are areas of great concern to a laparoscopic surgeon because of lack of dexterity in the beginning of their career. Knots are the weakest link in the process of suturing and if a knot fails to function accurately, results can be disastrous in the form of massive bleeding, fecal peritonitis, septicemia and even death. Only a few surgeons practice optimal

knot tying technique, majority, however employ the usual square knots which later become untied¹. The fear of unreliable intracorporeal appendicular base suturing technique lead to development of novel techniques of tissue approximation including extracorporeal knots using knot pushers, preformed endoloops, bipolar cautery devices, harmonic scalpels and tissue staplers. These novel techniques are easier to use, save operative times and have lesser learning curve issues^{2,3}.but have added to the overall cost of procedure. Moreover when the appendix is significantly inflamed, these ultra modern devices cannot be relied upon in serving their function. A simple way of lowering costs is preferring a handmade loop instead of an endoloop or stapler and using

1. Sajid Iqbal, Senior Resident, Department of Surgery, MMIMSR, Mullana, Ambala, Haryana, India.
2. Mohinder Kumar Malhotra, , Professor
3. Majhail Singh, Professor
Department of Surgery, MMIMSR, Mullana, Ambala, Haryana, India.
4. Saima Tabassum, Junior Resident, Department of ENT, MMIMSR, Mullana, Ambala, Haryana, India.

Correspondence to: Sajid Iqbal, Senior Resident, Department of Surgery, MMIMSR, Mullana, Ambala, Haryana, India. Email-drsajidms@yahoo.com

conventional laparoscopic instruments to tighten the loop instead of using knot pushers which are not readily available in every hospital in developing countries.

Materials and methods:

This prospective study was conducted in MMIMSR Ambala from January 2015 to August 2017. All operations were performed by the same surgical team. Each patient was given preoperative antibiotics in the form of injcfeoperazone 1gm intravenously. Trocars placed were supraumbilical 10mm, suprapubic 5mm and left lower abdomen 5mm. Operating table was tilted 15 degree Trendelenberg position and tilted 15 degree to the left. Mesoappendix was coagulated with bipolar cautery and cut with scissors. Two handmade loops were placed on base of appendix and tightened. We used handmade Meltzer's knot using 2-0 polyglactin suture. Both the limbs were cut, the long limb kept relatively longer than the short limb for easy identification inside abdomen. The loop was introduced inside abdomen via 5mm port and looped around the appendix near the base [fig 1]. The long limb was held with a grasper introduced via suprapubic port while the knot was pushed gently by a Maryland grasper introduced via left lateral port, with the convex side of Maryland grasper facing the knot [fig 2, 3]. Second loop was placed in a similar manner 2-3 mm distal to first one. A third loop was similarly placed 5mm away from the second and the appendix cut with scissors in between the 2nd and 3rd loop. The specimen was retrieved in a finger glove endobag via suprapubic port. Thorough lavage was given using 500ml – 1 liters of normal saline and a Nasogastric tube drain kept in pelvis via suprapubic port. Ethical approval was obtained from the ethic/research committee of MMIMSR, Mullana, Ambala, Haryana, India

Results:

53 patients were included in the study. 32 (60%) of them were males and 21 (40%) were females. Average age was 30 years, ranging from 18 to 60 years. There was no conversion to open procedure. Mean operating time was 40 mins (30-60 mins). The time spent for preparing and tying one loop was approximately 20-25 seconds. The period of stay in hospital was 1.5 (1–2) days. During the post-operative period, one patient

developed surgical wound infection (1.9%). Two patients had small pelvic collections (3.7%) which were managed conservatively. None of the patients had leakage from the appendicular stump. Only one polyglactin suture was used to make three loops. Knot pusher was not used in any of the patients.

Discussion:

Laparoscopic appendectomy is becoming treatment of choice for acute appendicitis. Although less invasive, this approach entails higher costs of treatment. Many studies have shown that laparoscopic appendectomy costs higher than open appendectomy^{4,5}. The cost of laparoscopic appendectomy is based on the disposable equipment, such as endostaplers, endoloops, and trocars. Some surgeons have tried to decrease the number of ports or other surgical instruments used in the operation to reduce costs⁶. Closure of the stump of the appendix with a stapler is a simple but more expensive method when compared with others⁷. Preformed Endoloops, knot pushers, clips and other tissue approximation techniques are expensive and add additional cost to the laparoscopic procedure. Knot pushers sometimes don't work owing to mismatch between its lumen and the size of knot. Our technique is simple and easier than intracorporeal knot tying. Its time saving and very easy to master by young surgeons newly introduced to laparoscopy. It is cheaper than pre-tied endoloops which cost Rs 1000 each in India. There was no need for a knot pusher in our study, which further decreases the cost of instruments. The technique provided satisfactory results. The absence of any stump blowout or fistula, or any communication between the stump and an abscess favours its use in securing the appendicular stump. The small number of the study population forms the main limitation of this study. The lack of control cases operated on with open appendectomy may also be regarded as a limitation; however, significant cost advantage makes the handmade endoloop tightened with conventional instruments the preferred operative method.

Conclusion:

securing the appendicular stump with handmade endoloop using conventional laparoscopic graspers is safe, cost effective, and easy to master.

Conflict of Interest and source of funds – None

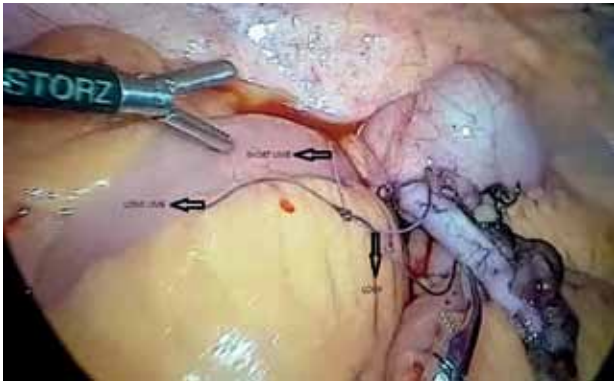


Figure-1 – hand made loop inserted inside abdomen

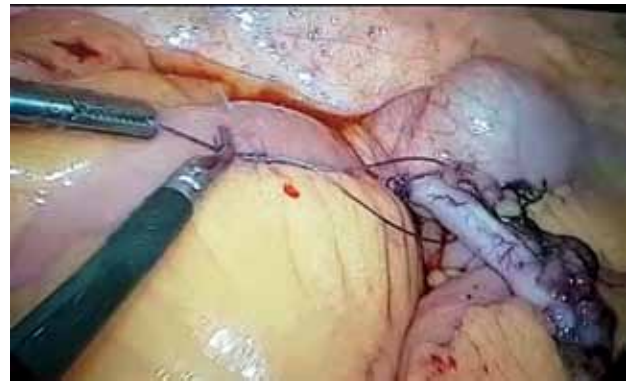


Figure-2 - loop being tightened with conventional grasper and Marylands

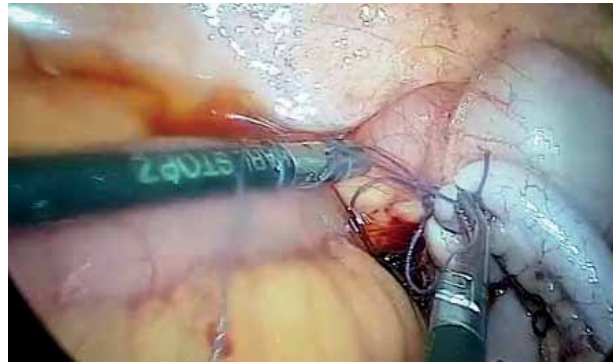


Figure-3 – tightened loop

References

1. Richard F, William B. Long III. Surgical Knot Tying Manual (3rd edition). Norwalk: Covidien, 2008.
2. Ates M, Dirican A, Ince V, Ara C, Isik B, Yilmaz S. Comparison of intracorporeal knot-tying suture (polyglactin) and titanium endoclips in laparoscopic appendiceal stump closure: a prospective randomized study. *Surg Laparosc Endosc Percutan Tech* 2012; **22**(3):226–31.
3. Beldi G, Vorburger SA, Bruegger LE, Kocher T, Inderbitzin D, Candinas D. Analysis of stapling versus endoloops in appendiceal stump closure. *Br J Surg* 2006; **93**(11):1390–3.
4. Fallahzadeh H. Should a laparoscopic appendectomy be done? *Am Surg* 1998; **64**: 231-3.
5. McGrath B, Buckius MT, Grim R, et al. Economics of appendicitis: cost trend analysis of laparoscopic versus open appendectomy from 1998 to 2008. *J Surg Res* 2011; **171**: 161-8.
6. Nguyen NT, Zainabadi K, Mavandadi S, Paya M, Stevens CM, Root J, et al. Trends in utilization and outcomes of laparoscopic versus open appendectomy. *Am J Surg* 2004; **188**: 813-820.
7. Arcovedo R, Barrera H, Reyes HS. Securing the appendiceal stump with the Gea extracorporeal sliding knot during laparoscopic appendectomy is safe and economical. *Surg Endoscop* 2007; **21**: 1764-7.