

Original article:

Correlation of VEGF expression with prognostic factors of breast carcinoma

Dr. Jhuma Nandi¹, Dr. Moumita Maiti², Dr. Neepamanjari Barman³, Dr. Moumita Paul⁴, Dr. Sreepurna Medda⁵, Prof. Sushil Ranjan Ghosal⁶, Prof. Ranu Sarkar⁷

Abstract:

Background: Breast carcinoma is the most common malignant tumour and leading cause of cancer death among women worldwide. VEGF being a powerful mediator of angiogenesis, plays a major role in local growth as well as metastasis of many solid tumours including breast carcinoma. **Objective:** This study aimed to evaluate the significance of VEGF expression in breast cancer and its correlation with prognostic parameters. **Materials and methods:** This study was conducted over a period of one year (February 2015 to January 2016). VEGF expression was evaluated in 57 histologically diagnosed cases of breast carcinoma with known ER and HER-2/neu status. **Result:** Among 57 cases 52(91.2%) were positive for VEGF. Positive ER expression was seen in 39 cases which is 64.8% of total cases. 54% of the total cases were positive for HER-2/neu. VEGF expression was positively correlated (P value <0.05) with tumour grade, tumour size and negatively correlated with ER (p<0.005) and HER-2/neu (p<0.005). Significant correlation also found with tumour type (p<.005). **Conclusion:** Considering the observations of the current study, it can be concluded that VEGF may play a crucial role in the pathogenesis of breast carcinoma and has a positive correlation with biologically aggressive tumour. So consideration of this biomarker (VEGF) is to be regarded as a prognostic parameter and critical evaluator of targeted chemotherapy

Bangladesh Journal of Medical Science Vol. 18 No. 03 July'19. Page : 513-518
DOI: <https://doi.org/10.3329/bjms.v18i3.41619>

Introduction:

Breast cancer is the second most common cancer in the world and by far the most frequent cancer among women with an estimated 1.67 million new cancer cases diagnosed in 2012, according to globocan (WHO). Highest number of deaths due to breast carcinoma (70218 women in the year 2012) was reported from India¹. Angiogenesis has been shown to be a critical aspect of tumour growth and metastasis²⁻⁴. The induction of angiogenesis by a tumour is a controlled process, influenced by angiogenic and angiostatic factors which involve a complex interaction between tumour and endothelial

cells⁴⁻⁶. Among the many reported angiogenic factors, vascular endothelial growth factor (VEGF) is the most powerful endothelial cell specific mitogen that plays a key role in the complicated process of angiogenesis. VEGF also known as vascular permeability factor, is a glycoprotein of 32-42 kDa. The VEGF family currently includes six known members: VEGF-A (commonly known as VEGF), VEGF-B, VEGF-C, VEGF-D, VEGF-E and placental growth factor⁷⁻⁹. VEGF activates tyrosine kinase receptors, VEGFR-1 (also referred to as FLT1) and VEGFR-2 (or KDR) located in the endothelium, which leads to stimulation of endothelial migration, proliferation, permeability,

1. Dr. Jhuma Nandi, Junior Resident, Department Of Pathology, NRS Medical College, Kolkata.
2. Dr. Moumita Maiti
3. Dr. Neepamanjari Barman
4. Dr. Moumita Paul
Assistant Professor, Department Of Pathology, NRS Medical College, Kolkata.
5. Dr. Sreepurna Medda, Demonstrator, Department Of Pathology, NRS Medical College, Kolkata.
6. Prof. Sushil Ranjan Ghosal, Professor and Head, Department Of Surgery, NRS Medical College, Kolkata.
7. Prof. Ranu Sarkar, Professor and Head, Department Of Pathology, NRS Medical College, Kolkata.

Correspondence to: Dr. Moumita Maiti, Assistant Professor, Department Of Pathology, NRS Medical College, Kolkata. Address: Rajkumari Apartment, 6 Dr. Meghnad Saha Road, Chhatak, Dum Dum, Kolkata 700074, Email: moumitapath11@gmail.com,

and survival¹⁰. Recent evidence suggests that VEGF not only plays a role in inducing angiogenesis but also promotes the survival of new vessels formed within the tumour¹¹.

A large number of studies conducted all over the world demonstrated that VEGF could be used as an indicator of significant poor outcome in patients of breast carcinoma.[12-14].

Therefore the current study tries to find the expression of VEGF and its correlation with other prognostic parameters of breast carcinoma as a possible explanation for the aggressive behaviour of this tumour.

Materials and Methods:

It was a cross-sectional observational study conducted in the Department of Pathology in collaboration with Department of General Surgery of NRS medical college and hospital, Kolkata over a period of one year from February 2015 to January 2016. Study population included 57 cases of breast carcinoma, subjected to modified radical mastectomy (MRM).

Histopathology: Tissue slices are taken from primary tumours and axillary lymph nodes of properly fixed MRM specimen and processed. Sections (4-5 micron) were stained with routine Hematoxylin-eosin stain for histopathological examination.

Immunohistochemistry: Immunohistochemical stain (VEGF) in the sections (2-3 micron) prepared from the same block following a standard streptavidin-biotin-peroxidase technique. Rabbit monoclonal antibody for VEGF was used.

VEGF scoring: The criteria for positive immunoreaction are granular cytoplasmic positivity. Both intensity and percentage score was done (as shown in respective tables below) and final score was obtained by summation of percentage and intensity score.

Percentage score:

Score	Staining pattern
Score 0	none of the cells revealed positivity for the marker
Score 1	Up to 10% of the tumour cells are stained
Score 2	Up to 25% of the tumour cells are stained positive
Score 3	Up to 50% of tumour cells are stained positive
Score 4	More than 50% of tumour cells are stained positive

Intensity score:

Score	Staining pattern
Score 0	No staining
Score 1	Weak
Score 2	Moderate staining
Score 3	Strong staining

Final score:

Negative	0-1
Weak	2-3
Moderate	4-5
Strong	6-7

Results of ER and HER-2/neu expression were noted from departmental records.

Statistical analysis: All data were analysed with applicable statistical tests using SPSS software and P value <0.05 was considered significant.

Ethical clearance: Prior the submission, the study was approved by the ethics committee of NRS Medical College, Kolkata

Result:

Out of total 57 cases 52 (91.2%) cases showed widespread cytoplasmic VEGF expression (table:1). All cases were female except one male patient. Strong VEGF was noted among the higher percentage (53%) of poorly differentiated (grade 3) breast carcinoma and it was positively correlated (Rho=0.290, p=0.02). Tumour size (Chart: 3) was also well correlated (rho value: 0.375) to immunoexpression of vascular endothelial growth factor with a P value of 0.004. In case of tumour stage (Table: 2), 21.7% of tumours having stage III or more showed strong expression of VEGF, whereas only 9% of the stage II tumours were detected as strongly positive. Though stage of the tumour was positively correlated (rho value: 0.071) with VEGF expression but statistically it was not significant (p>0.05). Expression of ER (chart: 2) and HER-2/neu (Table: 3) showed negative correlation with VEGF which is statistically significant (P value<0.005). Among 57 cases of breast carcinoma, 48 cases were invasive carcinoma of no special type (NOS) which accounted for 84.25% of total case and 18 among them had in situ component as well. Lobular, medullary and mucinous metaplastic type accounted for 7%, 3.5%, 1.75% and 3.5% of total cases respectively. Statistically significant correlation (P value <0.0001, Mann-Whitney test) among histological type of breast carcinoma and vascular endothelial growth factor expression was noted (table no: 1). However, we did not find any statistically significant correlation among axillary lymph node status and age of patient.

Table, Charts & Figures

Table: 1 -Expression of VEGF in different histologicaltype of Breast carcinoma

Histological type of breast carcinoma	VEGF Expression				
	Negative	Weak	Moderate	Strong	Grand Total
Invasive carcinoma , NOS	1	18	2	9	30
Invasive carcinoma NOS+ DCIS	4	5	9		18
Lobular			1		1
Pleomorphic lobular		2			2
Tubulo-lobular			1		1
Invasive carcinoma with medullary features				2	2
Metaplastic			2		2
Mucinous		1			1
Grand total	5	26	15	11	57

NOS: No special type, DCIS: Ductal carcinoma in situ; p value - <0.0001(Mann-Whitney test)

Table No: 2 – Expression of VEGF with stage of Breast carcinoma

Stage of breast carcinoma	VEGF Expression					Test of significance
	Negative	weak	Moderate	Strong	Grand Total	
III or more	4	21	11	10	46	Rho= 0.071 P >0.05
II	1	5	4	1	11	
Grand Total	5	26	15	11	57	

Table: 3 - Expression of VEGF in correlation with HER-2/neu

HER-2/neu	VEGF Expression					Test of significance
	Negative	weak	Moderate	Strong	Grand Total	
Negative		11	12	7	30	Rho- 0.470 P <0.05
Positive	5	15	3	4	27	
Grand Total	5	26	15	11	57	

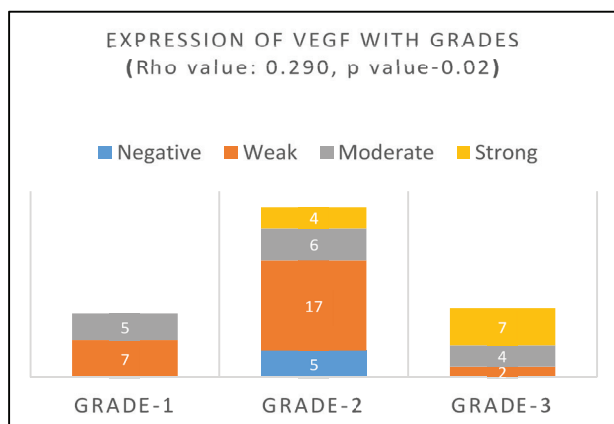


Chart: 1

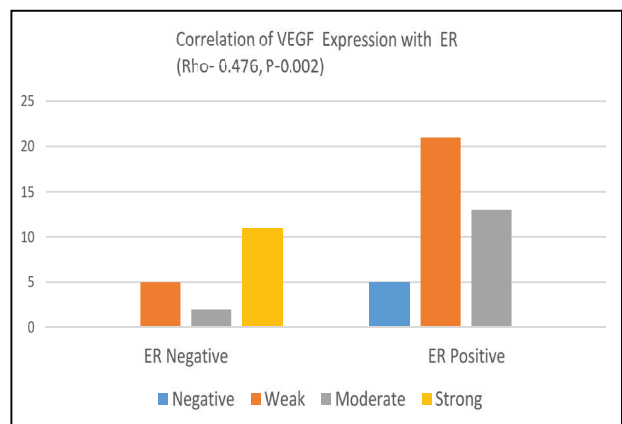


Chart: 2

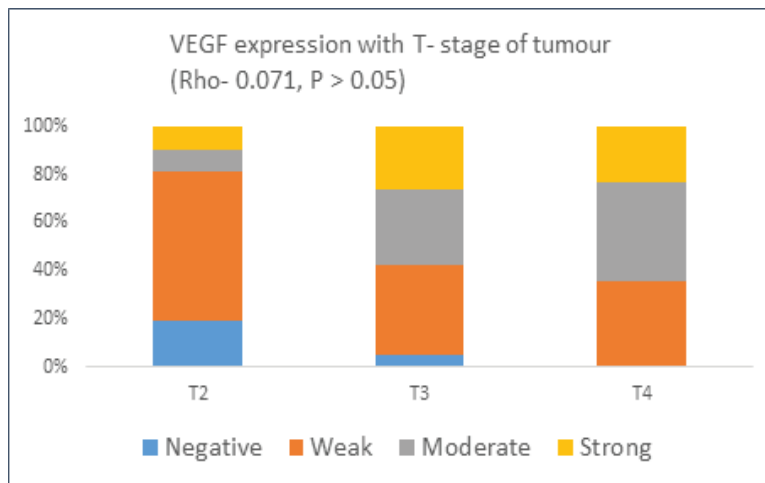
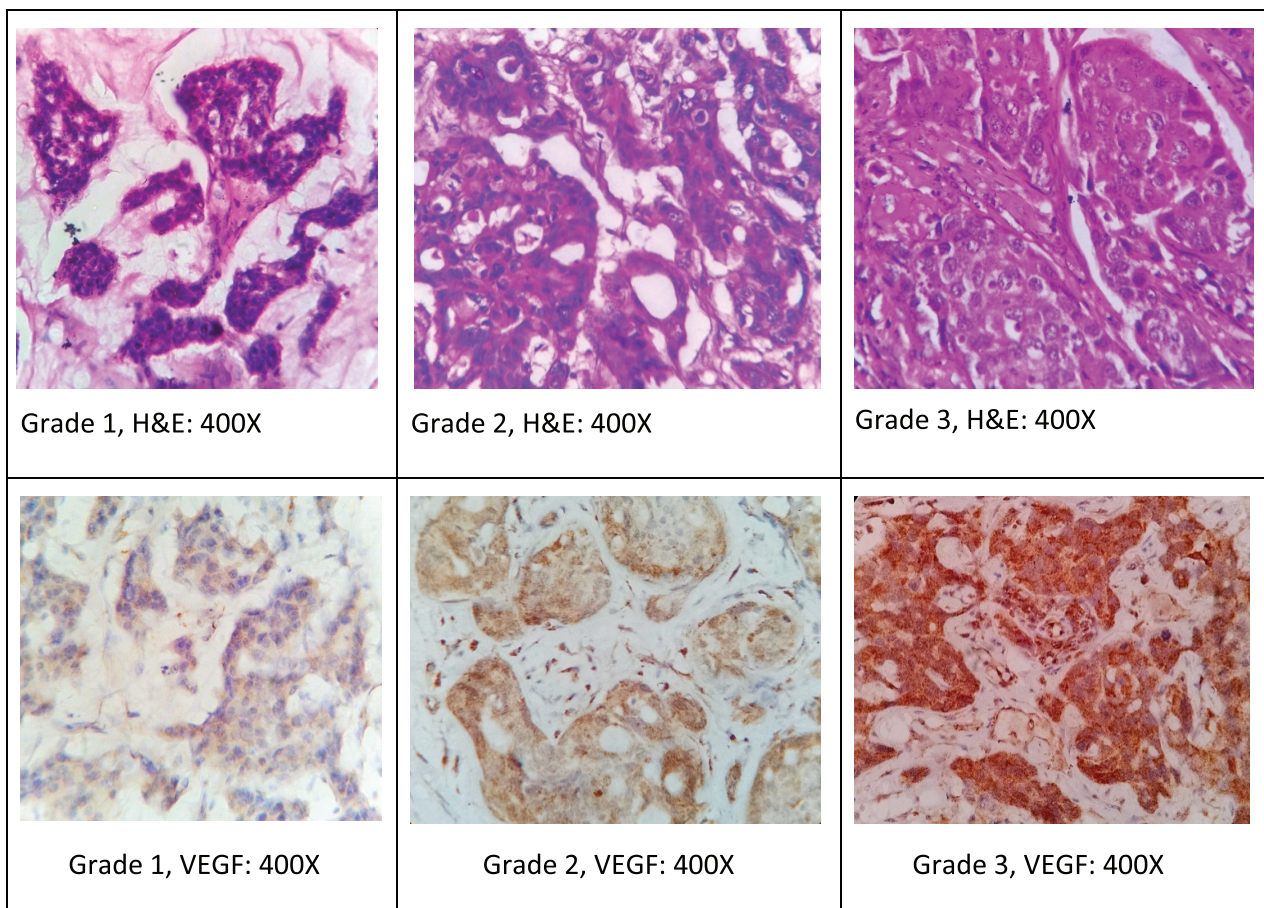


Chart: 3



Figures showing expression of VEGF in different grades of breast carcinoma

Discussion:

Causation of breast carcinoma is multifactorial and angiogenesis has a pivotal role¹⁵. The biology of breast carcinoma remains poorly understood as the knowledge about individual prognostic factors provides limited information¹⁶. In spite of a huge number of studies role of anti VEGF therapy is still debatable in case of breast cancer¹⁷.

In our study VEGF was expressed in 91.2 % of breast carcinoma which was concordant with other previous studies by Vogl G et al (98% VEGF positivity)²⁰, Anca Maria Cimpean et al (87.15%)²¹ and Adams J et al (80%)¹⁸. Whereas studies by Rivkin SE et al. showed very low expression (37%)¹⁹. Presence of significant positive correlation between grade of breast carcinoma (chart: 1) and VEGF

expression has been also shown by other researchers in different studies which explain the role of VEGF gene in tumour angiogenesis and tumour progression^{18,20,22,25}.

From chart no: 3, it has been clearly shown that T-stage of breast carcinoma (tumour size) is positively correlated with VEGF expression (p value : <0.005) and other investigators also found similar result^{20,25}. Adams J et al¹⁸ and Granato AM et al²² has reported that there is a significant negative correlation between VEGF and ER expression (chart no: 2) which is similar with our study findings (rho: -0.470, p-.002). Though many of the researchers^{20, 23} have failed to show any association between angiogenesis and HER2, we have noticed an association of HER2 and angiogenesis like Blackwell KL et al²⁴ and a significant correlation with histological type like Cimpean A M et al²¹.

Conclusion:

From the observations of our study it can be concluded that VEGF has the potential to be considered as an

important prognostic parameter in breast carcinoma. Targeted therapy against it may be beneficial for the patients specially, who are triple negative and have no specific treatment other than chemotherapy. As it was a time bound study of relatively small numbers of cases with limited scope of follow up, a wider evaluation involving large no of cases provided with proper follow up facility is recommended to validate its therapeutic efficacy.

Conflict of interest: None declared

Author's contribution:

Data gathering and idea owner of this study: Nandi J, Maiti M, Barman N,

Study design: : Nandi J, Maiti M, Barman N, Paul M, Medda S, Ghosal SR

Data gathering: Nandi J, Maiti M, Barman N, Paul M, Medda S, Ghosal SR, Sarkar R

Writing and submitting manuscript: Nandi J, Maiti M, Barman N, Paul M, Sarkar R

Editing and approval of final draft: Nandi J, Maiti M, Barman N, Paul M, Medda S, Ghosal SR,

References:

1. Electronic Article available from: http://www.breastcancerindia.net/bc/statistics/stat_global.htm
2. Folkman J, Shing Y. Angiogenesis. *J Biol Chem*, 1992;**267**:10931-34 <http://www.jbc.org/content/267/16/10931.long>
3. Folkman J. What is the evidence that tumors are angiogenesis dependent. *J Natl Cancer Inst*, 1990;**82**:4-6 <https://academic.oup.com/jnci/article/82/1/4/1035101/What-Is-the-Evidence-That-Tumors-Are-Angiogenesis>
4. Folkman J. Clinical application of research on angiogenesis. *N Engl J Med*, 1995;**333**:1757-63
5. Risau W. Mechanisms of angiogenesis. *Nature*, 1997;**386**:671-74
6. Hanahan D, Folkman J. Patterns and emerging mechanisms of the angiogenic switch during tumorigenesis. *Cell*, 1996;**86**:353-64 <http://www.sciencedirect.com/science/article/pii/S0092867400801087>
7. Newfeld G, Cohen T, Gengrinovitch S. Vascular endothelial growth factor (Vegf) and its receptors. *FASEB J*, 1999;**13**:9-22 <https://www.ncbi.nlm.nih.gov/pubmed/9872925>
8. Meyer M, Clauss M, Lepple-Wienhues A. A novel vascular endothelial growth factor encoded by Orf virus, VEGF-E, mediates angiogenesis via signalling through VEGFR-2 (KDR) but not VEGFR-1 (Flt-1) receptor tyrosine kinases. *EMBO J*, 1999;**18**:363-74 <https://www.ncbi.nlm.nih.gov/pmc/articles/PMC1171131/pdf/000363.pdf>

9. Ogawa S, Oku A, Sawano A. A novel vascular endothelial growth factor, VEGF-E (NZ-7 VEGF), preferentially utilises KDR/Flk-1 receptor and carries a potent mitotic activity without heparin-binding domain. *J Biol Chem*, 1998;**273**:31273-82
10. Shibuya M. Structure and function of VEGF/VEGF-receptor system involved in angiogenesis. *Cell Struct Funct*, 2001;**26**:25-35 https://www.jstage.jst.go.jp/article/csf/26/1/26_1_25/pdf
11. Benjamin LE, Keshet E. Conditional switching of vascular growth factor (VEGF) expressions in tumors: induction of endothelial cell shedding and regression of hemangioblastoma-like vessels by VEGF withdrawal. *Proc Natl Acad Sci USA*, 1997;**94**:8761-66.
12. Yen L, You XL and Al Moustafa AE. Heregulin selectively up-regulates vascular endothelial growth factor secretion in cancer cells and stimulates angiogenesis. *Oncogene*, 2000;**19**:3460-69
13. Gasparini G, Toi M, Gion M, Verderio P, Dittadi R, Hanatani M. Prognostic significance of vascular endothelial growth factor protein in node-negative breast carcinoma. *J Natl C Inst*, 1997;**89**:139-47
14. Epstein M, Ayala R and Tchekmedyan N. HER-2/neu-overexpressing human breast cancer xenografts exhibit increased angiogenic potential mediated by vascular endothelial growth factor (VEGF). *Breast Cancer Res Treat*, 2002;**76**(Suppl. 1):S143
15. Yen L, You XL and Al Moustafa AE. Heregulin selectively up-regulates vascular endothelial growth factor secretion in cancer cells and stimulates angiogenesis. *Oncogene*, 2000;**19**:3460-69
16. Sorli, T., Perou, C.M., Tibshirani, R., Aas, T., Geisler, S., Johnsen, H., et al. Gene Expression Patterns of Breast Carcinomas Distinguishes Tumor Subclasses with Clinical Implication. *Proceedings of the National Academy of Sciences of the United States of America*, 2001;**98**:10869-10874 <https://www.ncbi.nlm.nih.gov/pmc/articles/PMC58566/>
17. Miller K, Wang M, Gralow J, Dickler M, Cobleigh M, Perez E A, Shenkier T, Cella D, Davidson N. E. et al., Paclitaxel plus bevacizumab versus paclitaxel alone for metastatic breast cancer, *N Engl J Med*, 2007;**357**(26):155-168.
18. Adams J., Carder P. J., Downey S., Forbes M. A., MacLennan K., Allgar V., Kaufman S., Hallam S., Bicknell R., Walker J. J., Cairnduff F., Selby P. J., Perren T. J., Lansdown M., Banks R. E. et al, Vascular endothelial growth factor (VEGF) in breast cancer: comparison of plasma, serum, and tissue VEGF and microvessel density and effects of tamoxifen, *Cancer Res*, 2000;**60**(11):2898–2905. <https://www.ncbi.nlm.nih.gov/pubmed/10850435>
19. Rivkin S. E., Gown A. M., Malmgren J. A., Tickman R. J., Atwood M., Iriarte D., Vascular endothelial growth factor expression and survival in node positive breast cancer patients treated with adjuvant therapy, *J Clin Oncol*, 2004 ASCO Annual Meeting Proceedings (Post-Meeting Edition), 2004;**22**(14S):653
20. Vogl G, Bartel H, D Otto, K Cornelia et al. HER2 is unlikely to be involved in directly regulating angiogenesis in human breast cancer, *Appl Immunohistochem Mol Morphol* 2006;**14**(2):138-145 http://journals.lww.com/appliedimmunohist/Abstract/2006/06000/HER2_Is_Unlikely_to_Be_Involved_in_Directly.3.aspx
21. Cimpean A M, Raica M, Suciuc C , Tatucu D, Sarb S, Muresan A M et al.(VEGF A) as individual prognostic factor in invasive breast carcinoma, *Romanian journal of Morphology and Embryology*, 2008;**49**(3):303-308 http://www.academia.edu/20792567/Vascular_endothelial_growth_factor_A_VEGF_A_as_individual_prognostic_factor_in_invasive_breast_carcinoma
22. Granato AM, Nanni O, Faicini F, Folli S et al. Basic fibroblast growth factor and vascular endothelial growth factor serum levels in breast cancer patients and healthy women: useful as diagnostic tools? *Breast cancer Res* 2004;**6**:R38-45. <https://www.ncbi.nlm.nih.gov/pmc/articles/PMC314457/>
23. Horak ER, Leek R, Klenk N et al. Angiogenesis, assessed by platelet/ endothelial adhesion bodies, as indicator of node metastasis and survival in breast cancer. *Lancet*. 1992;**340**:1120-1124 <https://www.ncbi.nlm.nih.gov/pubmed/1279332>
24. Blackwell KL, Dewhirst MW, Liotcheva V, et al. HER-2 gene amplification correlates with higher levels of angiogenesis and lower levels of hypoxia in primary breast tumors. *Clin Cancer Res*. 2004;**10**:4083–4088. <http://clincancerres.aacrjournals.org/content/10/12/4083.long>
25. Ali A M, Sheta M, Mohsen M A El et al. Elevated serum and tissue VEGF associated with poor outcome in breast cancer patients, *Alexandria Journal of Medicine*, 2011;**47**:217-224 <http://www.sciencedirect.com/science/article/pii/S2090506811000455>