

**Case report**

**Anterior Urethral Polyp – A Rare Cause of Urethrorrhagia**

Souvik Chatterjee<sup>1</sup>, Pramod Kumar Sharma<sup>2</sup>, Kanishka Samanta<sup>3</sup>, Soumendra Nath Mandal<sup>4</sup>, Dilip Karmakar<sup>5</sup>

**Abstract:**

Urethrorrhagia is a benign self limited condition. Most of the cases of urethrorrhagia are idiopathic. Anterior urethral polyp (AUP) is a rare cause of it. AUP most commonly affect infants. Endoscopic modality is the best way to detect as well as manage the polyps. Fibroepithelial polyps are benign in nature with no propensity of recurrence with complete excision.

**Keywords:** Urethrorrhagia, anterior urethral polyp, fibroepithelial polyp, polypectomy

*Bangladesh Journal of Medical Science Vol. 18 No. 03 July'19. Page : 663-664  
DOI: <https://doi.org/10.3329/bjms.v18i3.41647>*

**Introduction:**

Urethrorrhagia is a benign self-limited clinical condition where urethral bleeding occurs in the absence of passage of urine. The site of bleeding is generally situated within urethra at some point distal to bladder neck. It is presented with blood spots on underwear not in relation to passage of urine in pre-pubertal boys.<sup>1</sup> Among different etiological factors, anterior urethral polyp (AUP) is a rare condition.<sup>2</sup>

**Case:**

A four year old boy was presented to us with repeated episodes of painless blood spotting on his underwear for last 3-4 months. According to his parents, there was no history of fever, burning sensation of micturition, lower urinary tract symptoms, and trauma to the lower urinary tract. The physical examination of external genitalia was unremarkable except blood staining of underwear. Blood examination, urine analysis and culture reports were unremarkable. Ultrasonography of whole abdomen, retrograde urethrogram (RGU), micturating cystourethrogram (MCU) and uroflowmetry study examinations did not reveal any abnormality.

The cystoscopy and panendoscopy (CPE) revealed a sessile pinkish mass measuring 1.5 cm×1 cm,

originated from dorsal surface of distal penile urethra just proximal to fossa navicularis with congested urethral mucosa proximal to the lesion [Figure 1]. He was treated with endoscopic transurethral polypectomy with fulguration of base of the polyp under general anaesthesia. The post operative recovery was uneventful. The histopathological report showed benign fibroepithelial polyp (FEP) of anterior urethra covered with transitional epithelium, with some areas of squamous metaplasia [Figure 2]. The boy remained free of symptoms without any evidence of stricture or recurrence on follow up for next six months.

**Discussion:**

Polyps arising from lower urinary tract are much less frequent than polyps of upper tract.<sup>2</sup> Urethral polyps are rare entity and most of them are benign posterior urethral growths in paediatric male patient. AUP is even rarer.<sup>2</sup>

AUP may be congenital or acquired in origin, whereas polyps of posterior urethra are usually congenital in origin. Mechanical irritation of anterior urethra by repeated transurethral procedure, obstructed urinary flow due to anterior urethral stenosis and recurrence urothelial carcinoma or prostatic malignancy may be the documented causes of AUP in literature.<sup>3-4</sup>

1. Souvik Chatterjee - MBBS, MS General Surgery, DNB General Surgery, MCh Urology Resident
2. Pramod Kumar Sharma - MBBS, MS General Surgery, MCh Urology, DNB Urology
3. Kanishka Samanta - MBBS, MS General Surgery, MCh Urology Resident
4. Soumendra Nath Mandal - MBBS, MS General Surgery, MCh Urology
5. Dilip Karmakar - MBBS, MS General Surgery, MCh Urology

**Correspondence to:** Dr. Souvik Chatterjee, DS 41, Central Government Hostel Complex, 7, Marlin Park, Ballygunge Phari, P.O. Ballygunge, Kolkata – 700019, Ph. No.- +919830455814, +913324601511, E-mail: [dr.souvikchatterjee@gmail.com](mailto:dr.souvikchatterjee@gmail.com), Disclose: Nil, Sources of support: Nil

Infants are most commonly involved, though aged male patients may rarely suffer from AUP.<sup>3-4</sup> Our patient is a four year old boy.

Patients of AUP usually present with dysuria, hesitancy, enuresis, post-void dribbling, and gross hematuria. Urethrorrhagia is an uncommon mode of presentation.<sup>1,2</sup> Along with clinical features, radiological examinations (RGU, MCU, ultrasonography) and direct endoscopic visualization help physician to reach the diagnosis.<sup>5</sup> Urine cytological examination is helpful in AUP of malignant origin.<sup>3-4</sup> In our patient, urethroscopy

helps us to detect as well as treat the cause of urethrorrhagia.

Urethral polyps are usually treated with transurethral resection using electrocautery or laser energy.<sup>2,6</sup> AUP with smooth surface and tense structure are managed by open surgical approach.<sup>5,6</sup> Our patient was treated with endoscopic excision. Histopathological report of excised specimen was FEP.

**Ethical clearance:** This case report was approved by local ethics committee

**Conflict of interest:** None

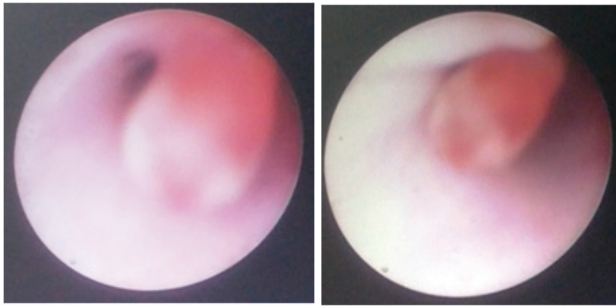


Figure 1: CPE showing anterior urethral polyp

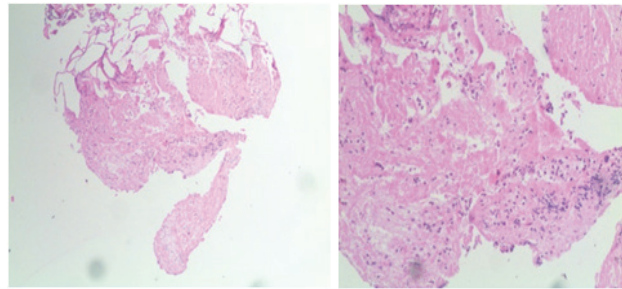


Figure 2: Histopathological report showing FEP

### References:

1. Patrick C. Cartwright. Urethrorrhagia. Pediatric Urology for the Primary Care Physician. *Current Clinical Urology* 07 November 2014; pp 221-224
2. Pal DK, Bag AK. Prolapsing anterior urethral polyp. *Indian J Urol.* 2006;22:142-143 <https://doi.org/10.4103/0970-1591.26571>
3. Ozeki Z, Kawakami S, Masuda H, Ishizaka K, Kegeyama Y, Kihara K. Fibro epithelial polyp of the anterior urethra, found during post-operative follow up of ureteral cancer. *Hinyokika Kyo* 2003;49:29-31.
4. BeikoD,ZazaK,PowerKV,SiemensDR,BoagAH.Isolated anterior urethral recurrence of prostatic adenocarcinoma. *Can Urol Assoc J.* 2014 May;8(5-6):E361-3. <https://doi.org/10.5489/cuaj.1692>
5. Demircan M, Ceran C, Karaman A, Uguralp S, Mizrak B. Urethral polyps in children: a review of the literature and report of two cases. *Int J Urol.* 2006 Jun;13(6):841-3. <https://doi.org/10.1111/j.1442-2042.2006.01420.x>
6. Jain P, Shah H, Parelkar S V, Borwankar S S. Posterior urethral polyps and review of literature. *Indian J Urol;* 2007 Apr-Jun; 23(2): 206-207 <https://doi.org/10.4103/0970-1591.32080>