

Original article:

Mucocutaneous Histoplasmosis in immunocompetent adult patients

Mallika Sengupta¹, Anita Mitra Nandi², Himangsu Roy³, Soma Sarkar⁴, Manideepa Sengupta⁵

Abstract:

Introduction: Histoplasmosis is a fungal infection caused by the agent *Histoplasma capsulatum*, a dimorphic fungus. The spectrum of illness ranges from subclinical infection to progressive disseminated disease. The major bulk of histoplasma infections are asymptomatic or pulmonary histoplasmosis. In immune compromised patients it can cause disseminated infections involving different organs of the body. In immune competent individuals it may cause isolated adrenal histoplasmosis. **Material and methods:** A retrospective study was done to look for mucocutaneous histoplasmosis. The excised tissue samples were cultured and only culture confirmed cases were included in the study. **Result:** Here, we present five cases of primary mucocutaneous histoplasmosis in immune competent individuals in a tertiary care centre in India. These patients had no other co-morbidities and had only isolated lesions in oral cavity or penis. The tissue on excision was cultured and showed growth of *Histoplasma capsulatum*. All the patients improved with treatment. There are limited cases of mucocutaneous ulcerated lesions caused by *Histoplasma capsulatum* in immune competent people in published literature. **Conclusion:** This study emphasizes the necessity of a vigilant look out and clinical suspicion of fungal causes like histoplasma in chronic non healing ulcers which should be confirmed by the laboratory investigations. Accurate diagnosis helps in specific management of these cases.

Keywords: *Histoplasma capsulatum*; ulcer; oral; genital; immunocompetent

Bangladesh Journal of Medical Science Vol. 19 No. 01 January'20. Page : 94-97
DOI: <https://doi.org/10.3329/bjms.v19i1.43878>

Introduction

Histoplasmosis is a fungal disease caused by dimorphic fungi *Histoplasma capsulatum*. Two varieties of fungi are known to infect humans, namely: *H. capsulatum* var. *capsulatum* and *H. capsulatum* var. *Duboisii*¹. Clinical manifestations of histoplasmosis varies from asymptomatic infection, pulmonary histoplasmosis and progressive disseminated disease². The only report of *Histoplasma* being isolated from soil is from the Gangetic plain of West Bengal as early as in 1975³. The first case of histoplasmosis from India was reported in 1954 by Panja and Sen from Calcutta⁴. A number of risk factors can predispose to disseminated histoplasmosis such as AIDS, primary immunodeficiency, long-term

immunosuppression as with use of glucocorticoids and post-organ transplantation². Only few cases of primary mucocutaneous histoplasmosis are reported and even fewer in immunocompetent individuals.

Materials and methods

A retrospective study was done for five and half years (July 2011 to December 2016) to find out the cases of primary mucocutaneous histoplasmosis in a tertiary care hospital in Eastern India. The clinical features and associated diseases were noted. The excised tissue was sent to the Department of Microbiology. Direct microscopy showed presence of yeast cells on Gram stain preparation and potassium hydroxide preparation. Tissue was then inoculated on Sabouraud's dextrose agar and incubated at 37°C and

1. Mallika Sengupta, Assistant Professor, Department of Microbiology, KPC Medical College, Kolkata.
2. Anita Mitra Nandi, Assistant Professor, Department of Microbiology, Medical College, Kolkata.
3. Himangsu Roy, Assistant Professor, Department of Surgery, Medical College, Kolkata.
4. Soma Sarkar, Assistant Professor, Department of Microbiology, Medical College, Kolkata.
5. Manideepa Sengupta, Professor, Department of Microbiology, Medical College, Kolkata.

Correspondence to: Dr. Manideepa Sengupta, Professor, Department of Microbiology, Medical College, Kolkata, Medical College, Kolkata, 88 College Street, Kolkata- 700073.

E-mail: manideepa.sengupta2305@gmail.com

25°C temperature. The growth of the organism was noted and identification was done by lactophenol cotton blue preparation. All the cases included were positive for fungal culture. The samples which had yeast cells on direct microscopy but did not grow in culture were excluded from the study.

Ethical clearance: Prior to the submission, the study was approved by the ethics committee of Medical College, Kolkata.

Results

A retrospective study was done in a tertiary care hospital in Eastern India which revealed five cases

of primary mucocutaneous histoplasmosis during the period of five and half years (2011 – 2016). The age of the patients was between 52 to 71 years (mean = 60.94, SD = 8.35). All the patients were male. All the patients were from rural areas of southern part of West Bengal and farmer by occupation. All these patients were immunocompetent and were negative for HIV test by ELISA, had no history of any medications, transplant etc. None of the patients were diabetic. The patients presented with swelling and ulcer of the affected region. Among these patients four had oral histoplasmosis while one had penile histoplasmosis (Table 1).

Table 1 shows the demographic characteristics and clinical features of the patients

Case	Year	Age	Gender	Clinical features	Tissue from which isolated
Case 1	2011	71	Male	Ulcer in palate	Palate
Case 2	2012	62	Male	Neck swelling	Oropharynx
Case 3	2014	54	Male	Ulcer in mouth	Mouth
Case 4	2015	68	Male	Dysphagia	Larynx
Case 5	2016	52	Male	Ulcer in penis	Penis

The lesion was excised and sent for microscopy and culture. On direct microscopy, it showed yeast cells on Gram stain preparation and potassium hydroxide preparation. It was inoculated on Sabouraud's dextrose agar and brain heart infusion agar and incubated at 37°C and 25°C temperature. The growth of the organism was noted and identification was done by lactophenol cotton blue preparation. The growth from culture at 25°C was white cottony growth (Fig 1). On microscopy septate hyaline hyphae with tuberculate macroconidia and small smooth microconidia, corresponding to the structure of *Histoplasma capsulatum* was seen (fig 2). None of these five cases had any malignant change on histopathology.

The mycelial phase converted to yeast phase on brain heart infusion agar at 37°C confirming the isolate as *Histoplasma capsulatum*. The patients were treated with amphotericin B and improved.

Discussion

Histoplasmosis is a fungal infection, having different names like Cave disease, Darling's disease, Ohio Valley disease, Spelunker's lung and Caver's disease. The aetiological agent is a dimorphic fungus, *Histoplasma capsulatum*, causing chronic granulomatous disease. The spectrum of illness ranges from subclinical infection of the lung to progressive disseminated disease. In immunocompromised

patients it causes disseminated infections with multiple organs involvement⁵.

The first report of oral histoplasmosis was by Joshi *et al*⁶ in 1973 and Sanyal *et al* from West Bengal in the same year⁷. This was followed by case reports by Thammayya in 1979⁸ and Padhye in 1994. Till 1992, there were 25 cases of histoplasmosis in India, of which 19 were confined to oral cavity. A 30 year old patient had presented with ulcer on hard palate which showed *Histoplasma* on both histopathology and culture⁹. Though cutaneous and mucocutaneous histoplasma infections are more commonly associated with HIV infected patients, it may cause disease in immunocompetent people as well as shown by Verma *et al* in 2011 where the immunocompetent patient presented with rhinosinusitis and a non-healing oral ulcer¹⁰.

In many instances oral lesions are associated with cutaneous lesions. Such a case has been reported by Harnalikar and group in a 60 year old HIV negative male who presented with asymptomatic swelling of the hard palate and crusted papules and nodules over the extremities, face and trunk which was diagnosed as histoplasma on culture¹¹. A similar case was reported by Anza and colleagues with linear erythematous atrophic plaques and oral ulcers in a immunocompetent patient¹² and Vidyanath *et al*¹³. However, here we present five cases of

mucocutaneous histoplasmosis of which four had isolated oral ulceration on presentation. The study shows that it is more common in the older age group with a mean age of 60.94 years which is similar to the findings of Deodhar *et al* who saw that the mean age of disseminated histoplasmosis was 52.2 years in immunocompetent patients as compared to much lesser age in immunodeficient individuals². In many studies histoplasmosis is diagnosed based on histology alone¹⁴. But in our study all cases included were culture positive.

In case 4, the patient presented with dysphagia and weight loss. He was diagnosed to have laryngeal histoplasmosis. This was also shown by John *et al*¹⁵ and a 58 year old patient from Madhya Pradesh¹⁶. The differential diagnosis are tuberculosis and malignancy as seen by Ansari and group in a 60 year old patient⁵.

In case 5, the patient presented with a non-healing ulcer on penis for 2 years. Genital histoplasmosis in India has been first reported by Randhawa *et al* from epididymal biopsy in 1995¹⁷. It has also been reported by Chaurasia *et al* in 2007 in a patient with penoscrotal histoplasmosis following bladder carcinoma¹⁸. A case of epididymal and prostatic histoplasmosis was reported from Karnataka State of southern India, in a 37-year-old male renal transplant

recipient¹⁹. Another similar case was seen in a renal transplant recipient whose epididymal biopsy revealed histoplasmosis²⁰. But in our case, the patient was a healthy immunocompetent male patient who had penile histoplasmosis.

Conclusion

Histoplasmosis may have varied clinical manifestations, ranging from oral ulcer, laryngeal histoplasmosis to penile histoplasmosis in immunocompetent individuals. As the disease mimics other diseases like malignancy and tuberculosis, a constant vigilance is required for clinical suspicion and laboratory diagnosis of these unusual presentations so that the causative agent is identified and appropriate management is given to these patients.

Conflict of interest

Authors possess no conflict of interest.

Individual Contribution of the Authors:

Conceptual work: Sengupta M

Data collection: Sengupta M, Nandi AM, Roy H, Sarkar S, Sengupta M

Manuscript writing: Sengupta M

Editing of final manuscript: Sengupta M, Nandi AM, Roy H, Sarkar S, Sengupta M



Fig 1

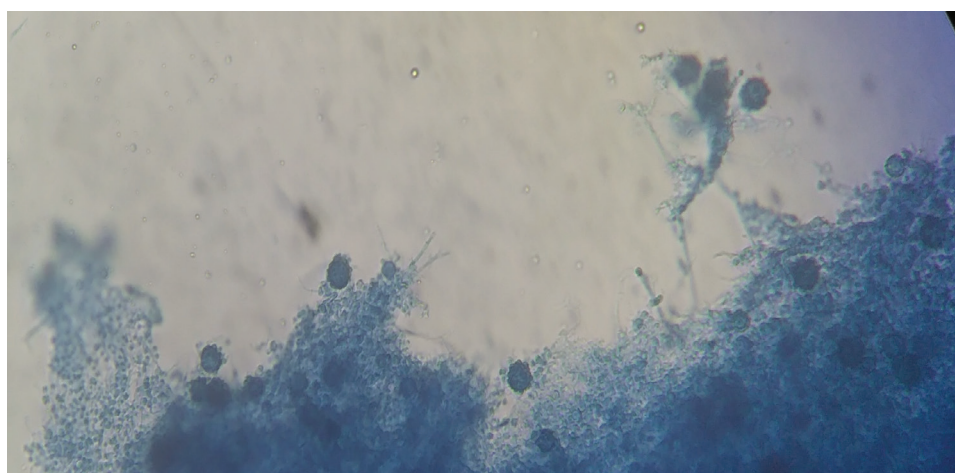


Fig 2

References:

1. De D, Nath UK. Disseminated Histoplasmosis in Immunocompetent Individuals- not a so Rare Entity, in India. *Mediterr J Hematol Infect Dis* [Internet]. 2015 Apr 20 [cited 2016 Aug 30];7(1). Available from: <http://www.ncbi.nlm.nih.gov/pmc/articles/PMC4418405/> <https://doi.org/10.4084/mjihid.2015.028>
2. Deodhar D, Frenzen F, Rupali P, David D, Promila M, Ramya I, et al. Disseminated histoplasmosis: A comparative study of the clinical features and outcome among immunocompromised and immunocompetent patients. *Natl Med J INDIA*. 2013;26(4):214-215.
3. Sanyal M, Thammayya A. Histoplasma capsulatum in the soil of Gangetic Plain in India. *Indian J Med Res*. 1975 Jul;63(7):1020-8.
4. Panja G, Sen S. A unique case of histoplasmosis. *J Indian Med Assoc*. 1954 Mar;23(6):257-8.
5. Ansari HA, Saeed N, Khan N, Hasan N. Laryngeal histoplasmosis. *BMJ Case Rep*. 2016;2016. <https://doi.org/10.1136/bcr-2016-216423>
6. Joshi KR, Chhangani DL, Ramdeo IN, Pandhi SC, Mahopatra LN. Oral histoplasmosis in India. *J Laryngol Otol*. 1973 Feb;87(2):165-70. <https://doi.org/10.1017/S002221510007674X>
7. Sanyal M, Basu N, Roy A, Thammayya A. Primary oral histoplasmosis in India. *Sabouraudia*. 1973 Jul;11(2):115-8. <https://doi.org/10.1080/00362177385190231>
8. Thammayya A, Sanyal M. Histoplasmosis with cutaneous nodules and oral granuloma caused by *Histoplasma capsulatum* in a Bengalee. *Indian J Med Res*. 1979 Mar;69:428-35.
9. Padhye AA, Pathak AA, Katkar VJ, Hazare VK, Kaufman L. Oral histoplasmosis in India: a case report and an overview of cases reported during 1968-92. *J Med Vet Mycol Bi-Mon Publ Int Soc Hum Anim Mycol*. 1994;32(2):93-103. <https://doi.org/10.1080/02681219480000141>
10. Verma RK, Shankar A, Kumar Arora S, Sivaprakash MR, Panda NK. Histoplasma rhinosinusitis presenting as a nonhealing oral ulcer in an immunocompetent patient. *J Otolaryngol - Head Neck Surg J Oto-Rhino-Laryngol Chir Cervico-Faciale*. 2011 Dec;40(6):E47-50.
11. Harnalikar M, Kharkar V, Khopkar U. Disseminated cutaneous histoplasmosis in an immunocompetent adult. *Indian J Dermatol*. 2012 May;57(3):206-9. <https://doi.org/10.4103/0019-5154.96194>
12. Anza K, Mamatha G, Sandhya G, Uma R, Muhammed K. Syphilis of Fungal world: Novel Skin Manifestations of Histoplasmosis in an Immunocompetent Host. *Indian J Dermatol*. 2012;57(6):504. <https://doi.org/10.4103/0019-5154.103089>
13. Vidyanath S, Shameena P, Sudha S, Nair RG. Disseminated histoplasmosis with oral and cutaneous manifestations. *J Oral Maxillofac Pathol JOMFP*. 2013;17(1):139-42. <https://doi.org/10.4103/0973-029X.110722>
14. Sood N, Gugnani HC, Batra R, Ramesh V, Padhye AA, others. Mucocutaneous nasal histoplasmosis in an immunocompetent young adult. *Indian J Dermatol Venereol Leprol*. 2007;73(3):182. <https://doi.org/10.4103/0378-6323.32743>
15. John M, Koshy JM, Mohan S, Paul P. Histoplasmosis Presenting as a Laryngeal Ulcer in an Immunocompetent Host. *J Assoc Physicians India*. 2015 Jun;63(6):69-71.
16. Phatak AM, Bhattacharya I, Misra V, Prabhu AMSR, Natraj U. Disseminated histoplasmosis mimicking laryngeal carcinoma from central India--a case report. *Indian J Pathol Microbiol*. 2006 Jul;49(3):452-4.
17. Randhawa HS, Chaturvedi S, Khan ZU, Chaturvedi VP, Jain SK, Jain RC, et al. Epididymal histoplasmosis diagnosed by isolation of *Histoplasma capsulatum* from semen. *Mycopathologia*. 1995 Sep;131(3):173-7. <https://doi.org/10.1007/BF01102897>
18. Chaurasia D, Agrawal R, Misra V, Bhargava A. Penoscrotal histoplasmosis following bladder carcinoma. *Int J Urol Off J Jpn Urol Assoc*. 2007 Jun;14(6):571-2. <https://doi.org/10.1111/j.1442-2042.2007.01766.x>
19. Baig WW, Attur RP, Chawla A, Reddy S, Pillai S, Rao L, et al. Epididymal and prostatic histoplasmosis in a renal transplant recipient from southern India. *Transpl Infect Dis Off J Transplant Soc*. 2011 Oct;13(5):489-91. <https://doi.org/10.1111/j.1399-3062.2011.00660.x>
20. Chawla A, Chawla K, Thomas J. Genitourinary histoplasmosis in post-renal transplant patient: Diagnostic dilemma. *Indian J Urol IJU J Urol Soc India*. 2012 Jul;28(3):359-61. <https://doi.org/10.4103/0970-1591.102730>