

Original article:

Menstrual pattern of severe intrauterine adhesion following hysteroscopy adhesiolysis

Umme Salma

Abstract:

Objective: The purpose of this study was to evaluate the menstrual and uterine shape in patients diagnosed with severe intrauterine adhesion (IUA) on hysteroscopy and to assess the outcome following hysteroscopic adhesiolysis. **Materials and methods:** It is a retrospective study of patients with severe intrauterine adhesion who attended with complain of infertility, abortion, and repeated dilatation and curettage to our institution from January 2017 and December 2017. Post hysteroscopic adhesiolysis the inserted of urinary balloon catheter and intrauterine device (IUD). The sodium hyaluronate gel was administered inside the uterus and oral cyclical hormonal treatment was initiated after the surgery to all patients to prevent reformation of adhesion, and promote endometrial regeneration respectively. The outcome of menstrual pattern and uterine shape were retrospectively analyzed. Data analyzed was performed with SPSS for Windows, version 20.0). Statistically significant level was set at $p < 0.05$. **Results:** In a total number of 64 patients with severe intrauterine adhesion and mean age of 30.1 years old were participated in this study. No identification of any complication around the hysteroscopy adhesiolysis. Out of 64 severe IUA patients, 59 (92.1%) patients had second, 42 (65.6%) had the third hysteroscopic adhesiolysis procedure required. After 3 months follow-up, restore of uterine shape and 95 % of patients in progress to normal menstruation, which was considered as significant ($p < 0.05$). **Conclusion:** The patients with severe intrauterine adhesion (IUAs) have found significant progress of normal pattern of menstruation with normal shape of the uterine cavity following hysteroscopic adhesiolysis. The repeat procedure and strategies are necessary for prevention of adhesions.

Keywords: Hysteroscopy; Adhesiolysis; Severe intrauterine adhesions; Asherman's syndrome,

Bangladesh Journal of Medical Science Vol. 19 No. 03 July'20. Page : 475-479

DOI: <https://doi.org/10.3329/bjms.v19i3.45865>

Introduction

Intrauterine adhesions occur following injury to the uterine endometrium, which may lead to development of adhesion formation. The uterine wall adherence each other may cause minimal, marginal, or complete obliteration of the uterine cavity during their healing mechanism.¹⁻³ The intrauterine adhesions may extend the endometrium, myometrium, or connective tissue, which proceed to menstrual disturbance, failure to conceive and abortion.³ However, most of the IUA patients present with infertility and menstrual problems.³ Intrauterine adhesions usually result from post traumatic or post infectious injury to the basalis layer of the endometrium leading to healing by fibrosis with the resultant obliteration of the uterine cavity. The frequently of dilatation and curettage (D&C), infection, ischaemia, exposure to foreign materials may develop of intrauterine adhesions.²⁻

⁴ However, in traumatic procedures some patients have experience of IUA formation and some have not. Hysteroscopy is the gold standard technique for the diagnosis intra uterine adhesion, another method like hysterosalpingogram (HSG), ultrasonography^{5, 6} can be used. There are many classification systems for diagnosis of IUAs. The key goals of management of severe intrauterine adhesions are restoration of the normal uterine cavity, preventing recurrence of adhesions, normalization of menstrual flow and improvement of reproductive outcome. Hysteroscopic Adhesiolysis is the procedure of choice in excision of the adhesion bands. Although studies have shown good success rate in restoration of normal endometrial cavity.⁷⁻¹⁰ The main challenges in hysteroscopic adhesiolysis in cases of severe IUAs have difficulty in the excision of the dense adhesion bands, as well as prevention of recurrence. Moreover,

Correspondence to: Umme Salma, Department of Obstetrics & Gynecology, College of Medicine, Jouf University, Sakaka, Kingdom of Saudi Arabia. E-mail: drsalma10@yahoo.com

the purpose of hysteroscopic procedure to re-establish the normal menstruation and the contour of the uterine cavity to improve the possibility for fertility but this method may challenge. The commonest risk was adhesion reformation after hysteroscopy adhesiolysis.¹¹ Our study aimed to detect the results following hysteroscopic adhesiolysis in 64 severe intrauterine adhesions patients by evaluation the stage of IUA, re-establishment of cavity and improvement menstruation.

Materials and methods

Total 64 patients hysteroscopically diagnosed with severe intrauterine adhesions by American Fertility Society (AFS), classification of IUAs.¹² who was treated at the Third Xiangya Hospital, Central South University, China, over a period of January 2017 to December 2017. All patients were complaining of irregular menses, recurrent pregnancy loss and / or infertility were enrolled as per inclusion and exclusion criteria after taking written informed consent. Hysteroscopy adhesiolysis was performed by general anesthesia than the dilation of cervix with 7 Hegar's dilators. The inserted of 6.5-mm therapeutic hysteroscopy with monitoring by ultrasound and then the insertion of micro scissors along the hysteroscope. The lysis of fibrous tissue started from uterine cavity and extent to both lateral wall and fundus of the uterine cavity. The dense fibromuscular adhesions were adhesiolysis with an 8-mm resecto-hysteroscope with hysteroscopic monopolar/bipolar dissection needle-shape electrode, at power settings of 20 W of pure cutting current and 25 W of coagulation current was introduced into the uterine cavity. A 5% mannitol solution was applied for the distension of the uterine cavity by hysteroscopic distension pump at a pressure of 100–120mmHg and a flow rate of 300–440 mL/min. Post hysteroscopic adhesiolysis, a bi-channel 12 Foleys catheter balloon was inserted which was filed 3–4 mL of normal saline and injected 2 mL of sodium hyaluronate gel. The Foleys catheter balloon removed 5 days after surgery, and then applied intrauterine device (IUD) which was removed during a second-look hysteroscopic after 3 months follow up, this procedure continues for each hysteroscopic follow-up. Prophylactic antibiotics (IV 1.0 g of cefoxitin in 100mL of saline) were given to all patients. The hormone therapy was also started from the day of the operation. This therapy consisted of (3–4 mg, twice a day) for 3 months with the addition of progesterone capsules (0.2 g per day) in the last 5–6 days. At the three months follow-up the

patients was assessed for post operative any changes of menstrual pattern, the shape of the uterine cavity and adhesions reformations.

Statistical analysis:

Data was analyzed by using SPSS 20.00 software. Significance considered when p-value was <0.05.

Ethical clearance: The study was started after receiving approval from the Institutional Ethic committee of the Third Xiangya Hospital, Central South University, China.

Results

The range of patients aged in between 23 to 41 years (mean age 30.1 years). Total 65 patients and fifty nine out of the total had show infertility (40 primary and 19 secondary patients) while five patients had a history of repeated abortion. Hypomenorrhoea has been frequently menstrual character which was found in IUA patients (Table 3 and Fig-1). Among the etiological factors evaluated, recurrent abortion (D&C) was the main cause for intrauterine adhesions (54.6%) followed by diagnostic curettage and post-partum curettage (Table 2).

Table 1. American Fertility Society (AFS), classification of intrauterine adhesions.

Extent of cavity involved	<1/3	1/3-2/3	>2/3
	1	2	4
Type of adhesions	Filmy	Filmy & Dense	Dense
	1	2	4
Menstrual pattern	Normal	Hypomenorhea	Amenorrhea
	0	2	4

Cumulative score: stage I (mild) 1–4, stage II (moderate) 5–8, and stage III (severe) 9–12.

Table 2. Demographic characteristic of the study

Variables	Number (%)
Primary infertility	40 (62.5)
Secondary infertility	19 (29.6)
Recurrent pregnancy loss	5 (7.8)
Causes of intrauterine adhesions(IUAs)	
H/O abortion (D&C)	35 (54.6)
H/O diagnostic curettage	28 (43.7)
H/O post-partum curettage	1(1.5)
Menstrual pattern	
Hypomenorrhoea	43 (67.1)
Amenorrhoea	21 (32.8)
H/O=History of, D&C=Dilatation and curettage	

Table 3. Hysteroscopy finding at different sittings of IUA

	First	Second	Third
Normal	5 (7.8)	17 (28.8)	20 (47.6)
Mild	27 (42.1)	30 (50.8)	19 (45.2)
Moderate	29 (45.3)	9 (15.2)	2 (4.7)
Severe	3 (4.6)	3 (5.0)	1 (4.7)
Total	64 (100)	59 (100)	42 (100)

Number in parenthesis represents percentage

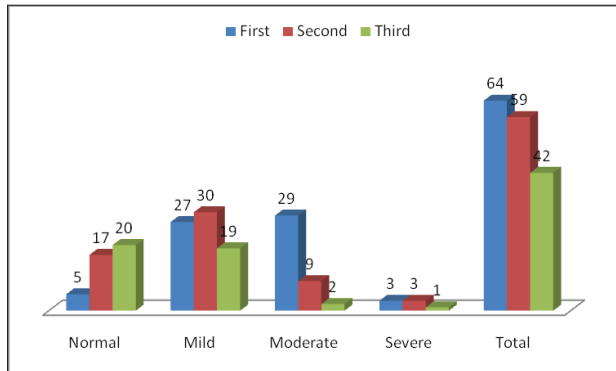


Fig.1. Hysteroscopy finding of different sitting.

Out of 64 patients of IUA, 27 (42.1%) had mild, 29 (45.3%) had moderate and 3 (4.6%) had severe adhesions in the first hysteroscopy procedure (Table 3) and 5 have normal their menstrual flow and no adhesion reformation. Out of 64, 59 (92.1%) patients had a second hysteroscopy after 3 months follow-up and there was no change of their menstruation. Among fifty nine patients, 17 patients have no adhesion reformation and improved their menstruation and uterine cavity, 42 patients did third adhesiolysis among them 3 patients shown persistent severe adhesions. About first setting 3 patients had shown severe adhesions. However, after third adhesiolysis 1 patient had detected as severe intrauterine adhesions (IUAs).

Table4. Characteristic of menstruation before and after the treatment

Before treatment	After treatment of menstrual character		
	Amenorrhea	Hypomenorrhea	Normal
Amenorrhea (n=21)	2 (9.5%)	1(4.7%)	18 (85.7%)
Hypomenorrhea(n=43)	0	0	43(100%)
Total (n=64)	2 (9.5%)	1(4.7%)	61(95.3%)

A total 64 severe IUA patients have done hysteroscopy adhesiolysis, we found 18 (85%) patients shown normal menstruation, 1 (4.7%) patient was hypomenorrhea and 2 (9.5%) patients

were amenorrhea out of 21 patients who was present amenorrhea before adhesiolysis (Table 4). In our study 43 patients were present hypomenorrhea that was shows all have restored normal menstruation after adhesiolysis. As well as total normal menstruation were found 61 (95.3%) and 2 (9.5%), 1 (4.7%) were found amenorrhea and hypomenorrhea respectively. Our result shown that reverse normal menstruation after combined treatment with hormone and surgical technique which was considered significant ($p < 0.05$).

Discussion

The management of severe intrauterine adhesions (IUAs) is challenging and associated with poor reproductive outcomes and a high recurrence rate. In our study, severe intrauterine adhesion accounted for 64 cases that had diagnostic hysteroscopies in our units over the study period. We have classified the severity of the adhesions following by American fertility society classification of intrauterine adhesions in 1998.¹³ In our study, we avoided the adhesion formation by applying both therapies such as hormone and surgical technique that has various effective acts as an anti-adhesion function. However, previous studies found trauma after delivery has been lead to the development of IUA, whereas in our study only found 1.5% related to IUA.^{14,15} The main causes of intrauterine adhesion occurs due to trauma and in our study found almost all the patients has history of repeated dilation and curettage. In our study, 95% case of our patients has restored of normal menstruation in compared to previous results which was around 85% after hysteroscopy adhesiolysis.^{12,16} In the present study, the patient has shown previous experience of uterine surgery (e.g. abortion and curettage, postpartum curettage), with clinical presentation of mostly hypomenorrhea, amenorrhea, pregnancy loss and infertility. This is in line with the hysteroscopy finding of complete cavity involvement in almost all the cases. The dense adhesions were mostly multiple and involving the whole of the uterine cavity. Dense adhesion bands are very tough fibrotic bands that are difficult to resect with the scissor.

Conversely, the patients with extensive and dense adhesion have been lysis with electrode needle until the exposed of the uterine cavity. The hallmark of presentation of the occlusive lesion is reduced/ absent menstrual flow in association with cyclical abdominal pain. The improvement the reproductive function with combined therapy of placing of IUD with hormone treatment has been detected in several

studies while some study only reported use of IUD without hormone therapy which was shown also beneficial effected on IUAs.¹⁷⁻¹⁹ Previous study reported with twenty four IUA has increased normal menstruation around 95% and history of pregnancy about 70% occurs after combined serial flexible office hysteroscopy adhesiolysis with hormonal therapy.¹⁹ According to our finding results, the hysteroscopy adhesiolysis technique may decrease the chance of any inflammatory reaction with insertion of IUD in the uterine cavity and it may lead to provide the facility for early response of patients for their improvement of reproductive function as well as reduce the interval time in between the hysteroscopy adhesiolysis technique and their outcomes.²⁰ In the present study, we have applied intrauterine a Bi-channel 12F Foley's catheter and used 5 ml of normal saline and 2 ml of hyaluronic acid (HA) respectively and keep inside for 5 to 7 days .while it was helping to prevent the recurrence formation of adhesion following adhesiolysis and keep continue the separated uterine cavity by separating the opposite uterine walls. However, Foley's catheter was a safer and successful procedure for prevention of recurrence IUA after adhesiolysis. Previously, several studies have been detected the benefit of placing an intrauterine device and it was represented as an extensively used technique to avoid the recurrence of adhesion formation.^{21, 22} Conversely, in our study, we were immediately placement of an IUD after adhesiolysis, as well as it may continue with the actual shape of the uterine cavity. In the Present study, we found increased endometrial volume and thickness after use of hormone therapies (estrogen–progestin) which were similar found in other studies.^{3,17,19} However, hormone therapy was commonly used for endometrial growth stimulation. However, previous studies documented to use of estrogen hormone therapy due to endometrial growth, which was causes avoided adhesion formation and restored normal menstruation.²³ While the current study found 95.3% cases of normal menstruation after adhesiolysis technique with hormone treatment.

However, it was established that in IUA there were increased the rate of adhesion formation after adhesiolysis of severe IUAs. On the other hand, usually more adhesion formation occurs in more score of IUA such as sever IUA. In the present study found comparatively less adhesion reformation from other studies.^{16, 23} In the present study, our result indicates that it may possible to reduce the adhesion formation in case of severe IUAs after subsequent second and third hysteroscopy adhesiolysis. However, our result found similar to other studies that lead to encourage knowing the possibility of recovering the endometrial function after subsequently hysteroscopy adhesiolysis which was important factors for reproductive function such as menstruation and fertility.^{1,23,24} Moreover, in current study the follow-up of the patients at three months interval to six to one year. While, hysteroscopy lysis causes return to the normal uterine cavity and the improvement of menstrual pattern 95%, all patients were participating in three surgical procedures. There were no complications arise during our procedure.

Conclusion:

The patients with severe intrauterine adhesion (IUAs), we were found following adhesiolysis the significant return the normal menstruation and normal uterine cavity. Possibility of reformation of adhesions is a main fact after surgical technique. The repeat procedures with strategies are necessary for prevention of adhesions.

Acknowledgement

I would like to express my highest thanks to Prof. Xu Da Bao, Gynecology Department of Third Xiangya Hospital Central South University, China.

Source of funding: Self founding.

Authors contributions:

Research designed, collected the data and wrote; Umme Salma.

Conflict of interest: Author declares there is no conflict of interest.

References:

1. J.G. Schenker, E.J. Margalioth, Intrauterine adhesions: an updated appraisal. *Fertil. Steril* 1982;**37**: 593–610.
2. U. Salma , D. Xu, MSA .Sheikh, Diagnosis and treatment of intrauterine adhesions. *Bangladesh Journal of Medical Science* 2011 ;**10**:72-82.
3. J.G. Schenker, Etiology of and therapeutic approach to synechia uteri. *Eur. J. obstetrics Gynecol reproductive Biol.* 1996 ;**65**:109–113.
4. Buckley CH. Normal endometrium and non-proliferative conditions of the endometrium. In: Fox H, Wells M, editor. *Obstetrical and Gynaecological Pathology Churchill Livingstone.* 2002; 391–442.
5. Diamond MP, Freeman ML. Clinical implications of postsurgical adhesions [J].*Hum Reprod.* 2001; **7**:567–76.
6. Seshadri S, El-Toukhy T, Douiri A et al. Diagnostic accuracy of saline infusion sonography in the evaluation of uterine cavity abnormalities prior to assisted reproductive techniques: a systematic review and meta-analyses. *Hum Reprod Update.* 2015; **21**: 262-74.
7. Kim MJ, Lee Y, Lee C et al. Accuracy of three dimensional ultrasound and treatment outcomes of intrauterine adhesion in infertile women. *Taiwan J ObstetGynecol.*2015; **54**: 737-41.
8. Roy KK, Baruah J, Sharma JB et al. Reproductive outcome following hysteroscopic adhesiolysis in patients with infertility due to Asherman’s syndrome. *Arch Gynecol Obstet.*2010; **281**: 355-61.
9. Yang JH, Chen CD, Chen SU et al. The influence of the location and extent of intrauterine adhesions on recurrence after hysteroscopic adhesiolysis. *BJOG* .2016; 123: 618-23.
10. Hanstede MM, van der Meij E, Goedemans L et al. Results of centralized Ashermansurgery.*FertilSteril.* 2015; **104**: 1561-8.
11. Zhang A, Jamail G, Xue M et al. Hysteroscopic Intrauterine Adhesiolysis Using the “Ploughing” Technique with Cold Scissors. *J Minim Invasive Gynecol.*2015; **22**: 93-45.
12. Yu D, Li TC, Xia E, Huang X, Liu Y, Peng X. Factors affecting reproductive outcome of hysteroscopicadhesiolysis for Asherman’s syndrome. *Fertil Steril.* 2008; **89**:715–22.
13. The American Fertility Society classifications of adnexal adhesions, distal tubal occlusion, tubal occlusion secondary to tubal ligation, tubal pregnancies, Müllerian anomalies and intrauterine adhesions. *Fertil Steril.* 1988; **49**: 944–55.
14. Asherman JG. Amenorrhoea traumatic (atretica). *J ObstetGynaecol Br Emp.* 1948; **55**:23-30.
15. Conforti A, Alviggi C, Mollo A, De Placido G, Magos A. The management of Asherman syndrome: a review of literature. *Reprod Biol Endocrinol.* 2013; **11**:118.
16. Yu D, Wong YM, Cheong Y, Xia E, Li TC. Asherman syndrome--one century later. *FertilSteril.* 2008; **89**:759-79.
17. Valle RF. Intrauterine adhesions: hysteroscopic diagnosis, classification, treatment, and reproductive outcome. *Am J Obstet Gynecol.* 1988; **158**:1459–70.
18. Sugimoto O. Diagnostic and therapeutic hysteroscopy for traumatic intrauterine adhesions. *Am J Obstet Gynecol.* 1978; **131**: 539–47.
19. Sanfilippo JS, Fitzgerald MR, Badawy SZ, Nussbaum ML, Yussman MA. Asherman’s syndrome. A comparison of therapeutic methods. *J Reprod Med.* 1982; **27**:328–30.
20. Robinson JK, Colimon LM, Isaacson KB. Postoperative adhesiolysis therapy for intrauterine adhesions (Asherman’s syndrome). *Fertil Steril.* 2008; **90**:409–14.
21. Massouras HG. Intrauterine adhesions: a syndrome of the past, with the use of the “Massouras” Duck’s Foot No. 2 IUD. *Am J Obstet Gynecol.*1973; **116**:576.
22. Jewelewicz R, Khalaf S, Neuwirth RS, VandeWiele RL. Obstetric complications after treatment of intrauterine synechiae (Asherman’s syndrome). *ObstetGynecol.* 1976; **47**:701–5.
23. Polishuk WZ, Weinstein D. The Soichet intrauterine device in the treatment of intrauterine adhesions. *Acta Eur Fertil.* 1976; **7**:215.
24. Songshu Xiao, YajunWanetal. Etiology, treatment, and reproductive prognosis of women with moderate-to-severe intrauterine adhesions.*International Journal of Gynecology and Obstetrics.* 2014.