

**Case report:**

**Ectopic carcinoma ex-pleomorphic adenoma in the lower neck: a rare entity at a rare location**

*Kuganathan Ramasamy<sup>1</sup>, Yatiee Swany Lahuri<sup>2</sup>, Norhaslinda Abdul Gani<sup>3</sup>, Noor Hasni Shamsudin<sup>4</sup>*

**Abstract**

Ectopic salivary gland tissue (ESGT) is salivary tissue located outside the major, minor and accessory salivary glands. Neoplasms rarely arise from ESGT, let alone carcinoma ex-pleomorphic adenoma (CEPA) which is a malignant tumour that arises from the epithelial component of pleomorphic adenoma. It usually occurs in the parotid gland and in lesser instances, from submandibular gland or minor salivary glands. Herein, we report a rare case of CEPA in right supraclavicular ESGT of a 67-year-old lady. She underwent complete surgical excision of the mass and is free from any recurrence to date. Brief review of pathogenesis, clinical features and treatment of ectopic CEPA are discussed. A thorough review of the English literature reveals that our patient may be the second case of ectopic CEPA in the neck region ever reported to date.

**Keywords** : Carcinoma ex-pleomorphic adenoma; pleomorphic adenoma; ectopic salivary gland; neck

*Bangladesh Journal of Medical Science Vol. 20 No. 03 July'21. Page : 658-661  
DOI: <https://doi.org/10.3329/bjms.v20i3.52812>*

**Introduction**

Ectopic salivary gland tissue (ESGT) is salivary tissue located outside the major, minor and accessory salivary glands. Neoplasms originating from ESGT are rare and often present as an enigmatic finding to clinicians. The finding of carcinoma ex-pleomorphic adenoma (CEPA) in ESGT is even rarer let alone at supraclavicular region. CEPA is a malignant tumour that arises from the epithelial component of pleomorphic adenoma (PA), either from primary or recurrent PA. A thorough review of the English literature reveals only solitary case of CEPA arising from ESGT in neck being reported<sup>1</sup>. We present a case of CEPA originating from ESGT at lower neck with a brief literature review on the pathogenesis, clinical features and treatment options of ectopic CEPA.

**Case report**

A 67-year-old lady with underlying hypertension presented with complaint of painless swelling in the right supraclavicular region for 6 months. She denied other symptoms during that period. Her past surgical history was significant for a right hemithyroidectomy done in 2014 for nodular hyperplasia of thyroid. On examination, there was a swelling over the right supraclavicular area measuring 3 x 4 cm, firm, mobile and non-tender. There were no other palpable lymph nodes in the neck. Systemic examination was unremarkable. Fine needle aspiration cytology (FNAC) revealed features suggestive either of salivary gland tumour or adnexal tumour. It was indeterminate as despite the bland looking nuclei, there was high proliferative index noted with necrotic

1. Kuganathan Ramasamy, Department of Otorhinolaryngology-Head & Neck Surgery, Hospital Tuanku Ja'afar, Seremban, Negeri Sembilan, Malaysia.
2. Yatiee Swany Lahuri, Department of Otorhinolaryngology-Head & Neck Surgery, Hospital Tuanku Ja'afar, Seremban, Negeri Sembilan, Malaysia.
3. Norhaslinda Abdul Gani, Department of Otorhinolaryngology-Head & Neck Surgery, Hospital Tuanku Ja'afar, Seremban, Negeri Sembilan, Malaysia.
4. Noor Hasni Shamsudin, Department of Pathology, Hospital Tuanku Ja'afar, Seremban, Negeri Sembilan, Malaysia.

**Correspondence to:** Kuganathan Ramasamy, Department of Otorhinolaryngology-Head & Neck Surgery, Hospital Tuanku Ja'afar, Jalan Rasah, 70300 Seremban, Negeri Sembilan, Malaysia. E-mail address: [kuganathan.ram@gmail.com](mailto:kuganathan.ram@gmail.com)

areas. Contrast-enhanced Computed Tomography (CT) scan of the neck showed heterogeneously enhancing lesion at the right supraclavicular region measuring 3.9 x 3.9 x 3.6cm.

The patient underwent complete excision of the lesion under general anaesthesia. Intraoperatively, the mass was attached to the underlying SCM. Surgical specimen consists of brownish tissue measuring 4 x 2 x 3cm. Histopathological examination (HPE) revealed biphasic tumour with epithelial and myoepithelial differentiation suggestive of CEPA. There was no perineural invasion and immunohistochemistry was positive for cytokeratin and smooth muscle actin stains. Ki67 proliferative index was about 40% (Figure 1A-1C). The post-operative course was uneventful (Figure 2). Upon confirmation of HPE findings, a CT-TAP was arranged to look for distant metastasis, which turned out negative. There is no sign of local or distant recurrence in one year follow-up since surgery. Informed consent was obtained from the patient for this report.

### Discussion

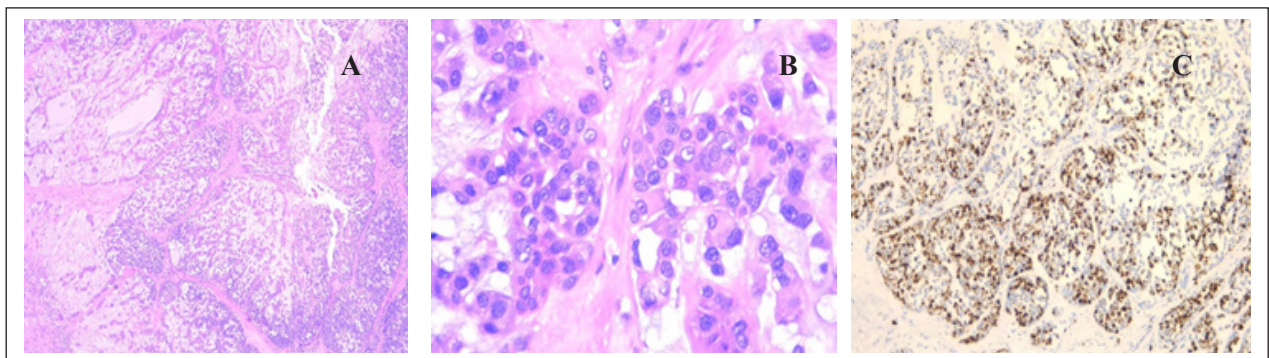
ESGT is defined as salivary gland tissue occurring outside the major, minor and accessory salivary glands with no clinical or histological features of branchial cleft anomalies<sup>2</sup>. ESGT has been recorded as early as 1789 and reported in various sites such as lymph node, external auditory canal, mandible, mastoid, middle ear, tongue, SCM, thyroid, parathyroid and neck<sup>3</sup>. ESGT tends to occur more often in upper neck than lower neck<sup>4</sup>.

Many theories regarding the development of ESGT in neck have been proposed in the past. These include; first, abnormal persistence and development of

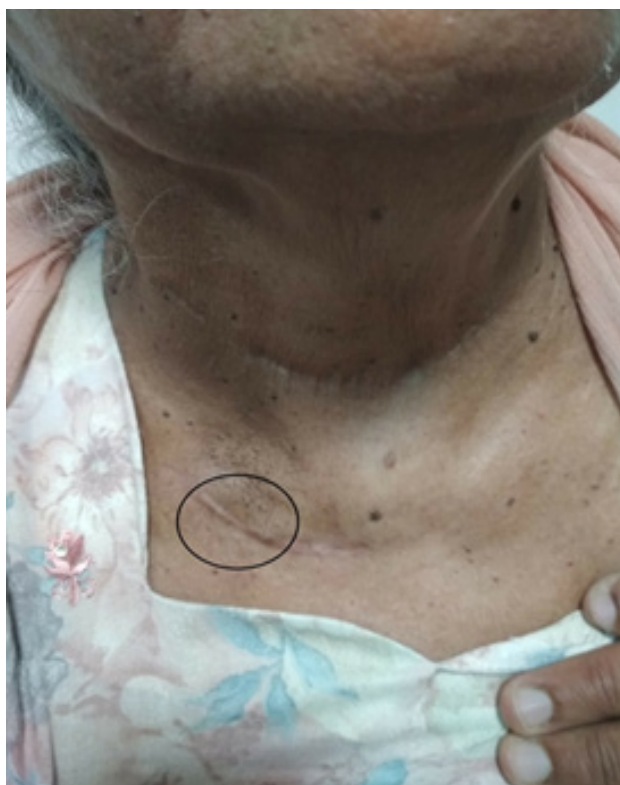vestigial structures; second, dislocation of a portion of definitive organ rudiment during mass movement and thirdly, abnormal differentiation of the local tissues<sup>5</sup>. Specific to the ESGT in lower neck, the most accepted theory is that of Youngs & Schofield who suggested it was due to the defective closure of pre-cervical sinus of His with the heteroplasia of the ectodermal lining within the sinus<sup>6</sup>. The usual presentation for upper neck ESGT is a slowly enlarging, painless and mobile mass, while lower neck ESGT usually presents as a draining sinus<sup>4</sup>. The unusual presentation of ESGT as a mass in the lower neck as well as neoplasm arising from it further piques the interest of our case.

Despite arising in unusual locations, ESGT is also subjected to the same pathologies affecting the major/minor salivary glands. While neoplasms arising from ESGT are rare, 80% of it are benign and PA is the second most common neoplasm after Warthin's tumour<sup>3,5</sup>. Specific to ectopic PA, it has same percentage of recurrence but higher percentage of cancerisation compared to that of occurring in major salivary glands<sup>7</sup>.

Malignant transformation of PA can present in three different forms namely CEPA, carcinosarcoma and metastasising PA. The risk of malignant transformation ranges from 3% to 15%, higher in larger tumour size and longer duration of symptoms<sup>1</sup>. CEPA accounts for 11.6% of all malignant salivary gland tumours<sup>8</sup>. The malignant transformation of PA is described in sequence. In the initial stage, tumour is surrounded by myoepithelial cells and labelled as Carcinoma in situ. Next stage would be intracapsular carcinoma, whereby tumour cells invasion occur but without breach of the fibrous capsule of PA. Invasion



**Figure 1**(A) Low magnification shows biphasic tumour composed of an admixture of epithelial cells amid fibrohyalinised and chondromyxoid stroma (B) Higher magnification shows the tumour cells possessing pleomorphic nuclei with coarse chromatin (C) Ki67 proliferative labeling index shows more than 40% of tumour cells are expressed



**Figure 2** Ectopic carcinoma ex-pleomorphic adenoma was removed from the circled site

beyond the capsule would be diagnosed as invasive CEPA. Invasive CEPA is further divided into microinvasive if the extracapsular invasion is 1.5mm and less; and frankly invasive if beyond 1.5mm<sup>9</sup>.

In our patient, the mobile and well-circumscribed nature of the mass was suggestive of benign lesion. However, the sudden onset and rapid growth of the mass, old age and inconclusive findings of the earlier biopsy were suspicious of malignancy. It is imperative to note here that CEPA can mimic PA clinically and preoperative biopsy can also be non-diagnostic in many instances. Several studies have only reported correct preoperative diagnosis of CEPA ranging from 29%-49% using FNAC<sup>10</sup>. An algorithm for management of neoplasms arising from ESGT was proposed by Daniel and McGuirt, suggesting excision alone for benign lesions and isolated low-grade malignant tumours while extensive surgery

with possible radiotherapy for high-grade malignant tumours<sup>3</sup>. Our patient was treated accordingly with complete surgical excision of the tumour. Radiotherapy is not indicated for our patient as she had undergone complete excision with clear surgical margins.

### **Conclusion**

The evaluation of neck mass may be an intriguing process depending on the location. The common differentials include neck cysts, lymphoma, thyroid mass and metastases from head and neck malignancies. ESGT is a rare finding particularly neoplasm arising from it. Nevertheless, ESGT neoplasm ought to be considered as one of the differential diagnosis when encountering such neck mass. Proper preoperative management comprising of history, physical examination, cytology/tissue biopsy and imaging studies should be carried out prior to the planned surgery. Extended surgery with possibility of irradiation should be considered in cases of high-grade malignant neoplasm of ESGT.

**Conflict of Interest** No conflicts of interest were declared by the authors

**Source of Fund** There was no source of funding for this case report

**Ethical clearance** Consent was obtained from the patient and submitted to hospital Ethics Committee prior to submission of this manuscript

### **Authors' contribution**

Data gathering and idea owner of this study: Ramasamy K, Lahuri YS, Abdul Gani N, Shamsudin NH

Study design: Ramasamy K, Lahuri YS, Abdul Gani N

Data gathering: Ramasamy K, Lahuri YS, Abdul Gani N, Shamsudin NH

Writing and submitting manuscript: Ramasamy K

Editing and approval of final draft: Lahuri YS, Abdul Gani N, Shamsudin NH

**References:**

1. Ismi O, Vayisoğlu Y, Arpacı RB, Eti C, Pütürgeci T, Gorur K, Özcan C. Carcinoma ex pleomorphic adenoma originating from ectopic salivary gland in the neck region: case report. *Gland Surg* 2015; **4**:567-571.<http://dx.doi.org/10.3978/j.issn.2227-684X.2015.01.03>
2. Cannon D, Szabo S, Flanary V. Heterotopic salivary tissue. *Am J Otolaryngol*.2012; **33**:493-496. <https://doi.org/10.1016/j.amjoto.2011.11.003>
3. Daniel E, McGuirt W. Neck masses secondary to heterotopic salivary gland tissue: a 25-year experience. *Am J Otolaryngol*.2005; **26**:96-100. <https://doi.org/10.1016/j.amjoto.2004.08.009>
4. Tay H, Howitt R. Heterotopic pleomorphic adenoma in the neck. *The Journal of Laryngology & Otology*.1995; **109**:445-448. <https://doi.org/10.1017/S0022215100130403>
5. Ferlito A, Bertino G, Rinaldo A, Mannarà G, Devaney K. A review of heterotopia and associated salivary gland neoplasms of the head and neck. *The Journal of Laryngology & Otology*.1999; **113**:299-303.<https://doi.org/10.1017/S0022215100143841>
6. Youngs LA, Schofield HH. Heterotopic salivary gland tissue in the lower neck. *Arch Pathol*.1967; **83**:550-6.
7. Chang CF, Wang CW. Pleomorphic Adenoma of Ectopic Salivary Gland Tissue in the Upper Neck. *Head Neck Cancer Res*. 2016, **1**:2. <https://doi.org/10.21767/2572-2107.100009>
8. Felix A, Rosa-Santos J, Mendonça M, Torrinha F, Soares J. Intracapsular carcinoma ex pleomorphic adenoma. Report of a case with unusual metastatic behaviour. *Oral Oncology*.2002; **38**:107-110.[https://doi.org/10.1016/S1368-8375\(01\)00023-9](https://doi.org/10.1016/S1368-8375(01)00023-9)
9. Cheuk W, Chan JK. Advances in salivary gland pathology.*Histopathology*.2007; **51**:1-20.<https://doi.org/10.1111/j.1365-2559.2007.02719.x>
10. Zbären P, Zbären S, Caversaccio M, Stauffer E. Carcinoma ex pleomorphic adenoma: Diagnostic difficulty and outcome. *Otolaryngology-Head and Neck Surgery*.2008; **138**:601-605.<https://doi.org/10.1016/j.otohns.2008.01.013>