

Review Article/Meta-analysis

Fabrication of single piece definitive obturator for post surgical maxillectomy defect during covid-19 pandemic- A Literature review with Clinical case report

Dr Anupama Aradya¹, Dr. Narahari Ranganatha², Dr. Sreeshyla H S³, Dr. Giriraj Sandeep⁴

Abstract

Background: Impacts of primary oncology surgical procedure can impede restoration objectives. Restoring oral function, comfort and aesthetics is a challenge due to limitations in the restorative treatment options. **Methodology:** Literature review on the responsibilities, role of maxillofacial prosthodontist, materials and retentive aids used for prosthesis, classification of maxillofacial prostheses, recent advancements in MFP and Workflow for the fabrication of obturator prostheses in the COVID-19 pandemic scenario. Case report on the fabrication of Hollow bulb definitive obturator during pandemic crisis. A 47 years old male patient reported for post-surgical evaluation in maxillary posterior region of oral cavity. The patient had partial maxillectomy surgical procedure of squamous cell carcinoma in the palate 5 years back. To replace the gap created, the patient was using interim obturator. He had facial asymmetry and collapse. Prosthodontic rehabilitation with one piece closed hollow bulb obturator was planned & subsequently fabricated for the patient. For our case considering the feasibility & ease of manipulation, heat activated acrylic resin was used for this particular patient for rehabilitation. The method described is easy, simple, time saving & economical. Bulb portion was hollow & made of heat cure resin, so weight was less & less chances of tissue irritation. **Results:** With the Covid-19 infection protocol measures taken definitive obturator was given to the maxillectomy patient to restore aesthetics, function and comfort as well. After insertion of prostheses mastication, deglutition and phonetics were improved. Breathing problems were resolved and aesthetics was improved. **Conclusion:** A simplified technical approach for the treatment of a patient with palatal defect of and other supportive structure has been presented in Covid-19 situation following the described infection prevention protocols. The technique presented offers a method of obtaining a detailed impression of the defect and promptly provides the patient with a light weight, easy-to-use and flexible tissue- tolerant obturator.

Keywords-Covid-19; obturator; prosthesis; cancer; challenges

Bangladesh Journal of Medical Science Vol. 21 No. 04 October '22 Page : 676-684
DOI: <https://doi.org/10.3329/bjms.v21i4.60272>

Introduction

Around the world, the fifth most common cancer is oral malignancy with the seventh most elevated mortality.¹ The survival rate has been improved with the advances in the management of cancer.²

Effects of primary oncology surgical procedure can impede restoration objectives. These effects incorporate a reformed anatomy of oral cavity, conceded soft tissue conditions, modified muscle attachments, losing lip competence, loss of bony

1. Dr Anupama Aradya _{MDS}, Assistant professor, Department of Prosthodontics JSS Dental college and Hospital, A Constituent college of JSS Academy of Higher Education & Research, Mysore, Karnataka India -570015. Email- dranupamavenu@gmail.com
2. Dr. Narahari Ranganatha _{MDS}, Reader, Department of Oral & Maxillofacial Surgery, Shree Rajarajeswari Dental college and Hospital, Bangalore-560074 Karnataka. India. Email-narahari2012@yahoo.com
3. Dr. Sreeshyla H S _{MDS}, Assistant Professor, Department of Oral Pathology and Microbiology, JSS Dental college and Hospital, A Constituent college of JSS Academy of Higher Education & Research, Mysuru, Karnataka. India -570015. Email-dr.sreeshylahs@jssuni.edu.in
4. Dr. Giriraj Sandeep _{MDS}, Senior Lecturer, Department of Oral & Maxillofacial Surgery, Shree Rajarajeswari Dental college and Hospital. Bangalore-560074. Karnataka. India.

Correspondence: Dr. Sreeshyla H S _{MDS}, Assistant Professor, Department of Oral Pathology and Microbiology, JSS Dental college and Hospital, A Constituent college of JSS Academy of Higher Education & Research Mysuru, Karnataka. India -570015. Email-dr.sreeshylahs@jssuni.edu.in

structures and teeth, changes in facial emergence and causing trismus. Due to limitations in the restorative treatment options restoration of oral function, comfort and aesthetics is a challenge.³

A multidisciplinary group approach ought to be utilized for the complete restoration of head and neck malignant growth (HNC). This group includes several strengths like onco-Surgeons, general surgeons, plastic surgeons, physicians, medical oncologist, radiotherapist, physiotherapist, maxillofacial prosthodontist (MFP), speech therapist, nutritionist, occupational therapist, psychologist, rehabilitation nurture, social worker, recreational specialist.⁴

The oro maxillary defacement bring about regurgitation of oral fluids, change in voice because of asynchrony in resonance, and difficulty in speech and swallowing. The maxillofacial prosthodontist is included in diagnostic examination, restoration and maintenance of oral function, providing comfort, aesthetics, and health to patients who are going through chemo and radiation therapies. This expert review addresses the involvement of maxillofacial prosthodontists in treatment planning, highlighting prosthodontic restoration of head and neck malignancy patients from beginning to end and a case report on the definitive obturator fabrication during Covid-19 Pandemic.

Responsibilities of MFP's

- In the management of HNC patients, responsibility of MFP is bifold. Initial responsibility is recognizing the complaints identified with oral, perioral and masticatory sources so that they can be treated with dental procedures. Furthermore map out the rehabilitation being aware of prognosis of the prosthetic therapy.
- They guarantees the broad scope of services like intraoral and extra oral prosthesis, cleft lip and cleft palate rehabilitation, reconstructive plastic surgery, management of temporomandibular joint disorder, dental implant restoration.
- Additionally includes the oral prophylaxis of all cancer patients in whom sufficient oral cleanliness and its maintenance is of utmost importance prior to cancer treatment. Planning of Pre-prosthetic surgery to eliminate anatomic interferences and to fulfill healthy oral hard and soft tissue to receive future prosthesis.⁵

Classification of Maxillofacial Prostheses

For the most part, maxillofacial prostheses can

be classified as restorative or complementary. Restorative prostheses replace for repair of facial contour deformities and bone loss. -They can be fabricated internally within the tissue or externally as oral, ocular, nasal, auricular or facial prostheses. Complementary prostheses assist with plastic surgery, in the pre, trans, or postoperative forum, or in radiotherapy period.⁶

Palatal Obturator Prostheses- Fabricated to close the communication between the oral and nasal cavities, restoring speech and improving mastication and swallowing of the patient.⁷

The obturator prostheses are immediate, transitional and definitive. Immediate obturators can be fabricated prior to surgery and inserted immediately following the surgical procedure to protect the surgical cavity. The temporary obturator, fabricated few weeks after the surgery allowing time for customization and tissue repair. Restorative, or definitive, prostheses are fabricated after healing. They have all the attributes of conventional prostheses, are more functional, and result in better aesthetics and comfort.

External Buccal Prostheses- The seek of prosthetic treatment for intraoral impairment is to re establish the patient's masticatory function and phonetics, improve aesthetics, and restore their psychosocial well-being. During the contraindication of intraoral reconstructive surgery, palatal obturator, mandibular, and tongue prostheses can be used for the treatment.⁸

Mandibular Prostheses- The entire stomatognathic system is impaired by partial or total mandibulectomy subsequently, surgery and prosthetic reconstruction are particularly difficult. Mucosupported complete dentures or removable partial prostheses may only partially restore lost aesthetic qualities, due to articular changes and a shortened prosthetic basal area, the function remains impaired.

Tongue Prostheses- It can guide the alimentary bolus to the oropharynx, for verbalization of dentilingual phonemes and vowels, improves the patients' ability to chew, swallow, and speak. In addition the elimination of sibilant distortions, improving of speech intelligibility can be achieved by the utilization of palatography.⁹

Ocular Prostheses- They retain tone of the upper eyelid muscles, preserve the conjunctival and tear duct dryness, prevent eyelid atresia due to lack of function, and protection of cavity mucosa from debris and dust.

Facial Prostheses- In general, facial prostheses can be classified as nasal, lip, oculo palpebral, auricular and skullcap. These prostheses artificially reconstruct soft and hard tissues which were recently lost, restore the patient's appearance, leading to improved self-esteem and quality of life. For example, auricular prosthesis improves hearing in noisy conditions, the nasal prosthesis further improves airflow and speech, lip prostheses seal the lips, reestablish lip support and ensure better chewing, swallowing, and speech. Traqueostomal prostheses permit breathing, speech, and filtering the air, Skullcap prostheses secure the brain.¹⁰

Radiotherapy Prostheses- These prostheses, also called as radium-holder apparatus, permit radioactive elements to be oriented to treat the tumour, constricting the doses consumed by adjacent healthy tissues. They are utilized for brachytherapy or external actinotherapy by contact.¹¹

Materials utilized for the Maxillofacial prostheses

Acrylic resins based on polymethyl methacrylate (PMMA) and copolymers, polyurethanes, polyvinyl chloride and copolymers, latex, and silicone polymers like HTV, RTV, foaming silicones, the new materials like silicone block copolymers, polyphosphazenes. In order to match the patient's skin tone silicone rubber can also be infused with colored pigments.⁶

Purposes behind referring patients to maxillofacial prosthodontist

To complete most of the preoperative dental procedures within 24 hours of introductory reference is necessary, because this will help to prevent acute dental infection and related pain and further more to accomplish the conceivable tissue and teeth support for prosthesis. In advance the diseased/malposed/impacted teeth can be brought to the oral and maxillofacial surgeons notice that can be extracted regardless of the extent of surgical defect during the operation itself. Essentially, if the routine oral cleanliness procedures are not viably practiced acute oral infections like necrotizing ulcerative gum disease will probably be exacerbated in a postoperative period.⁵

Retentive aids for Maxillofacial Prostheses

Mechanical variables like adhesions, crowns, and magnets as well as anatomic factors such as hard and soft tissue residue in trauma or post-surgery deformity, concavities and protrusions in auricular or orbital region, zygoma support, and external auditory

pathway have been utilized. Conservation of residual structure such as teeth, pre maxillary region, nasal bone, vestibular depth etc supports various structures in retention of intraoral prosthetic devices.¹²

Cast Partial Dentures: Properly designed retainers of cast partial denture decline the stresses transmitted to the abutment teeth while retaining the obturator in place and contributing to the success of obturator prostheses

Magnets: The most powerful commercially available primary magnetic material utilized is neodymium iron boron (Nd-Fe-B). They have been adequately utilized for retention, maintenance and stabilization of combined maxillofacial prosthesis.

Implants: In case of less retention, stability and support endo osseous implants may be used as an alternative anchorage system. Dental implants have helped in establishing increased level of physical and psychological comfort with the maxillofacial prosthetic rehabilitation. The literature shows that the favorable functional outcome is achieved in patients treated with implant retained prosthesis.¹³

Other Retention Methods

In situations where an implant or adhesive systems cannot be used for number of reasons, eyeglasses can be utilized viably, especially for nasal prostheses. If eyeglasses have thick, opaque frames, they help to camouflage the prosthetic margins. A consistently utilized method is the permanent attachment of prostheses, in cases including mid-field face defects, to the glasses.¹²

Refer to MFP's

- The prosthodontist ought to be available at the initial treatment planning and make preoperative dental impressions because during post-operative period patients are relatively uncomfortable due to facial incisions, blood on mucosa, swelling and coating of dried mucosa. They cannot keep up their oral cleanliness adequately, thus making an accurate impression procedure difficult. Subsequently rehabilitation ought to be considered before formation of physiologic and restorative deficiencies.
- Prosthesis planning always begins prior to any HNC surgical procedures and besides, the transitional phase between the time of carcinoma surgical removal and reconstructive plastic surgery.
- Patients who were referred during treatment

planning are mentally prepared about the reality whereas, patients often have high expectation in case they are referred after oncotherapy to MFP's therefore treatment planning and dental treatment for these patients can be achieved satisfactorily if they are referred prior.⁵

Recent advancements in Maxillofacial Prostheses

The maxillofacial prosthodontics as a profession has far improved with the advent of upgradation dental material science, Computer aided design-Computer aided manufacturing information technology, osseointegrated implant treatment, and rapid prototyping methods. These technological advancements revolutionized the outcome of prosthodontic rehabilitation by virtual planning and exact, lifelike fabrication of prosthesis.

With the presentation of three dimensional planning and computer aided design (CAD) assistance, preoperative virtual augmented models are great asset to the surgical team and support shared decision-making regarding favourable reconstruction choice after oncology treatment.¹⁴ Three-dimensional planning enables a high accuracy of guided resection surgery and prosthetic-driven reconstruction planning. With the utilization of 3D printed guides, a 3D Virtual Surgical Planning (VSP) can be precisely executed by creating the possibility of completing a full ablative and reconstructive plan in surgery. However, soft tissues are not very reliably reproduced yet by digital techniques. This is still an uncertain factor to be considered with regards to planning prosthetic treatment. Tools to better reproduce soft tissues are in development.¹⁵

In spite of the mention of digital technology use in maxillofacial prostheses has extended strikingly in the main prosthodontics journals in the course of the most recent ten years, absolute article movement remained moderately little. The increased utilization of digital technology was more apparent in case reports whereas use of innovation technologies was more frequently mentioned in original research articles. Knowledge of the utilization of digitization, design and Rapid Prototyping advances in original research on maxillofacial prosthetics ought to be improved.¹⁶

Ravish et al briefed in their original study that there seems to be lack of involvement of MFP in the management of HNC patients due to availability, efficiency and inadequate hospital setup. Awareness of onco surgeons about dental implant therapy seems

to be lacking, so maxillofacial prosthodontists ought to be included from the beginning in the management of head and neck malignancy patients to provide essential guidance for optimal oral rehabilitation and to enhance quality of life of cancer survivors.¹⁷

Workflow for the fabrication of obturator prostheses in the COVID-19 pandemic scenario

The COVID-19 pandemic established time-sensitive challenges and essential concerns that require developing new and quick solutions as alternatives in contrast to routine standard evidence-based protocols which require significant time and co operations among dentist and patient. Therefore, worldwide dissemination of this information to health care professionals can assist with preventing COVID-19 infection.¹⁸⁻²¹

On a single dental appointment dental experts can be exposed to all common courses for COVID-19 contamination (aerosols and droplets, contact with materials, dental sharp instruments, or contaminated surfaces),²²and even when a procedure is finished, they are exposed because of the long period that pathogenic microorganisms remain suspended in the air. Confronting a pandemic situation, maxillofacial rehabilitation specialists associated with supportive care in cancer must rearrange dental clinical practice to take into consideration of care of patients contaminated with COVID-19 who require prosthodontic appliances.

Alternative and further developed protocols could assist patients with complex condition to rapidly get back to normal function. By strategically altering the prosthodontic rehabilitation protocol, patients can receive necessary cancer care and abandon the need to go through long hospitalization, regular subsequent visits for obturator adjustments, and even so maintain adequate oral function and trauma control.²³

To avoid unnecessary consultations during covid-19 pandemic, for the fabrication of the surgical obturator prosthesis models must be produced at the same time of hospitalization, followed by intraoperative installation. To decrease follow-up for necessary adjustments, a reline or an impression and fabrication of a new prosthesis (interim obturator) must be performed on the day of hospital discharge reducing the ideal time of this phase transition from 7 days to approximately 3 days.²⁴ Obviously, this is a prudent outcome during the pandemic of COVID-19. Furthermore, such procedure will ensure a longer period of time until the need for a replacement or

relining of the prosthesis. Additionally, with these protective measures, tele consults and, mainly, video calls are considered as reliable strategies for patients' guidance and functional assessments.²⁵

At the point when consultation is unavoidable, breaks in appointments are considered for proper time of environment disinfection between patients. Of significance is the education of the patient to arrive at the scheduled time, minimizing long waiting. Whenever possible, the patient's family member or carer should not enter the dental office.

Case Presentation

The sole responsibility of a maxillofacial prosthodontist is rehabilitation of patients with acquired defects of the maxilla after surgical resection. The maxillary soft palatal defects cause oro nasal/oroantral communication result in difficulties in speech, mastication, deglutition, nasal regurgitation, facial collapse(fig.1 & fig.2) and also in aesthetics. Finally it results decreased quality of life and confidence for the patients, who create a challenging situation to the maxillofacial prosthodontist.²⁶

Obturator is a prosthesis used to close a congenital or acquired tissue opening, primarily of hard palate as well as adjoining alveolar/soft tissue structures.

Confronting a pandemic scenario, maxillofacial rehabilitation specialists involved in supportive care in cancer must adapt dental practice to allow for continuation of care of patients infected with COVID-19 who require prosthodontic appliances.²⁷

Diagnosis

This case report depicts the clinical and laboratory management of a patient of partial maxillectomy using one piece hollow close bulb obturator during covid-19 pandemic.

A 47 years old male patient reported for post surgical evaluation in maxillary posterior region of oral cavity. The patient had partial maxillectomysurgical procedure of squamous cell carcinoma in the palate 5 years back (fig.3). To replace the gap created, the patient was using interim obturator. He had facial asymmetry and collapse(fig.1& fig.2)

Treatment Objectives

Prosthodontic rehabilitation with one piece closed hollow bulb obturator was planned & subsequently fabricated for the patient. Heat activated acrylic resin was used in our case considering the feasibility & ease of manipulation for rehabilitation.

As an integral part of the Covid-19 infection prevention protocol, proper COVID-19 professional protective equipment (PPE) use (isolation gown, disposable working cap, goggles or face shield, disposable N95 mask, and disposable gloves) is a must. Hand-washing techniques (water and soap or \approx 70% alcohol gel) must be consistent with World Health Organization protocols designed for health care workers.²²

The Primary impression of maxillary and mandibular arch were made with irreversible hydrocolloid material (Algitex) and was poured in dental stone(Kalstone) followed by the disinfection of both the impression and cast(fig.4 & fig.5). Undercuts were blocked out, custom tray was fabricated using auto-polymerizing resin (DPI-RR) and the extension was checked in patient's mouth. Later border-moulding procedure was performed with low fusing compound (DPI PINNACLE, Tracing Sticks,), then final impression was made using medium bodied addition silicone impression material and a wash impression was made. Final Impression was poured utilizing type IV die stone (NEW FUJIROCK). Jaw relations were recorded in patient's mouth and afterward complete try in was done.

Fabrication of One Piece Hollow Bulb Obturator

Entire defect area was relieved with one thickness of base plate wax which should follow the form of the deformity. Investing was done in the conventional flask followed by flasking and deflasking in the regular manner. Subsequent to cooling, separating medium was applied and packing of prosthesis was done in heat cure acrylic resin and placed it for short curing cycle. After finishing and polishing put salt, or pumice in the depression closer to the outer surface with the auto-polymerizing resin shim, prepared two bur holes on the shim of 0.5mm diameter to flush out the salt then bur hole were closed with auto-polymerizing resin. After finishing and polishing (fig 6) obturator prosthesis was inserted into the patient mouth.

Patient was instructed and educated for proper oral hygiene maintenance. During recall check upit showed greater improvement in deglutition, mastication, speech and it was found to be more comfortable due to weight reduction. Postoperative insertion adjustments were scheduled for 6 months at regular intervals of time.

Discussion

The COVID-19 pandemic introduced time-sensitive

challenges and issues that require developing new and rapid solutions as options in contrast to routine standard evidence-based protocols which require significant time and interactions between provider and patient.¹⁸⁻²¹

Maxillary deformities usually results in extreme limitations like patient's swallowing, speech and mastication. The deficiency of supporting structures may likewise cause considerable facial collapse(Fig 1 & Fig 2). Long-term prosthodontic treatment facilitates physical and psychological recovery and can reestablish some of the functions, aesthetics as well as comfort. In covid-19 pandemic situation it's a challenge for maxillofacial prosthodontist to rehabilitate them. Although each patient has a unique combination of problems, there are certain general rules that apply to the fabrication of most obturators in pandemic crisis.

This article depicts the construction of hollow obturator prosthesis. In addition to the usual discomfort in deglutition, patients with large maxillary defects have unique issues like they should continue nasal-gastric feeding until the palate can be closed either rehabilitation or by surgical reconstruction. Speech is usually unintelligible; the mucous, general nasal, sinus & oral fluids tend to dry and crust upon already tender tissues in the defect. An impression of the defect should be obtained as soon as the patient can tolerate the procedure.

The obturator have various functions including: reduces psychological impact of surgery, keeps the defective area clean, boost the healing of traumatic or postsurgical defects and also help to reshape or reconstruct the defect. It additionally improves or in some instances makes speech possible and correct lip and cheek position. It is used to improve impaired deglutition and mastication functions. It also decreases the passage of exudates into the mouth.²⁸

It is demonstrated that silicone prosthesis gives best outcome when used in function as it offers greatest potential for gaining retention from within the defect due to its flexible nature.²⁹ But in our case considering

the feasibility & ease of manipulation, economic status of the patient heat activated acrylic resin was selected to restore the defect.

The method described is easy, simple, time saving & economical. After insertion of prostheses mastication, deglutition and phonetics were improved. Breathing problems were resolved and aesthetics was improved. Bulb portion was hollow & made of heat cure resin, so weight was less & less chances of tissue irritation. Hence there was rebuilding the self confidence in patient.

Conclusion

A simplified technical approach for the treatment of a patient with palatal defect of and other supportive structure has been presented in Covid-19 situation following the described infection prevention protocols. The technique presented offers a method of obtaining a detailed impression of the defect and promptly provides the patient with a light weight, easy-to-use and flexible tissue- tolerant obturator. The procedure was carried out giving utmost importance to functional, psychological & aesthetic needs of the patient.

Source of fund: (if any): Nil

Conflict of interest: The authors declare that there is no conflicts of interests among them.

Ethical clearance: The study participant (Patient) was informed and a written informed consent for their willingness to publish the data was obtained.

Authors's contribution:

Data gathering and idea owner of this study: Anupama Aradya

Study design: Anupama Aradya, Sreeshyla H S

Data gathering: Anupama Aradya, Narahari Ranganatha

Writing and submitting manuscript: Anupama Aradya, Sreeshyla H S

Editing and approval of final draft: Anupama Aradya, Narahari Ranganatha, Sreeshyla H S

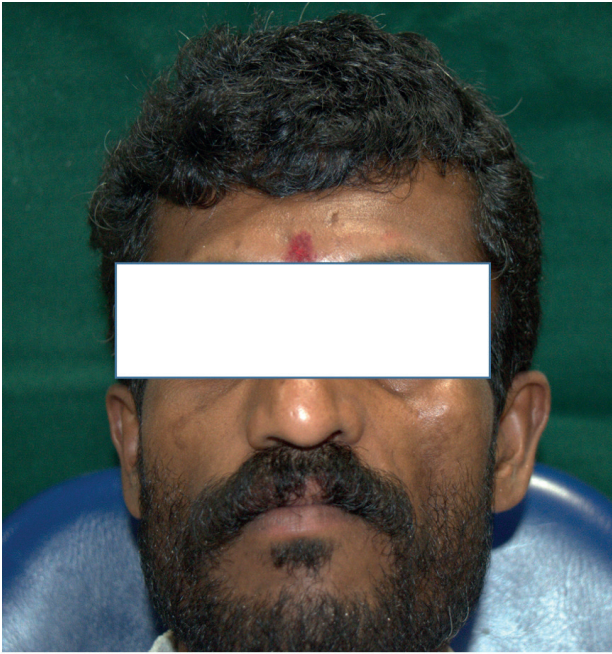

Figure.1-Pre operative image of face with facial deformity

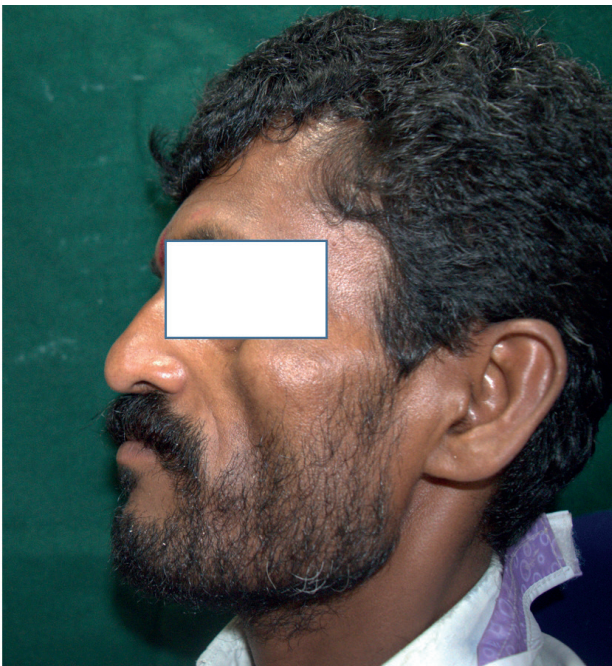

Figure.2-Preoperative image of left side face with facial deformity

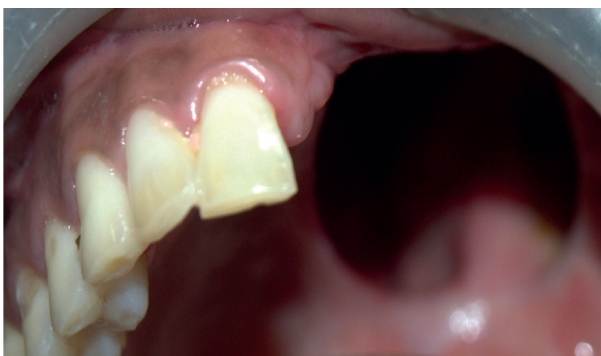

Figure.3-Intra oral defect

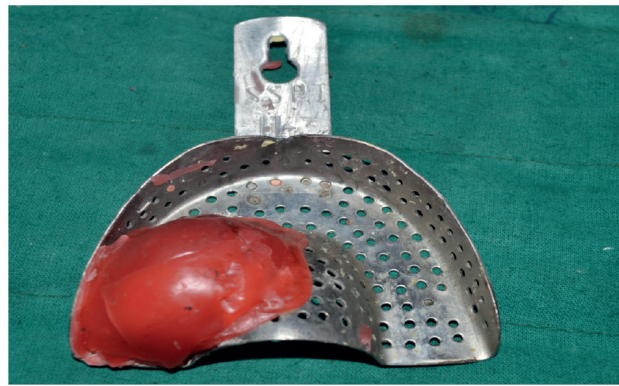


Figure.4- Stock tray modification before making impression

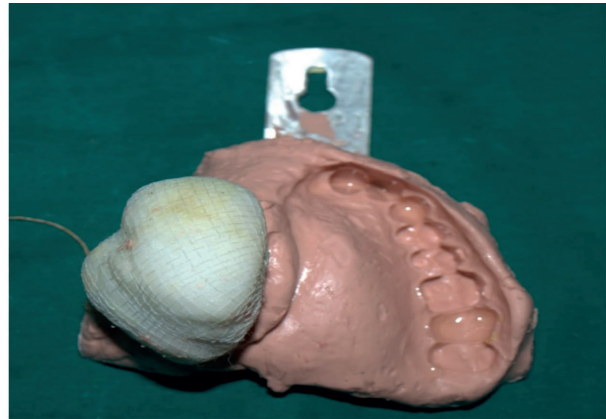


Figure.5- Maxillary primary impression

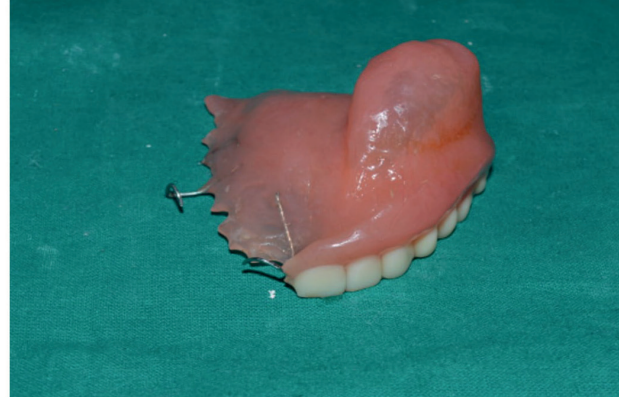


Figure.6-Maxillary definitive obturator

References

1. Ferlay J, Shin HR, Bray F, Forman D, Mathers C, et al. Estimates of worldwide burden of cancer in 2008. *Int J Cancer*.2010;**127**: 2893-2917. <https://doi.org/10.1002/ijc.25516>
2. Shaw RJ, Sutton AF, Cawood JI, Howell RA, Lowe D, et al. Oral rehabilitation after treatment for head and neck malignancy. *Head Neck*. 2005;**27**: 459-470. <https://doi.org/10.1002/hed.20176>
3. Nayar, S. Current concepts and novel techniques in the prosthodontics management of head and neck cancer patients. *British Dental Journal*.2019; **226**(10): 725-737 <https://doi.org/10.1038/s41415-019-0318-3>
4. Bast RC Jr, Kufe DW, Pollock RE, Weichselbaum RR, Holland JF, Frei E III (2000)Principles of cancer rehabilitation medicine. In: Holland-Frei Cancer Medicine.5th ed. Hamilton, Ontario: BC Decker Inc; 971-985.
5. Jinesh A Dugad I, Smita Athavale, Gunjan Chouksey and Ravish Tongya. Oral cancer rehabilitation: Requirement and responsibility of maxillofacial prosthodontist's (MFP's). *Surg Rehabil*.2017;**1**(4): 1-4. <https://doi.org/10.15761/SRJ.1000121>
6. Fernanda P, Daniela M, Lisiane CB, Clovis L, Marcelo CG. Classification, History, and Future Prospects of Maxillofacial Prosthesis. *International Journal of Dentistry*. 2019;**1**:1-8. <https://doi.org/10.1155/2019/8657619>
7. J. Irish, N. Sandhu, C. Simpson et al., "Quality of life in patients with maxillectomy prostheses. *Head Neck*.2009; **31**(6): 813-821. <https://doi.org/10.1002/hed.21042>
8. Dos Santos DM, de Caxias FP, Bitencourt SB, Turcio KH, Pesqueira AA, and Goiato MC. Oral rehabilitation of patients after maxillectomy: a systematic review. *British Journal of Oral and Maxillofacial Surgery*. 2018; **56**(4):256-266. <https://doi.org/10.1016/j.bjoms.2018.03.001>
9. Harley WT. Dynamic palatography-a study of linguopalatal contacts during the production of selected consonant sounds. *Journal of Prosthetic Dentistry*.1972;**27**(4):364-376. [https://doi.org/10.1016/0022-3913\(72\)90284-3](https://doi.org/10.1016/0022-3913(72)90284-3)
10. M. C. Goiato, A. A. Pesqueira, C. Ramos da Silva, H. G. Filho, D. Micheline dos Santos. Patient satisfaction with maxillofacial prosthesis. Literature review. *Journal of Plastic, Reconstructive & Aesthetic Surgery*.2009;**62** (2): 175-180. <https://doi.org/10.1016/j.bjps.2008.06.084>
11. M. C. Goiato, M. Miyashita, D. M. dos Santos et al., Radipherous prostheses, an alternative for the treatment of head and neck neoplasias. *Revista Cubana Estomatologia*.2006;**43**(2):1-5.
12. Diken Türksayar AA, Saglam SA, Bulut AC. Retention systems used in maxillofacial prostheses: A review. *Niger J Clin Pract*. 2019;**22**:1629-34. https://doi.org/10.4103/njcp.njcp_92_19
13. Sarke A, Gupta H, Sudan R and Singh R. An Update on Retentive Aids in Maxillofacial Rehabilitation. *Int J Com Health and Med Res*. 2018;**4**(1):32-36.
14. Kraeima, J., Glas, H. H., Merema, B. J., Vissink, A., Spijkervet, F. K. L., Witjes, M. J. H. (2020). Three dimensional virtual surgical planning in the oncologic treatment of the mandible - Current routines and clues for optimization. *Oral Diseases* (in press). <https://doi.org/10.1111/odi.13631>
15. Nathalie V, Jamie A, Max HJ, Gerry MR, Harry R, Arjan V et al., Prosthodontic rehabilitation of head and neck cancer patients :Challenges and new developments. *Oral Diseases*. 2021;**27**:64-72. <https://doi.org/10.1111/odi.13374>
16. Mahmoud E, Yuka S, Shajidan K et al. Application of Digital Technologies in Maxillofacial Prosthetics Literature: A 10-Year observation of five selected prosthodontics Journals. *Int J Prosthodont* 2019;**32**:45-50. <https://doi.org/10.11607/ijp.5932>
17. Ravish R, Jinesh A. Maxillofacial Prosthodontic Rehabilitation: A Survey On Head And Neck Surgeon's Attitude And Opinion. *Indian Journal Of Applied Research*. 2018;**8**(10):51-52.
18. Amir, S. H. ., Zafar, L. ., Siddiqui, O. A., & Nasreen, F. Challenges in managing an emergency and trauma ICU during COVID-19 pandemic: Perspective from a tertiary care centre in western Uttar Pradesh (India). *Bangladesh Journal of Medical Science* 2021; **20**(5):26-31. <https://doi.org/10.3329/bjms.v20i5.55397>
19. Hardcastle, T. C. ., Hollander, D. D. ., Ganchi, F. ., Naidoo, S. ., & Shangase, T. N. Management Issues with Infection Control during Trauma Resuscitation in the Era of COVID-19: South African Experience. *Bangladesh Journal of Medical Science* 2021; **20**(5): 72-76. <https://doi.org/10.3329/bjms.v20i5.55410>
20. Perrone, G., Giuffrida, M., Bonati, E., Rio, P. D., Pattonieri, V., Tarasconi, A., Coccolini, F., Sartelli, M., Ansaloni, L., & Catena, F. Emergency Surgery in A Tertiary Hospital: The Covid-19 Experience. *Bangladesh Journal of Medical Science* 2020; **19**: 66-68. <https://doi.org/10.3329/bjms.v19i0.48168>
21. Zainun, Z., Suhaimee, H., Mohamad, I., & Hadi, A. A. Removal of Aural Tick in a General Practitioner Setting During COVID-19 Lockdown. *Bangladesh Journal of Medical Science* 2020; **19**: 82-84. <https://doi.org/10.3329/bjms.v19i0.48171>
22. Kowalski LP, Sanabria A, Ridge JA, Ng WT, Bree R, Rinaldo A et al., COVID-19 pandemic: effects and evidence

- based recommendations for otolaryngology and head and neck surgery practice. *Head Neck*.2020; **42**:1259-1267. <https://doi.org/10.1002/hed.26164>
23. Kampf G, Todt D, Pfaender S, Steinmann E. Persistence of coronaviruses on inanimate surfaces and their inactivation with biocidal agents. *J Hosp Infect*.2020; **104**:246-251. <https://doi.org/10.1016/j.jhin.2020.01.022>
24. Acharya V, Chambers MS (2015) Maxillofacial prosthodontic rehabilitation of a patient with oral complications during and after multimodality therapy for the management of oral squamous cell carcinoma. *J Prosthet Dent*. 2014; **113**:651-655. <https://doi.org/10.1016/j.prosdent.2014.12.010>
25. Ignatius E, Perälä S, Mäkelä K. Use of videoconferencing for consultation in dental prosthetics and oral rehabilitation. *J Telemed Telecare*. 2010; **16**:467-470. <https://doi.org/10.1258/jtt.2010.100303>
26. Desjardins R.P. Obturator prosthesis design for acquired maxillary defects. *J Prosthet Dent* 1978; **39**: 424. [https://doi.org/10.1016/S0022-3913\(78\)80161-9](https://doi.org/10.1016/S0022-3913(78)80161-9)
27. Brandão TB, Migliorati CA, Vechiato-Filho AJ, Silva WG, Ana Carolina PR & Orlando PJ et al., Strategic use of obturator prostheses for the rehabilitation of oral cancer patients during the COVID-19 pandemic. *Supportive Care in Cancer*. August. 2002; **2**:1-5
28. Aramany M.A: Basic principles of obturator design for partially edentulous patients. Part I : Classification. *J Prosthet Dent*.1978; **40**:351. [https://doi.org/10.1016/0022-3913\(78\)90092-6](https://doi.org/10.1016/0022-3913(78)90092-6)
29. Russell R. Wang - Refilling hollow obturator base using light activated resin. *J Prosthet Dent*.1997; **78**:327. [https://doi.org/10.1016/S0022-3913\(97\)70035-0](https://doi.org/10.1016/S0022-3913(97)70035-0)
-