

Gap closure in missing lateral incisors comparing the use of mesialising canines and prosthetic implants: A Systematic Review

Sherif Elsayed Sultan ¹, Amal Abdallah Abo-Elmagd ², Noha Mohamed ³, Mohammed Fawaz Alhabbad ⁴, Basil Abdulaziz Alhassan ⁵, Fawaz Talal Alanazi ⁶, Mohammed Khursheed Alam ⁷

ABSTRACT

Background

The most prevalent form of birth defect is hypodontia, or the lack of teeth. Patients who suffer from agenesis of the maxillary lateral incisors worry about how their new teeth and face will look after therapy. The main purpose of orthodontic treatment, known as gap closure, is to preserve as many teeth as possible. The two most important methods regarding gap closure are mesialising canines and prosthetic implants.

Objective

Mesialising canines and prosthetic implants for lateral maxillary incisor gap closure are the subjects of this systematic study.

Methodology

In addition to using a systematic search technique on Google Scholar, PUBMED, and the Web of Science, we formally included or excluded studies, extracted data, assessed validity, and evaluated quality. A systematic review was conducted on all of the studies. In order to evaluate the quality, the Cochrane risk of bias tool was utilized.

Results

According to our set inclusion criteria, 11 most relevant studies were found in the databases. Data was extracted from each study separately in an Excel Sheet. All studies mentioned discussed the use of the two best potential treatments, their advantages and disadvantages, and the parameters determining the best treatment.

Conclusion

Although prosthetic implants did enhance a few metrics, this comprehensive study did not find a statistically significant difference between the two treatments. The comparative efficacy of two methods for closing the space left by removing maxillary lateral incisors requires more study.

Keywords

Hypodontia; Maxillary lateral incisors; Orthodontic treatment; Mesialising canines; Prosthetic implants

INTRODUCTION

Hypodontia is the most prevalent kind of dental malformation in children. A condition known as hypodontia occurs when a tooth or teeth are not present at birth. The reported prevalence of hypodontia, excluding third molars, ranges from 1.6% to 6.9% ¹, depending on the community under observation. There are distinct agenesis patterns in permanent dentition, however the

1. Sherif Elsayed Sultan, Assistant Professor, Department of Prosthetic Dental Sciences, Jouf University, Sakaka, KSA. sesoltan@ju.edu.sa
2. Amal Abdallah Abo-Elmagd Prosthodontics department, college of dentistry, Qassim University, KSA, Fixed Prosthodontics department, faculty of dental surgery, MUST University, Egypt a.aboelmagd@qu.edu.sa, amal.abdallah4660@gmail.com
3. Noha Mohamed, Phd fixed Prosthodontics, Egypt. nohamo7ammad@hotmail.com
4. Mohammed Fawaz Alhabbad, Faculty of Dentistry, Jouf University, Sakakah, KSA.
5. Basil Abdulaziz Alhassan, Faculty of Dentistry, Jouf University, Sakakah, KSA basil.alhasan@jodent.org
6. Fawaz Talal Alanazi, Faculty of Dentistry, Jouf University, Sakakah, KSA Fawaz.talal@jodent.org
7. Mohammed Khursheed Alam, Preventive Dentistry Department, College of Dentistry, Jouf University, Sakaka 72345, Saudi Arabia. mklam@ju.edu.sa, & Department of Dental Research Cell, Saveetha Institute of Medical and Technical Sciences, Saveetha Dental College and Hospitals, Chennai 600077, India & Department of Public Health, Faculty of Allied Health Sciences, Daffodil International University, Dhaka 1207, Bangladesh.

Correspondence

Sherif Elsayed Sultan, Assistant Professor, Department of Prosthetic Dental Sciences, Jouf University, Sakaka, KSA. sesoltan@ju.edu.sa & Mohammed Khursheed Alam, mklam@ju.edu.sa

frequency of tooth loss can vary greatly depending on variables including dentition, gender, and demographic or geographical factors ². When it comes to missing teeth at birth, maxillary lateral incisors are the most common. ³. Agenesis of the maxillary lateral incisors is rather common, with a frequency incidence ranging from 1.9% to 4.9% ⁴. The present research indicates that MLIA is more prevalent in bilateral than unilateral cases, and that its prevalence rate is higher in females than men in the general population ^{5,6}. The effects of dental agenesis on facial and dental aesthetics are substantial. Asymmetry of the face, irregularities in the midline deviation, and problems with the dental arches are symptoms reported by patients with MLIA ⁷. Because of their asymmetry and imbalance, they have trouble swallowing and expressing themselves verbally, which causes social and psychological difficulties ⁸. A multidisciplinary team will be needed to treat these lost teeth. Treatment methods for MLIA range from space closure with a mesializing canine and tooth recontouring to space opening and prosthetic implant replacement of lost maxillary incisors ⁹. Each patient's expectations and distinctive dental and facial characteristics must be carefully considered in order to develop an effective treatment plan ¹⁰. However, while deciding on a course of treatment, the main objective is to preserve the tooth as much as possible by going with the least intrusive method while still achieving the desired cosmetic results ¹¹. This study examines the aesthetic and functional aspects of patients with maxillofacial misalignment (MLIA) who had implant treatment, gap closure, or tooth recontouring in an effort to determine the significance of an interdisciplinary approach to achieving optimal dental aesthetics.

RATIONALE

Although the use of prosthetic implants and mesialising canines has been evaluated in current literature, there has reportedly been limited data on the comparison of the two treatment options available or discussing the interdisciplinary approach considering the facial and functional dental aesthetics in patients with congenitally missing maxillary lateral incisors. There are several consequences of leaving the MLIA untreated; physical and psychological consequences including problems related to chewing, voice articulation, other concerning facial aesthetics, and low self-esteem. The goal of modern dentistry is to choose the least invasive treatment option for maximum tooth conservation. This study

attempts to critically discuss both treatment options and compare the efficacy of the different treatment options based on the above-mentioned parameters.

OBJECTIVE

1)To evaluate and compare the efficacy of mesialising canines and advanced surgical prosthetic implants in orthodontic gap closure. 2)To utilize the minimally invasive option in gap closure for restoring dental and facial aesthetic and tooth conservation. 3)To discuss the potential limitations and disadvantages of given treatment options to help clinicians choose the best treatment option available. This systematic review aims to highlight the best treatment choice available according to an individual's needs.

METHODS

According to the Preferred Reporting Items for Systematic Review and Meta-Analyses (PRISMA) [12], study eligibility was determined using the PICOS framework, which stands for Population, Intervention, Comparison, Outcome, and Study Design. The table below (Table 1.0) lists the inclusion and exclusion criteria.

Criteria	Inclusion	Exclusion
1. Language	English	All other languages
2. Timeframe of publications	2000-2024	Older
3. Type of Studies	Observational studies, In vivo studies, Randomized Control Trials	Perspective Reviews Grey literature
4. Region	All	
5. Target Population	Patients with missing maxillary lateral incisors	Patients with infections of the supporting structure of the teeth
6. Context	Evaluation of the efficacy of mesialising canines and prosthetic implants in orthodontic gap closure.	Other surgical or non-surgical interventions.

INCLUSION CRITERIA

The inclusion criteria were as follows: 1) peer-reviewed studies comparing the use of mesialising canines with prosthetic implants in orthodontic gap closure. 2) Studies that were published from 2000 to 2024. 3) Studies with abstracts and free full-texts available were

selected. 4) Language specifications were made in this study. 5) Retrospective and Prospective cohort studies were included in this study.

Exclusion Criteria

The exclusion criteria were as follows: 1) All studies published before 200 were excluded. 2) Patients with infections of surrounding supporting structures of the teeth were eliminated. 3) Study designs such as narrative reviews were not included. 4) No other language other than English was included. 5) Studies, especially randomized control trials with “High Risk” of bias.

Search Strategy

In order to fill this gap, we looked through a number of databases for articles that discussed prosthetic implants, mesializing canines, or compared the two. Among these, you may find the ACM Digital Library, Cochrane, Google Scholar, and PubMed. There were print publications in addition to online databases that served as literary sources. For the search technique, the Boolean operators AND and OR were utilized. In order to narrow the search for articles, many filters were used.

Data extraction

This systematic review followed the guidelines laid out by PRISMA, the Preferred Reporting Items for Systematic Reviews and Meta-Analyses. The technique included a comprehensive search of many electronic databases, such as PubMed, Web of Science, Science Direct, and the Cochrane Library. The studies that were found mostly dealt with the topic of gap closure and the many treatment methods that are accessible, such as prosthetic implants or mesializing canines. These terms were part of the search tool’s vocabulary. There were a total of 33 studies that met the inclusion criteria. These studies included topics such as: (“Gap closure” OR “Tooth replacement”); (“Missing lateral incisors” OR “Lateral incisor restoration”); (“Mesialising canines” OR “Canine substitution”); and (“Prosthetic implants” OR “Dental implants”). In addition, we checked the papers’ reference lists that were chosen for the systematic review. In order to consider include certain papers in this evaluation, a list was created. In preparation for the second round of screening, all articles were read in their entirety. After a comprehensive screening of all eligible papers, a standard data extraction table was created. This table includes details such as the first author, publication year, study design, country, setting, sample size, sampling technique, instrument, standard errors

and standard deviations, and related factors.

Selection Process

Researchers searched for relevant articles in scholarly journals and other published works that met the inclusion criteria they had established. To further investigate the likelihood of publication bias, we turned to peer-reviewed publications that had a high impact factor. All articles were uploaded on Rayyan AI [13], for primary and secondary screening. To prevent any foreseeable outcomes, the first step was to detect any duplicate trials. A total of $n=478$ articles were detected as duplicates and removed from the original literature search. $n=212$ articles were marked ineligible by the automation tools, A total of $n=278$ articles were deemed eligible for primary screening. By the inclusion and exclusion criteria, a group of researchers collaborated to “include” and “exclude” the studies, and a total of $n=122$ studies were considered for final review and analyses. We excluded the studies due to a variety of reasons. 1) The study design was not ideal for analysis, 2) The study did not have the preferred outcome, and 3) The study showed a potential risk of bias. Sometimes it could be due to the combined effect of all these reasons.

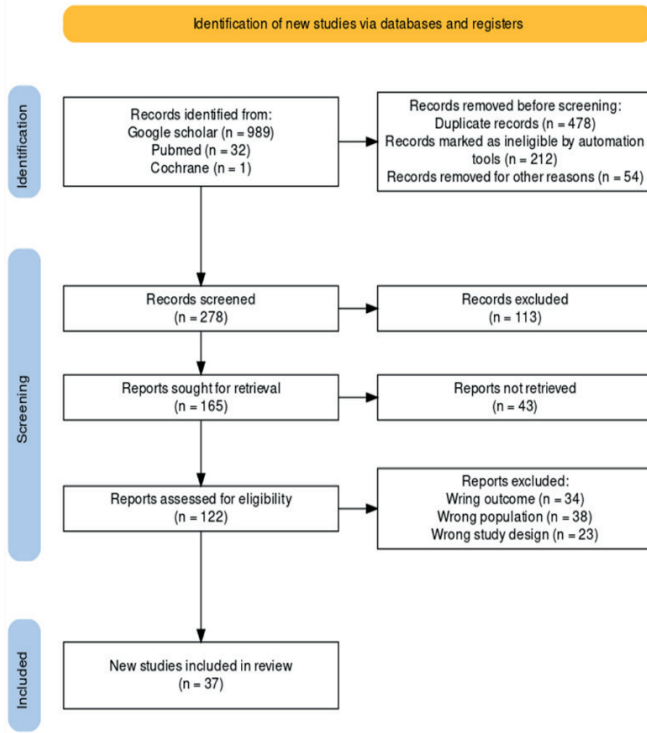
RESULTS

Data Items

After the secondary screening was finished, all fifteen articles from the chosen literature were carefully reviewed. According to the PRISMA principles, researchers took certain steps to produce a PRISMA Flow Diagram [12]. The research selection procedure is illustrated in Figure 1.0. It involves identifying, screening, and include studies from journals and other independent resources according to report availability.

Once each study segment was finished, the study interventions were tallied against their respective research populations and outcomes. Just the most important takeaways from the results are listed in the synthesis table.

One way that bias in the analysis was reduced was by 1) doing a literature review to pick high-quality studies. 2) mandating the disclosure of potential conflicts of interest in peer reviews. 3) removing bias from clinical research and practice by implementing a system of peer review and informed consent swapped out for standard review pieces. 5) Systematic reviews and narrative reviews were often omitted from the literature in order



“Prisma Flow Chart of included studies:

to uphold the study’s standards. The following steps for detecting and eliminating publication bias in research protocols are based on those outlined by Dickersin (1997).

RESULTS

The final sample for the systematic review included 11 peer-reviewed studies. All studies included were observational studies. Among the observational studies, there were 2 Case reports, 1 Cross-sectional study, and 8 studies were cohorts which included both retrospective and prospective cohort studies. Sample size ranged from N=1 to as large as N=486. According to ¹⁴, in a cross-sectional study conducted in Sweden, 44 patients were allocated to the two treatment groups. Among these treatment groups, implant group 1 included 22 patients all aged under 26 years old who had one or both MLIA, Patients matched with patients in the I group according to diagnosis, gender, and quantity made up the space-closure group. In the clinical evaluation of the 44 patients, the aesthetics and gingival conditions of the replacement canine and the implant-supported crown were assessed. The examiner discovered that out of the twelve variables evaluated, one yielded considerably

better outcomes in Group 1, whereas five factors yielded significantly better results in the space closure group. In the other six groups, there was no discernible change in clinical outcomes. France was the site of a retrospective study that looked at 486 patients who had maxillary lateral agenesis, either one side or both ¹⁵. In patients lacking maxillary lateral incisors on one or both sides, this study indicated that prosthetic gap replacement resulted in better final dental arch relationships (59.8% improvement) and dental arch symmetry (88.1 percent improvement) than orthodontic gap closure (10.3% improvement) and orthodontic gap treatment (44.0 percent improvement), respectively. In conclusion, prosthetic implants were found to have significantly better outcomes as compared to the orthodontic gap closure. A retrospective cohort study by Rosa *et al.* (2017) evaluates the closure of maxillary lateral incisors and potential periodontic infections ¹⁶. In this study, 26 participants were treated with space closure and results were compared with the control group which had no absence of teeth. There was no statistically significant difference found between the experimental and control groups. There was no occurrence of periodontal tissue deterioration and increased risk of infections in patients who underwent orthodontic gap closure. In Schneider-Moser *et al.* (2016), the posttreatment intraoral photographs after undergoing canine substitution and prosthetic implants were compared for outcomes, and highly significant improvements were found in esthetic outcomes of patients who underwent implants ¹⁷.

According to Walter *et al.* (2023), 24 patients who received implants were followed up for esthetic outcomes to evaluate the implant survival after 12 months ¹⁸. The esthetic outcome was calculated using a pink esthetic score. With a 95% confidence interval of 10.5 to 11.9, the mean pink aesthetic score at 6 months was 11.2. A different research, Lacarbonara *et al.* (2021) ¹⁹, also included three patients in their investigation. Patients underwent surgical implant placement, and many metrics were employed to assess the implants’ and the orthodontics’ post-implant health. There were seven cases of bleeding after one month, six cases after one year, five cases after five years, and five cases after 10 years, representing 16.6%, 20%, and 11.9% of incidents, respectively. No other statistically significant difference was found in the parameters taken into consideration. Rocuzzo *et al.* (2022) also demonstrated the survival rate of implants, where 100 patients with dental implants were included ²¹. In the case report mentioned in the synthesis table by ²², a

Data characteristics:

Sr.	Study Id.	Location	Study Design	Participants	Evidence obtained through	Results
1	Josefsson and Lindsten (2018) [14]	Sweden	Cross sectional Study	22 of 44 patients were treated with implant placement and 22 were treated with space closure	Clinical examination	Of the 12 variables analyzed by the examiner, there were significant improvements in 1 variable in the I group and 5 variables in the SC group.
2	Quenel <i>et al.</i> (2022) [15]	France	Retrospective Cohort study	n=486 patients, including 212 patients with unilateral or bilateral missing maxillary lateral incisors	Intraoral photographs	prosthetic replacement of the gap was associated with better final dental arch relationships (59.8 percent versus 10.3 percent; $p < 0.01$) and better dental arch symmetry (88.1 percent versus 44.0 percent; $p < 0.01$)
3	Rosa <i>et al.</i> (2017). [16]	France	Retrospective Cohort study	The agenesis group included 26 patients (9 male, 17 female) treated with space closure.	survey based protocol	No clinically significant difference was found between the experimental and control group regarding the increased risk of periodontic infections with canine substitution.
4	Schneider-Moser <i>et al.</i> (2016) [17]	Italy	Cohort study	A series of 9 posttreatment intraoral frontal photographs were evaluated	Intraoral photographs	Highly significant improvements ($P < 0.0001$) in the esthetic outcome for implants were found in all respondent groups when compared with the study from 2005.
5	Walter <i>et al.</i> (2023) [18]	Germany	Prospective Cohort	Twenty-four males and 17 females with a mean age of 44.5 (± 18.3 standard deviation) received the implant.	Pink esthetic score	Three out of 41 implants were lost yielding a survival rate of 92.7% (95%-CI: 79.0%; 97.6%) at 1 year.
6	Lacarbonara <i>et al.</i> (2021) [19]	Italy	Prospective Cohort	A total of 30 patients treated with mini-implants were included in this analysis.	Intraoral photographs	there were no statistically significant differences between the parameters taken into consideration
7	Stabryła <i>et al.</i> (2021) [20]	Poland	Retrospective Cohort	Eighty-five patients (83%) with 97 impacted canines started the treatment.	Panoramic radiograph	Treatment was successful for 87 canines (96%) in 79 patients who started the therapy. Orthodontic extrusion failed in 3 patients with 3 impacted maxillary canines (4.6% of all the impacted maxillary canines).

Sr.	Study Id.	Location	Study Design	Participants	Evidence obtained through	Results
8	Rocuzzo <i>et al.</i> (2022)[21]	Denmark	Prospective Cohort	One hundred patients rehabilitated with dental implants Ø2.9 mm (n = 50) or Ø3.3 mm (n = 50) were included		no statistically significant difference between the two groups (p = 1.000; 95% CI: 94.6%–99.9%).
9	Gupta and Rauniyar (2020) [22]	Nepal	Case Report	A 22-year-old patient with maxillary lateral incisor agensis	intraoral photographs	The posttreatment facial photographs exhibited a remarkable improvement of facial esthetics. The patient's smile was improved.
10	Robertsson and Mohlin (2000)[23]	Sweden	Retrospective study	Fifty patients were identified. 30 had been treated with orthodontic space closure and 20 by opening and prosthesis.	Eastman aesthetic index questionnaire,	It was concluded that orthodontic space closure produced better results than prosthetic implants
11	Vignon <i>et al.</i> (2023) [24]	France	Case Report	A woman about 30 years old, with no systematic health issues and non-smoker, came with congenital missing lateral incisors.	Intraoral photographs	patient complete satisfaction was achieved using orthodontic treatment combined with implant rehabilitation, and coupled with interdisciplinary management and well-time sequencing treatment.”

22-year-old patient with MLIA underwent orthodontic gap closure, and her dental and facial aesthetic progress was monitored with intraoral photographs, which significant improvement over a few months.

Quality Assessment:

-for systematic review: The studies that were chosen for the quality assessment were all checked for bias in the publication process. Data on interventions, populations, and outcomes were all double-checked in each study. Using the Critical Appraisal Skills Programme (CASP) instrument, all research that met the criteria for inclusion in the study were chosen privately. It was stated by Page *et al.* in 2021. The risk of bias algorithm evaluated three areas of possible bias in accordance with the CASP protocol. First, we made sure to only include studies that met high standards of quality and conduct a comprehensive literature review. Second, we did away with the double standard that exists when it comes to clinical research and informed consent, and third, we made sure that peer reviewers publicly declared any conflicts of interest they may

have. According to the study's guidelines, narrative reviews and systematic reviews were often left out of the literature. In accordance with the steps outlined by Chalmers *et al.* (1990) for eliminating publication bias, these recommendations identify and eliminate bias from the research process. The quality assessment included three broad categories of questions: ¹ Were the study results validated? ² What were the results? ³ Are the results of the study applicable locally? 11 questions for quality assessment were answered with careful consideration of study designs and the relevant outcomes. The responses to the questions were “Yes,” “No,” and “Can't tell.” If the first question is answered in the affirmative, it makes logical sense to move on to the other inquiries. The questions overlap each other in certain ways. The description of the answers and researchers' remarks has also been mentioned in the assessment table (See results section).

CASP Assessment:

To recap, all of the main studies included in the meta-analysis had their risk assessed using the CASP technique.

To generate a quality assessment table for each study in the final sample, we utilized the Critical Appraisal Skills Programme (CASP) tool [35]. The assessment table for 8 primary studies is mentioned below:

DISCUSSION:

In the field of dentistry, a comparison between prosthetic implants and mesialising canines for gap closure in lateral incisor loss is a topic of major significance. Both approaches have advantages and disadvantages, as the literature that is now accessible demonstrates. This results in a comprehensive evaluation of the strengths and practicality of each approach. For patients suffering from hypodontia of the lateral maxillary incisors, there are two potential treatments: either opening the space

for a prosthetic repair or implant placement and closure, or replacing the space with canines⁹. When it comes to maxillary anterior region oral rehabilitation, aesthetics are paramount. In the above-mentioned studies, every maximum effort was made to maximize the esthetics to improve functional and facial parameters discussed in the literature.

According to Millar and Taylor (1995) The alignment issues, the connection in the front, specific space needs, and the condition of adjacent teeth collectively influence the choice of the most suitable treatment method²⁵. In the functional and facial dental aesthetics were assessed of the implant-supported and replacement canines. Patients with MLIA have issues related to their appearance and lack of self-confidence and certain

Column1	Questions	Josefsson and Lindsten (2018)	Quenel <i>et al.</i> (2022)	Rosa <i>et al.</i> (2017)	Schneider-Moser <i>et al.</i> (2016)	Walter <i>et al.</i> (2023)	Lacarbonara <i>et al.</i> (2021)	Stabryla <i>et al.</i> (2021)	Rocuzzo <i>et al.</i> (2022)	Robertsson and Mohlin (2000)	Vignon <i>et al.</i> (2023)	Gupta and Ranjumar (2020)
1	Did the study address a clearly focused issue?	Y	Y	Y	Y	Y	Y	Y	Y	Y	Y	Y
2	Did the authors use an appropriate method to answer their question?	Y	N	Y	Y	Y	Y	Y	Y	Y	Y	Y
3	Were the cases recruited in an acceptable way?	Y	Y	?	Y	?	?	Y	Y	Y	Y	?
4	Were the controls selected in an acceptable way?	Y	Y	Y	Y	N	Y	Y	?	Y	Y	Y
5	Was the exposure accurately measured to minimize bias?	Y	Y	N	N	Y	Y	N	N	Y	Y	Y
6 (a)	Aside from the experimental intervention, were the groups treated equally?	Y	N	Y	Y	Y	?	?	?	?	Y	Y
6 (b)	Have the authors taken account of the potential confounding factors?	?	Y	N	Y	Y	Y	N	N	Y	?	N
8	Is the model validated?	Y	Y	Y	Y	Y	Y	Y	Y	Y	Y	?
9	Do you believe the results?	Y	Y	Y	Y	Y	Y	Y	Y	Y	Y	Y
10	Can the results be applied to the local population?	N	Y	Y	N	N	N	?	Y	N	Y	Y
11	Do the results of this study fit with other available evidence?	Y	?	N	Y	Y	N	Y	N	Y	Y	Y
	SCORE OUT OF 11	9	8	7	9	8	7	7	7	9	10	8

psychological issues related to their facial aesthetics²⁶. This evidence was supported by the study mentioned [14], which also assessed the appearance while smiling along with the assessment of other gingival conditions. This study demonstrated better results with implant-supported crowns as compared to the canine substitution. The main goals of the study by Schneider-Moser *et al.* (2016) were to compare the results with a 2005 study in the US and to determine how a group of experts in orthodontics, dentistry, and general public viewed the aesthetic quality of dentitions after canine substitution for orthodontic space closure compared to space opening and implant-borne crowns for missing maxillary lateral incisors¹⁷.

Nine intraoral frontal photographs taken after treatment were shown to 87 orthodontists and 100 general dentists. In both studies, prosthetic rehabilitation was found to have better dental arch symmetry and dental arch relationships^{14,15}. The case reports and one retrospective study mentioned that Orthodontic gap closure with mesialising canines proved to be a better alternative treatment option than prosthetic implantation^{7,24}. Gap closure by canine substitution provides a permanent treatment and eliminates the need for long-term temporary restorations and long-term maintenance required for prosthetic implant placement²⁷. The downsides of canine substitution include the need to remove tooth structure from the canine and first premolar, which might lead to further expenses if cosmetic bonding is needed to improve the canines' appearance. Research and clinical studies are crucial to evaluate each approach's potential consequences, patient satisfaction, and longevity. This study demonstrates through various retrospective, prospective cohorts and case reports that overall both treatment options serve best depending on each individual's need.

Patient satisfaction after Implant prosthesis:

Implant placement in conjunction with resin-bonded fixed dental prosthesis is one of the best ways to achieve ideal occlusion^{28,29}.

In a study², the prosthetic implants demonstrated significantly better results according to the parameters considered, i.e. the dental arch symmetry and its relationships. A lot of these factors were improved with implant prosthesis as compared to the canine

mesialisation. This indicates certain advantages regarding patient satisfaction with implants over mesialising canines. However, the clinical examining the teeth over using intraoral photographs makes this study less reliable. It is also however different to achieve dental aesthetics while mesialising canines due to differences in the color of the tooth, shape, and other characteristics. Implant prosthesis is also preferable because it provides longevity of the treatment and prevents the incidence of recurrent treatment.

Patient satisfaction after canine mesialisation:

According to Jamilian *et al.* (2015), adolescents and young adults preferably go for orthodontic space closure with canine substitution because it doesn't require waiting until the end of the growth period as in the case of implant prosthesis³⁰. An advantage of this is that the adolescent will complete the treatment at an early stage and that would help the teeth to appear more natural by the time of complete development and growth³¹. Periodontal conditions are found to be relatively better with canine substitution than other available treatment options. Patients after orthodontic space closure demonstrated better patient satisfaction factors as evaluated by the Eastman Aesthetic Index than those with prosthetic implants. Between the two sets of data, a statistically significant difference was seen¹⁰. This study also discussed several other parameters along with facial aesthetics including, gingival conditions, appearance of the smile and the incidence and prevalence of Temporomandibular joint disorders and orthodontic treatment showed better results in all the discussed parameters.

Limitations:

The limitations of this study are that the several studies mentioned in the synthesis table have a small number of patients. This study can't be applied to a larger number of population. The population demographics were not given any consideration. There was no sufficient literature on the comparison of both treatment options rather both were discussed in different retrospective studies respectively. It is proven that age and gender can significantly alter the results of the final analysis.

CONCLUSION

This study aimed to determine the best possible treatment

option available with evidence among the mesialising canines and the use of prosthetic implantation in missing maxillary lateral incisors by assessing studies that evaluated the dental, facial, and periodontal aesthetics. The majority of these studies demonstrated significant improvements in the mentioned parameters with orthodontic space closure than the prosthetic implants. To sum up, orthodontic space closure with canine substitution scores higher on measures of patient happiness and oral health. A trust relationship between the patient and physician is proved to be beneficial when selecting the best treatment option. According to the given stats, when possible, orthodontic space

closure should be recommended.

CONFLICT INTERESTS

The author states that there is no conflict of interest.

Funding

The author states that they do not have a source of funding.

AUTHOR'S CONTRIBUTION

All authors contributed to the writing of this systematic review article.

REFERENCES

- Al-Ani AH, Antoun J, Thomson WM, Merriman TR, Farella M. Hypodontia: An update on its etiology, classification, and clinical management. *BioMed Research International [Internet]*. 2017 Jan **1**;2017:1–9. Available from: <https://doi.org/10.1155/2017/9378325>
- De Coster PJ, Marks L, Martens L, Huyseune A. Dental agenesis: genetic and clinical perspectives. *Journal of Oral Pathology & Medicine [Internet]*. 2008 Dec **23**;38(1):1–17. Available from: <https://doi.org/10.1111/j.1600-0714.2008.00699.x>
- Gupta SPS, Rauniyar S. Orthodontic space closure of a missing maxillary lateral incisor followed by canine lateralization. *Case Reports in Dentistry [Internet]*. 2020 Nov **14**;2020:1–7. Available from: <https://doi.org/10.1155/2020/8820711>
- Chafi I. The Maxillary Lateral Incisor Agenesis: A case report and a literature review. *Advances in Dentistry & Oral Health [Internet]*. 2020 Oct **22**;13(3). Available from: <https://juniperpublishers.com/adoh/ADOH.MS.ID.555861.php>
- Polder BJ, Hof M a. V, Van Der Linden FPGM, Kuijpers-Jagtman AM. A meta-analysis of the prevalence of dental agenesis of permanent teeth. *Community Dentistry and Oral Epidemiology [Internet]*. 2004 May **19**;32(3):217–26. Available from: <https://doi.org/10.1111/j.1600-0528.2004.00158.x>
- Fekonja A. Hypodontia in orthodontically treated children. *European Journal of Orthodontics [Internet]*. 2005 Jul **25**;27(5):457–60. Available from: <https://doi.org/10.1093/ejo/cji027>
- Robertsson S, Mohlin B. The congenitally missing upper lateral incisor. A retrospective study of orthodontic space closure versus restorative treatment. *European Journal of Orthodontics [Internet]*. 2000 Dec **1**;22(6):697–710. Available from: <https://doi.org/10.1093/ejo/22.6.697>
- Proff P, Will F, Bokan I, Fanghänel J, Gedrange T. Cranial base features in skeletal class III patients. *Angle Orthodontist [Internet]*. 2008 May **1**;78(3):433–9. Available from: <https://doi.org/10.2319/013007-48.1>
- Kinzer GA, Kokich VO. Managing congenitally missing lateral incisors. Part III: Single-Tooth implants. *Journal of Esthetic and Restorative Dentistry [Internet]*. 2005 Jul **1**;17(4):202–10. Available from: <https://doi.org/10.1111/j.1708-8240.2005.tb00116.x>
- Al-Anezi SA. Orthodontic treatment for a patient with hypodontia involving the maxillary lateral incisors. *American Journal of Orthodontics and Dentofacial Orthopedics [Internet]*. 2011 May **1**;139(5):690–7. Available from: <https://doi.org/10.1016/j.ajodo.2009.10.042>

11. Pinho T, Lemos C. Dental repercussions of maxillary lateral incisor agenesis. *European Journal of Orthodontics [Internet]*. 2011 Aug 2;**34**(6):698–703. Available from: <https://doi.org/10.1093/ejo/cjr084>
12. Page MJ, McKenzie JE, Bossuyt PM, Boutron I, Hoffmann T, Mulrow CD, *et al*. The PRISMA 2020 statement: an updated guideline for reporting systematic reviews. *The BMJ [Internet]*. 2021 Mar 29;n71. Available from: <https://doi.org/10.1136/bmj.n71>
13. Ouzzani M, Hammady HM, Fedorowicz Z, Elmagarmid AK. Rayyan—a web and mobile app for systematic reviews. *Systematic Reviews [Internet]*. 2016 Dec 1;**5**(1). Available from: <https://doi.org/10.1186/s13643-016-0384-4>
14. Josefsson E, Lindsten R. Treatment of missing maxillary lateral incisors: a clinical and aesthetic evaluation. *European Journal of Orthodontics [Internet]*. 2018 Sep 11;**41**(3):273–8. Available from: <https://doi.org/10.1093/ejo/cjy061>
15. Quenel L, Keribin P, Durand T, Salagnac JM, Perrin JP, Delaire J, *et al*. Impact of Orthodontic Gap Closure versus Prosthetic Replacement of Missing Maxillary Lateral Incisor on Dental Arch Relationships and Symmetry in 212 Patients with Cleft Palate: Retrospective Study. *Plastic and Reconstructive Surgery [Internet]*. 2022 Jul 1;**150**(3):613e–24e. Available from: <https://doi.org/10.1097/prs.00000000000009477>
16. Rosa M, Lucchi P, Ferrari S, Zachrisson BU, Caprioglio A. Agénésie congénitale des incisives latérales maxillaires : évaluation parodontale et fonctionnelle à long terme après fermeture orthodontique de l'espace avec ingression de la première prémolaire et égression de la canine. *L'Orthodontie Française [Internet]*. 2017 Dec 1;**88**(4):319–32. Available from: <https://doi.org/10.1051/orthodfr/2017022>
17. Schneider-Moser U, Moser L, Fornasetti M, Piattella M, Siciliani G. Esthetic evaluation of implants vs canine substitution in patients with congenitally missing maxillary lateral incisors: Are there any new insights? *American Journal of Orthodontics and Dentofacial Orthopedics [Internet]*. 2016 Sep 1;**150**(3):416–24. Available from: <https://doi.org/10.1016/j.ajodo.2016.02.025>
18. Walter C, Sagheb K, Blatt S, Klein M, Herrmann J, Kleinheinz J, *et al*. Evaluation of the clinical safety and performance of a narrow diameter (2.9 mm) bone-level implant: a 1-year prospective single-arm multicenter study. *International Journal of Implant Dentistry [Internet]*. 2023 Sep 19;**9**(1). Available from: <https://doi.org/10.1186/s40729-023-00495-x>
19. Lacarbonara M, Cazzolla AP, Lacarbonara V, Lo Muzio L, Ciavarella D, Testa N, *et al*. Prosthetic rehabilitation of maxillary lateral incisors agenesis using dental mini-implants: a multicenter 10-year follow-up. *Clinical Oral Investigations [Internet]*. 2021 Sep 26;**26**(2):1963–74. Available from: <https://doi.org/10.1007/s00784-021-04176-0>
20. Stabryła J, Plakwicz P, Kukuła K, Zadurska M, Czochrowska E. Comparisons of different treatment methods and their outcomes for impacted maxillary and mandibular canines. *The Journal of the American Dental Association [Internet]*. 2021 Nov 1;**152**(11):919–26. Available from: <https://doi.org/10.1016/j.adaj.2021.05.015>
21. Rocuzzo A, Imber J, Lempert J, Hosseini M, Jensen SS. Narrow diameter implants to replace congenitally missing maxillary lateral incisors: A 1-year prospective, controlled, clinical study. *Clinical Oral Implants Research [Internet]*. 2022 Jul 11;**33**(8):844–57. Available from: <https://doi.org/10.1111/clr.13966>
22. Gupta SPS, Rauniyar S. Orthodontic space closure of a missing maxillary lateral incisor followed by canine lateralization. *Case Reports in Dentistry [Internet]*. 2020 Nov 14;2020:1–7. Available from: <https://doi.org/10.1155/2020/8820711>
23. Robertsson S, Mohlin B. The congenitally missing upper lateral incisor. A retrospective study of orthodontic space closure versus restorative treatment. *European Journal of Orthodontics [Internet]*. 2000 Dec 1;**22**(6):697–710. Available from: <https://doi.org/10.1093/ejo/22.6.697>
24. Vignon M, Bensaidani T, Soliverès S, Bousquet P. Interdisciplinary management of Bilateral congenitally missing lateral incisor agenesis. *Case Reports in Dentistry [Internet]*. 2023 Jul 10;2023:1–12. Available from: <https://doi.org/10.1155/2023/5576050>
25. Millar B, Taylor N. Lateral thinking: the management of missing upper lateral incisors. *British Dental Journal [Internet]*. 1995 Aug 1;**179**(3):99–106. Available from: <https://doi.org/10.1038/sj.bdj.4808848>
26. Johal A, Huang Y, Toledano S. Hypodontia and its impact on a young person's quality of life, esthetics, and self-esteem. *American Journal of Orthodontics and Dentofacial Orthopedics [Internet]*. 2022 Feb 1;**161**(2):220–7. Available from: <https://doi.org/10.1016/j.ajodo.2020.07.039>
27. Oosterkamp BCM, Dijkstra PU, Rimmelink HJ, Van Oort RP, Sandham A. Orthodontic Space Closure versus Prosthetic Replacement of Missing Upper Lateral Incisors in Patients with Bilateral Cleft Lip and Palate. *The Cleft Palate Craniofacial Journal [Internet]*. 2010 Nov 1;**47**(6):591–6. Available from: <https://doi.org/10.1597/09-092>
28. Jamilian A, Perillo L, Rosa M. Missing upper incisors: a retrospective study of orthodontic space closure versus implant. *Progress in Orthodontics [Internet]*. 2015 Feb 25;**16**(1). Available from: <https://doi.org/10.1186/s40510-015-0072-2>
29. Lam WYH, Botelho M, McGrath C. Longevity of implant crowns and 2-unit cantilevered resin-bonded bridges. *Clinical Oral Implants Research [Internet]*. 2012 Oct 2;**24**(12):1369–74. Available from: <https://doi.org/10.1111/clr.12034>
30. Lam WYH, McGrath C, Botelho M. Impact of complications of single tooth restorations on oral health-related quality of life. *Clinical Oral Implants Research [Internet]*. 2013 Apr 15;**25**(1):67–73. Available from: <https://doi.org/10.1111/clr.12166>