

Review article

Diagnosis and treatment of intrauterine adhesions

Salma U¹, Xu D², Sheikh MSA³

Abstract

Intrauterine adhesions develop as a result of intrauterine trauma. The degree of adhesion formation and the impact of the adhesions on the contour of uterine cavity vary greatly. It has been reported that intra abdominal adhesions occur in 60–90% of women who have undergone major gynecological procedures. Hysteroscopy is the gold standard for the diagnosis of severe intrauterine adhesions. Effective methods for preventing adhesions, a variety of surgical techniques and agents have been advocated for the prevention of intrauterine adhesion formation. The present review indicates that there is still no single modality proven to be unequivocally effective in preventing post-operative adhesion formation either for laparoscopic or for hysteroscopic use. Hopefully, the increasing understanding of the future emphasis will probably be on a multimodality therapy, including the use of pharmacologic adjuncts in conjunction with a barrier material tailored to the specific operative procedure and a precise surgical technique.

Key words: Intrauterine adhesion, hysteroscopy, Pharmacologic adjuncts.

Introduction

Intrauterine adhesions are a recognized complication of operative hysteroscopy. Amenorrhea associated with intrauterine adhesions was first described in 1894 by H. Fritsch in a patient after postpartum curettage¹. Subsequently; Asher man published two reports². On the frequency and the etiology of intrauterine adhesions and the eponym Asher man's syndrome has been used ever since. Intrauterine adhesions develop as a result of intrauterine trauma. Adhesions are defined as abnormal fibrous connections joining tissue surfaces in abnormal locations³. Diamond and Hellebrekers divided adhesions into two types, primary or de novo adhesions (those that are freshly formed, on locations where no adhesions were found before) and secondary or reformed adhesions (those adhesions that undergo adhesiolysis and recur at the same location⁴. Another type is modified classification based on European society of gynaecological endoscopy(ESGE)table-1, in gynaecology, adhesions can be differentiated on the basis of location, into intraabdominal or intrauterine. The most frequent cause of their formation is post-partum or post-abortion

overzealous dilatation and curettage. Transperitoneal operation can lead to the formation of intraabdominal adhesions ranging from minimal scarring of serosal surface to firm agglutination of nearly all structures. The formation of adhesions following open gynaecological surgery has considerable epidemiological and clinical impact. It has been reported that intraabdominal adhesions occur in 60–90% of women who have undergone major gynaecological procedure⁵. Conducting Scotland Reported that women undergoing an initial open surgery for gynecological conditions had a 5% likelihood of being rehospitalized because of adhesions over the next 10 years and overall, adhesions may have contributed to rehospitalization in an additional 20% of patients. In recent years, many attempts have been made to develop effective strategies to reduce the risk of post-surgical adhesions⁶.

Prevalence and symptomatology

Intrauterine adhesions, also known as synechiae, are found in 1.5% in women who

-
1. Umme Salma,
 2. *Dabao Xu,
 3. Md Sayed Ali Sheikh

Department of Gynecology and Obstetrics, Xiangya 3rd Hospital, Central South University.

*Corresponds to: Dabao Xu, Associate Professor, 138, Tongzipo Road, Changsha, Hunan, 410013, P.R.China. **Email:** bxudabao@hotmail.com.

undergo hysterosalpingography ⁷. Asherman's syndrome, also called "uterine synechiae" or intrauterine adhesions, presents a condition characterized by the presence of scars within the uterine cavity. Patients with intrauterine adhesions usually present with infertility, menstrual cycle disorders, repeated pregnancy losses, or abnormal adherence of the placenta⁸. Intrauterine adhesions can be asymptomatic and no clinical significance. Symptoms associated with clinically significant

intrauterine adhesions include: Infertility Menstrual irregularities (hypo menorrhea, amenorrhea) cyclic pelvic pain recurrent pregnancy loss. Disorders of placenta ion, including placenta accrete and previa, are relatively rare ⁹.The condition was found in 1.5% of women undergoing HSG. Between 5 and 39% of women with recurrent miscarriage ¹⁰, and up to 40% of patients who have undergone D&C for retained products of conception.

Table 1:

The American Fertility Society classification of intrauterine adhesions, 1988.			
Extent of Cavity Involved	<1/3	1/3–2/3	>2/3
	1	2	4
Type of Adhesions	Filmy	Filmy & Dense	Dense
	1	2	4
Menstrual Pattern	Normal	Hypomenorrhea	Amenorrhea
	0	2	4
Prognostic classification		HSG^a score	Hysteroscopy score
Stage I (Mild)	1-4		
Stage II (Moderate)	5-8		
Stage III (Severe)	9-12		

Source: The American Fertility Society classifications of adnexal adhesions, distal tubal occlusion, tubal occlusion secondary to tubal ligation, tubal pregnancies, mullerian anomalies and intrauterine adhesions. *Fertil Steril* 1988;49:944-55. (34)

^a All adhesions should be considered dense.

Yu. Asherman syndrome. Fertil Steril 2008.

Etiology

Approximately 90 percent of cases of severe intrauterine adhesive disease are related to curettage for pregnancy complications, such as missed or incomplete abortion, postpartum hemorrhage, or retained placental remnants. Pregnancy is the most common predisposing factor, usually associated with trauma to the endometrial, as seen in patients undergoing curettage in the puerperium, after missed abortion, evacuation of a hydatidiform mole, or cesarean section. Postpartum curettage is most likely to cause intrauterine adhesions when performed between the second and fourth weeks postpartum. Repeated curettage for pregnancy loss increases the risk of developing adhesions from 8 percent after the first

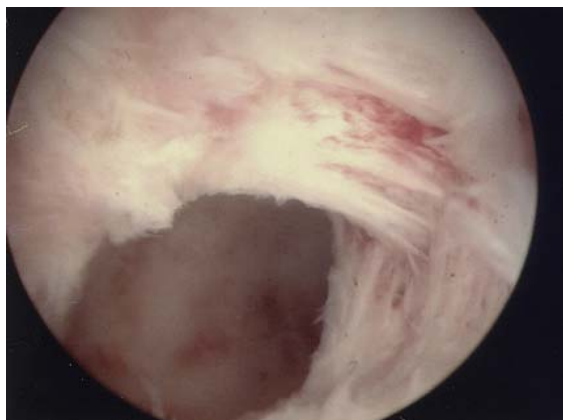
curettage to over 30 percent with the third curettage. It is estimated that up to 5% of D&Cs result in intrauterine adhesions. More conservative estimates put this rate at 1%. Intrauterine adhesions result from 25% of D&Cs performed 1-4 weeks post-partum ¹¹, 30.9% of D&Cs performed for miscarriages and 6.4% of D&Cs performed for incomplete miscarriages.

In the case of missed miscarriages, the time period between fetal demise and curettage increases the likelihood of adhesion formation to over 30.9% ¹².The risk of intrauterine adhesions also increases with the number of procedures: one study estimated the risk to be 16% after one D&C and 32% after 3 or more D&Cs. AS can also result from other pelvic

surgeries including Cesarean sections¹³. Chronic endometritis from genital tuberculosis is a significant cause of severe IUA in the developing world, often resulting in total obliteration of the uterine cavity which is difficult to treat¹⁴. One study found a significant correlation between Müllerian anomalies and IUA. This apparent correlation is because women with congenital uterine anomalies are predisposed to miscarriages¹⁵, and therefore would also have higher rates of D&Cs performed than the general population, which could account for the higher rate of IUA observed. It is also feasible that women with septate uteri and other Müllerian defects are at a higher risk of sustaining endometrial damage after blind D&C due to their atypical anatomy. An artificial form of Asherman's syndrome can be surgically induced by endometrial ablation in women with excessive uterine bleeding, in lieu of hysterectomy. In the developing world, genital tuberculosis is a cause of intrauterine adhesions, which are often severe with complete obliteration of the uterine cavity¹⁶.

Diagnosis

Hysteroscopy is the gold standard for diagnosis¹⁷. Imaging by sonohysterography or hysterosalpingography will reveal the extent of the scar formation. Ultrasound is not a reliable method of diagnosing intrauterine adhesion. Hysteroscopy Fig.1 is better for view.



Hysteroscopic view of a case of Asherman syndrome with adhesions bands in the anterior and left lateral side wall of the uterine cavity.

Figure 1: Ashermans syndrome, (Source) Fertil Steril 2008

Strategies for adhesion prevention

Effective methods for preventing adhesions, a variety of surgical techniques and agents have been advocated for the prevention of intrauterine adhesion formation. The main approaches include adjusting surgical techniques, minimizing tissue trauma and applying pharmacological and/or barrier adjuncts to decrease adhesion formation, prevention of adhesion by gynecological laparoscopic surgery.

Surgical technique

Laparoscopy has been thought to have an advantage of reducing the formation of post-operative adhesions, as it seems to meet most of the well-known principles of a traumatic, gentle and bloodless surgery originally described. Laparoscopy with its minimal access to the abdominal cavity reduces the amplitude of peritoneal injury, which seems to play a pivotal role in the pathophysiology of adhesion formation^{18,19,20}. Avoiding incisions through highly vascularized anatomical structures e.g. muscle layers, and minimizing the extent of tissue trauma are the two confirmed basic principles for reducing post-operative adhesions²¹. Minimal access also prevents the abdominal cavity from exposure to air and foreign reactive materials, thus reducing the formation of adhesions at locations distant from the operative site²². The laparoscopic magnified view enables a gentler handling and a more precise dissection of anatomical structures at the operative site, thus contributing to minimize the degree of tissue trauma. Moreover, recent findings seem to indicate that the laparoscopic environment may reduce post-operative adhesion formation by directly interfering with the fibrinolytic activity of peritoneum via the inhibition of plasminogen activator inhibitor 1 (PAI-1) released by mesothelial cell. Such concepts contrast with conclusions drawn who have demonstrated that carbon dioxide (CO₂) pneumoperitoneum during laparoscopic surgery may act as a cofactor in post-operative adhesion formation mostly by inducing peritoneal hypoxia through a compression of the capillary flow in the superficial peritoneal

layers. Furthermore, it has been demonstrated that CO₂ pneumoperitoneum induces respiratory acidosis that, if not corrected, leads to metabolic acidosis and metabolic hypoxia²³. This could be deleterious for the peritoneal cells and enhance the detrimental effect of the CO₂ pneumoperitoneum-induced peritoneal ischemic hypoxia. Role of CO₂, further studies have shown that CO₂ pneumoperitoneum enhances adhesion formation through an up-regulation of hypoxia inducible factors. Role of hypoxia inducible factors, 1 α and 2 α in basal adhesion formation and in carbon dioxide plasminogen system (PAI-1) members of the vascular endothelial growth factor family and placental growth factor.

Furthermore, a role for reactive-oxygen species (ROS) in post-operative adhesion formation at laparoscopy has been suggested, since ROS is produced during the ischemia-reperfusion process (insufflations of peritoneum = ischemia; deflation of pneumoperitoneum = reperfusion) and the administration of ROS scavengers has been demonstrated to decrease adhesion formation. Hypothermia has been demonstrated to reduce the toxic effects of hypoxia and of the ischemia-reperfusion process in mice²⁴. On the other hand, the use of humidified gases has been demonstrated to minimize adhesion formation induced by desiccation. Thus, the concept of combining controlled intraperitoneal cooling with a rigorous prevention of desiccation might be important for clinical adhesion prevention. However, laparoscopic technique, a further improvement in preventing adhesion formation in gynaecologic laparoscopy may be provided by the adherence to 'good' surgical techniques, amount of Ringer's lactate at the completion of the procedure should be followed. Modern surgical devices are provided with both cutting and homeostatic activities, thus sparing the use of multiple ligatures, which also favour adhesions. The newly developed laparoscopic techniques, it is worth mentioning that temporary ovarian suspension is a technique recently proposed as a simple and effective method in preventing periovarian post-operative adhesions, especially in the case of surgery for advanced endometriosis. Less

recent are the numerous adjusts in laparoscopic technique proposed to prevent adhesion formation in the case of myomectomy or interventions for tubal pregnancy. Every gynaecologist performing pelvic surgery by laparoscopic techniques believes that this result in fewer post-operative adhesions than similar procedures performed at laparotomy.

Pharmacological adjuvant

A wide variety of pharmacological adjuvant, including steroidal and non-steroidal anti-inflammatory agents, antihistamines, progesterone, gonadotrophin-releasing hormone (GnRH α) agonists, fibrinolytics and anticoagulants have been tested to prevent post-operative adhesion formation following open abdominal surgery without any clearly demonstrated.

Anti-inflammatory agents

Progesterone has been investigated for reduction of post-operative adhesions after the initial observation that adhesions were reduced after ovarian wedge resection if that ovary was containing an active corpus luteum at the time of operation²⁵. The role of progesterone in preventing post-operative adhesion formation reported exclusively on patients treated by traditional surgery. At present, the use of progesterone in preventing adhesion development in clinical practice is also not recommended. Combined pre-operative and post-operative treatment with GnRH agonists has been shown to decrease adhesion formation and reformation in both animal models and clinical trials. Among the various direct and indirect actions through which GnRH agonists might modulate adhesion formation, the interference with fibrinolytic processes seems to be predominant. On the basis of the data available, adhesion prevention seems to be at its best when pre- (2–3 months) and post-operative (2–3 months) GnRH agonists treatment is administered. At present, no studies evaluating the role of GnRH agonists in preventing adhesion following laparoscopic gynaecological procedures are available in the literature.

Fibrinolytic agents

An imbalance between fibrin-forming (coagulation) and fibrin-dissolving (fibrinolytic) activities in the peritoneum has been hypothesized as one of the major pathogenesis factors in adhesion development in animals²⁶. A recent prospective study in humans seems to add further weight to the hypothesis that this applies to humans also. Fibrinolytic agents have been suggested in preventing adhesions, as they act directly by reducing the fibrinous mass and indirectly by stimulating plasminogen activator (PA) activity. Thrombolytic agents including plasmin preparations (plasmin, actase and fibrinolysin) and plasmin activators (streptokinase, urokinase and recombinant human tissue PA) have been found to be effective in preventing adhesion formation in the greater part of the reviewed animal and clinical studies. However, the current use of fibrinolytic agents in humans awaits further evaluation of their safety and side effects. Moreover, studies pertaining to the role of fibrinolytic agents on the prevention of adhesion after gynaecological laparoscopic surgery are still missing.

Anticoagulants

Heparin is the most widely investigated anticoagulant used for prevention of adhesions. Its mechanism of action may be mediated by an interaction with antithrombin III in the clotting cascade or by a direct stimulation of the activity of PAs. Animal studies where heparin was administered by different routes either alone or in combination with peritoneal irrigants, carboxymethylcellulose instillates or mechanical barriers resulted in conflicting reports demonstrating its efficacy in reducing adhesion formation and reformation. However, the efficacy of heparin in reducing adhesion formation whether administered alone or in combination with Interceded TC7 barrier was not able to be demonstrated in the two clinical trials available in the literature. Also, heparin was found to have no therapeutic advantage over Ringer's lactated solution in the prevention of post-operative pelvic adhesion, in the paper reporting on patients undergoing

laparoscopic surgery for different gynaecological conditions.

Antibiotics

The rationale behind the use of antibiotics is prophylaxis against infection and hence the inflammatory response that triggers the adhesion formation. Systemic broad-spectrum antibiotics, particularly cephalosporin, were widely used in the past. At present, there is insufficient published data from human studies supporting this practice. The ideal barrier should be noninflammatory, nonimmunogenic, persist during the remesothelialization, stay in place without suture, remain active in the presence of blood and be completely biodegradable.

Oxidized regenerated cellulose

Oxidized regenerated cellulose (ORC), the most widely used adhesion-reducing substance has been used in human studies. Use of interceded (TC7) absorbable adhesion barrier to reduce Post-operative adhesion reformation in infertility and endometriosis surgery. It reduce adhesion formation by its transformation into a gelatinous mass covering the damaged peritoneum and forming a barrier physically separating adjacent raw peritoneal surfaces. The use of ORC was associated with a reduced incidence of both de novo and reformed adhesions as diagnosed at the second-look laparoscopy. In the first study, reported a significant reduction of de novo adhesion formation in premenopausal women undergoing laparoscopic myomectomy with the application of ORC on the uterine incisions and sutures, in comparison with those undergoing the same surgery but without any specific antiadhesive strategy.

Expanded polytetrafluoroethylene

Expanded polytetrafluoroethylene non-absorbable barrier has also undergone evaluation in a randomized multicentre controlled trial. This product must be sewn in place and is usually removed during a second surgical procedure. In patients undergoing gynaecological surgery by laparotomy for adhesions or myoma, Gore-Tex Surgical Membrane was shown to decrease the severity,

extent and incidence of adhesions in treated areas. Its usefulness is limited by the nature of the product: it must be sutured in place and, in most cases, should be removed at a subsequent surgery. It is very difficult to apply at laparoscopy.

Icodextrin

Icodextrin (ADEPT, Baxter, USA) is an α -1, 4 glucose polymer of high molecular weight, which is rapidly metabolized to glucose by the α -amylase in the systemic circulation, but is adsorbed only slowly from the peritoneal cavity. The 4% solution of icodextrin, having a longer peritoneal residence time (≥ 4 days) than crystalloid solutions has the potential to significantly reduce post-surgical adhesion formation by means of a prolonged hydroflotation.

Hyaluronic acid

Hyaluronic acid (HA) is a naturally occurring glycosaminoglycan and a major component of the extracellular matrix, including connective tissue, skin, cartilage and vitreous and synovial fluids. This polymer is biocompatible, nonimmunogenic, non-toxic and naturally bioadsorbable. Intraperitoneal instillation coats serosal surface minimizes serosal desiccation and reduces adhesion formation. However, its use after tissue injury is ineffective. Cross-linking HA with ferric ion (FeHA) increases the viscosity and half-life. In a large multicentre randomized study showed that Integral. The first marketed derivative of FeHA was effective in reducing the extension and the severity of post-operative adhesions in comparison to lactated Ringer's solution in patients undergoing peritoneal cavity surgery by laparotomy with a planned second-look laparoscopy. Likewise, in three other randomized trials ferric hyaluronate gel was demonstrated to be safe and highly efficacious in reducing the number, severity and extent of adhesions throughout the abdomen following pelvic laparotomic surgery. Further, the application of ACP as an antiadhesive barrier in infertile patients undergoing laparoscopic myomectomy is associated with the increased pregnancy rates than laparoscopic myomectomy alone. The favourable safety

profile and the efficacious antiadhesive action of this adjunct following laparoscopic myomectomy have been recently confirmed in a blinded, controlled, randomized, multicentre study.

Solution of HA

Sepracoat coating solution a liquid composed of 0.4% sodium hyaluronate (hyaluronic acid) in phosphate buffered saline is applied intraoperatively, prior to dissection, to protect peritoneal surfaces from indirect surgical trauma or post-operatively to separate surfaces after they are traumatized²⁷. In humans, preliminary results were promising and have been confirmed in a multicentre randomized trial where intraperitoneal Sepracoat instillate was safe and significantly more effective than placebo in reducing the incidence, extent and severity of de novo adhesions to multiple sites indirectly traumatized by gynaecologic laparotomic surgery²⁸.

Viscoelastic gel

Oxiplex/AP Gel is a viscoelastic gel composed of polyethylene oxide and carboxymethylcellulose stabilized by calcium chloride specifically formulated for laparoscopic application, with tissue adherence and persistence sufficient to prevent adhesion formation.

Hydrogel

SprayGel consists of two synthetic liquid precursors that, when mixed, rapidly cross-link to form a solid, flexible, absorbable hydrogel. The solid polymer acts as an adhesion barrier and it can be easily applied by laparoscopy. The currently available evidence does not support the use of SprayGel either in decreasing the extent of adhesion or in reducing the proportion of women with adhesions.

Prevention of IUA in hysteroscopic surgery

Surgical technique

As for hysteroscopic, the adherence to an appropriate hysteroscopic surgical technique may minimize the risk of post-operative IUA. General recommendations include avoiding

trauma of healthy endometrium and myometrium surrounding the lesions to be removed, reducing the usage of electro surgery whenever possible especially during the removal of myomas with extensive intramural involvement and avoiding forced cervical manipulation.

Early second-look hysteroscopy

An early second-look hysteroscopy after any hysteroscopy surgery has been advocated as an effective preventive and therapeutic strategy. Indeed, although IUAs are recognized, they are likely to be 'mild' and they can be easily dissected by hysteroscope sheath alone or by micro scissors. However, the relevance of removing 'mild' intracavitary adhesions has not yet been proven. Severe type of intrauterine adhesion is better adhesiolysis after 1 month follow-up hysteroscopy adhesiolysis²⁹.

Antibiotic administration

Antibiotic administration before, during and after hysteroscopic surgery to avoid infections and therefore to prevent post-operative IUA is not consistently recommended.

Pre-operative hormonal endometrial suppression

GnRH analogues and danazol are widely administrated before some major hysteroscopic procedures (e.g. transcervical resection of endometrium, myomectomy and metroplasty) to provide technically optimal conditions for the surgery (by suppressing the endometrium and by decreasing vascularity and oedema), as well as to minimize perioperative complications (perforation, fluid overload and bleeding). The role of endometrial suppression before resectoscopic surgery on the frequency of post-operative IUA has been questioned.

Post-operative hormonal treatment

The post-operative administration of conjugated oestrogen (dose: 1.25–5 mg daily) for 30–60 consecutive days and progestin therapy in a cyclic regimen seem to stimulate the endometrium so that the scarred surfaces are re-epithelialized. However, the efficacy of

this method needs to be validated by large randomized studies. The insertion of a levonorgestrel-releasing intrauterine device (IUD) might represent another promising tool to prevent IUA adhesions, but studies addressing this issue are still missing.

Barrier methods

The maintenance of the freshly separated uterine cavity after any uterine forced intervention is an essential prerequisite for prevention of subsequent adhesion formation, whereas rapid endometrial re-growth might be enhanced by oestrogen and progestogens cyclic administration³⁰.



Figure 2: Pediatric Foley catheter balloon (source, Middle East Fertility Society Journal 2005)

Intrauterine device

For several years, the placement of an IUD in the uterine cavity for 1- 3 months has been considered the standard method of maintaining the uterine cavity after uterine forced intervention³¹. However the specific type to be used for this purpose remains a controversial issue. The copper-bearing IUDs and the progestasert intrauterine system (IUS) seem to have a too small surface area to prevent adhesion reformation, whereas those containing copper might induce an excessive inflammatory reaction. Actually, the loop-IUS seems to represent the best to use as it keeps the raw dissected surfaces separated during the initial healing phase, reducing the chance of re-

adherence. Despite good results, this method has been associated with several complications such as infections, uterine perforation, and misplacement of the device and IUA recurrence. Prophylactic antibiotics are recommended to minimize the risk of infection.

Foley catheter balloon

An inflated pediatric Foley catheter balloon inserted into the uterine cavity for several days retains separation of the uterine walls with fewer complications in comparison with IUDs²⁹ (Fig.2). Its use is however limited because of the need for hospitalization during the duration of treatment, pain and the shortness of the treatment period which, in itself, is an obstacle in ensuring definitive results in preventing IUA¹⁵. Foley catheter is not only safe but also effective in the restoration of normal menstrual pattern and fertility.

Auto-cross-linked HA gel

The introduction of APC gel into the uterine cavity at the end of the hysteroscopic surgery through the out-flow channel of the resectoscope, whereas the surgeon progressively limits the entering of the distension medium through the in-flow channel. The procedure is considered complete when, under hysteroscopic view, the gel seems to have replaced the entire liquid medium and the cavity appears completely filled by the gel from tubal ostia to internal uterine orifice. Its high viscosity and adhesiveness make it easier to introduce the gel into the uterine cavity and ultrasound scans have confirmed that APC gel remains in situ for at least 72 hours.

HA and carboxymethylcellulose barrier

Seaprafilm is a bioresorbable membrane of chemically modified HA and carboxymethylcellulose, which has been shown to be effective in reducing adhesion formation after suction curettage for incomplete and missed abortion.

Discussion

Intrauterine adhesion occurs after trauma to the basalis layer of the endometrium generally

after endometrial curettage. IUA cause of infertility by tubule occlusion, distortions in the symmetry of the uterine cavity and damage to the basalis layer of the endometrium that predisposes towards abnormal placental implantation¹³. IUA grade was proportionally higher among the women with more than three previous abortions. Speculative and intuitive reasoning might lead to the belief that missed abortions could be related to IUA, because the death concept remain in contact with the endometrium for a longer period, thereby eliciting fibroblastic activity and endometrial regeneration¹⁷. IUA also caused by an insult to the endometrium that engenders adhesion of the myometrium to the opposing uterine wall. Adhesions formation noted in 7% to 30% of patients undergoing hysteroscopic examination after D&C for sponetuous abortion^{32, 33, 34}. Uterine infection can also causes intrauterine adhesions, particularly genital tuberculosis, which is associated with uterine cavity obliteration in over half of cases³⁵. However, intrauterine adhesions can reform even following surgical treatment. Several methods have been to prevent post-surgical adhesion. It can be classified as either pharmacological agents (anti-inflammatory, antioxidants, anti-coagulants, and fibrinolytics)³⁶, or physical barriers, where substances are interposed between adjacent injured surfaces to avoid direct contact after surgery³⁷. In recent years, several methods have been used to prevent intrauterine adhesions, as well as IUD or Foley's catheter intrauterine insertion after surgery. In our experience, high frequencies of post-operative adhesions were observed, especially after hysteroscopic adhesions. The extent of scar formation is critical. Small scars can usually be treated with success either pharmacological agents (anti-inflammatory, antioxidants, anticoagulants and fibrinolytics)³⁸, or physical barriers, where substances are interposed between adjacent injured surfaces to avoid direct contact after surgery. Extensive obliteration of the uterine cavity or fallopian tube openings (Ostia) may require several surgical interventions or even be uncorrectable. Some author's belief hysteroscopy is the golden method for prevention of adhesions. Hysteroscopy should be offered to the entire

patient who is subjected to curettage for abortion or post abortion evacuation, especially if those women desire a future pregnancy³⁹. Hysteroscopy, however, provides more accurate picture and allows for the surgical correction to be carried-out if indicated. Severe type of intrauterine adhesions is difficult to treat. These can be managed safely and effectively hysteroscopically, restoring fertility and normal menstrual patterns²⁹. Hamu introduced second look hysteroscopy in order to assess the result of surgical procedure⁴⁰, grade I and Grade II adhesions may be amenable to further attempts at correction, Grade III adhesions, which are thick, dense and fibrous, lead to uniformly poor results when attempts to reconstruction are made. However it seems reasonable that routine early follow-up hysteroscopic intervention might be beneficial⁴¹. Although minimally invasive endoscopic approach has been shown to be less adhesiogenic than traditional surgery, at least with regard to selected procedures, it does not however totally eliminate the problem. Consequently, many attempts have been made to further reduce adhesion formation following endoscopic procedures and many surgical techniques; pharmacological agents and mechanical barriers have been advocated to address this issue. The present review clearly indicates that there is still no single modality proven to be unequivocally effective in

preventing post-operative adhesion formation either for laparoscopic or for hysteroscopic use. Furthermore, the available adhesion-reducing substances are rather expensive. Much work needs to be done to enhance this adjunctive therapy, since excellent surgical technique alone seems insufficient. Hopefully, the increasing understanding of the pathophysiology of peritoneal healing will provide the rational basis for the development of further specific interventions at critical points along the adhesion formation cascade. The future emphasis will probably be on a multimodality therapy, including the use of pharmacologic adjuvants in conjunction with a barrier material tailored to the specific operative procedure and a precise surgical technique⁴¹.

Conclusions

Although minimally invasive endoscopic approach has been shown to be less adhesiogenic than traditional surgery, it does not totally eliminate the problem. Many attempts have been made to further reduce adhesion formation following endoscopic procedures and many surgical techniques; pharmacological agents and mechanical barriers have been advocated to address this issue.

References

1. Asher man JG. Amenorrhea traumatic (atretica). *Obstet Gynaecol Br Emp* 1948; 55:23.
2. Asher man JG. Traumatic intra-uterine adhesions. *Obstet Gynaecol Br Emp* 1950; 7:892.
3. Diamond MP, Freeman ML. Clinical implications of postsurgical adhesions. *Hum Reprod* 2001; 7:567–76. doi:10.1093/humupd/7.6.567. PMID:11727865.
4. Pabuçcu R, Atay V, Orhon E, et al. Hysteroscopic treatment of intrauterine adhesions is safe and effective in the restoration of normal menstruation and fertility. *Fertil Steril* 1997; 68: 1141–1143. doi:10.1016/S0015-0282(97)00375-0.
5. Nappil A, Grecol E, Guidal M, et al. Prevention of adhesions in gynaecological endoscopy Adhesions: preventive strategies. *Eur. J. Surg. Suppl* 1997; 577: 32–39.
6. Watson A, Vandekerckhove P, Lilford R. Liquid and fluid agents for preventing adhesions after surgery for subfertility (Cochrane Review). 2002;
7. Dmowski WP, Greenblatt RB. Asherman's syndrome and risk of placenta accrete. *Obstet Gynecol* 1969; 34:288-299. PMID:5816312
8. Schenker JG. Etiology of and therapeutic approach to synechia uteri. *Eur J Obstet Gynecol Reprod Biol* 1996; 65:109-113. doi:10.1016/0028-2243(95)02315-J.
9. Dmowski WP, Greenblatt RB. Asherman's syndrome and risk of placenta accrete. *Obstet Gynecol* 1969; 34 (2): 288–299. PMID:5816312.
10. Toaff R. Some remarks on posttraumatic uterine adhesions in French. *Rev Fr Gynecol Obstet* 1966; 61 (7): 550–552. PMID:5940506.
11. Ventolini G, Zhang M, Gruber J. Hysteroscopy in the evaluation of patients with recurrent pregnancy loss: a cohort study in a primary care population. *Surg Endosc* 2004; 18 (12): 1782–1784. doi:10.1007/s00464-003-8258-y. PMID:15809790.
12. Westendorp, ICD, Ankum WM, WJ Mol B, et al. Prevalence of Asherman's syndrome after secondary removal of placental remnants or a repeat curettage for incomplete abortion. *Hum Reprod* 1998; 13 (12): 3347–3350. doi:10.1093/humrep/13.12.3347. PMID:9886512.
13. Schenker JG, Margalioth EJ. Intra-uterine adhesions: an updated appraisal. *Fertility Sterility* 1982; 37 (5): 593–610. PMID:6281085.
14. Rochet Y, Dargent D, Bremond A, et al. The obstetrical outcome of women with surgically treated uterine synechiae (in French). *J Gynecol Obstet Biol Reprod* 1979; 8 (8): 723–726.
15. Stillman RJ, Asarkof N. Association between mullerian duct malformations and Asherman syndrome in infertile women. *Obstet Gynecol* 1985; 65 (5): 673-7. PMID:3982744.
16. Buttram VC, Turati G. Uterine synechiae: variations in severity and some conditions which may be conducive to severe adhesions. *Int J Fertil* 1977; 22 (2): 98–103. PMID:20418.
17. Valle RF, Sciarra JJ. Intrauterine adhesions: Hysteroscopic diagnosis, classification, treatment and reproductive outcome. *Am J Obste* 1988; 158 (6Pt1): 1459–1470.
18. Gut, CN, Oniu T, Schemmer P, et al. Fewer adhesions induced by laparoscopic surgery?. *Surg Endosc* 2004; 18:898–906. doi:10.1007/s00464-003-9233-3. PMID:15108105.
19. Liakakos T, Thomakos N, Fine PM, et al. Peritoneal adhesions: etiology, pathophysiology, and clinical significance. *Dig Surg* 2001; 18:260–73. doi:10.1159/000050149. PMID:11528133.
20. Rock JA. Infertility: surgical aspects. In Yen SSC and Jaffe RB (Eds.). *Reproductive Endocrinology, Physiology Pathophysiology and Clinical Management* (Sauders, Philadelphia, PA) pp 1991; 710–4.
21. Moreno A, Aguayo JL, Zambudio G, et al. Influence of abdominal incision on the formation of post-operative peritoneal adhesions: an experimental study in rats. *Eur J Surg* 1996; 162:181–5. PMID:8695731.
22. Ziprin P, Ridgway PF, Peck DH, et al. Laparoscopic-type environment enhances mesothelial cell fibrinolytic activity in vitro via a down-regulation of plasminogen activator inhibitor-1 activity. *Surgery* 2003; 134:758–65. doi:10.1016/S0039-6060(03)00293-9.
23. Molinas CR, Campo R, Dewerchin M, et al. Role of vascular endothelial growth factor and placental growth factor in basal adhesion formation and in carbon dioxide pneumoperitoneum –enhanced adhesion formation after laparoscopic surgery in transgenic mice. *Fertil Steril* 2003a; 80:803–11. doi:10.1016/S0015-0282(03)00768-4.
24. Eddy CA, Asch RH, Balmaceda JP. Pelvic adhesion following microsurgical and macrosurgical wedge

Management of intrauterine adhesion

- resection of the ovaries. *Fertil Steril* 1980;33:557-61. PMID:6768600.
25. Binda MM, Molinas CR, Mailova K, et al. Effect of temperature upon adhesion formation in a laparoscopic mouse model. *Hum Reprod* 2004; 19:2626-32. doi:10.1093/humrep/deh495. PMID:15333592.
26. Diamond M.P, The Sepracoat Adhesion Study Group. Reduction of de-novo postsurgical adhesions by intraoperative precoating with Sepracoat (HLA-C) solution: a prospective, randomised, blinded, placebo-controlled multicenter study. *Fertil Steril* 1998; 69: 1067-1074. doi:10.1016/S0015-0282(98)00057-0.
27. Berg RA, Rodgers KE, Cortese S, et al. Post-surgical adhesion reformation is inhibited by Oxiplex adhesion barrier gel. *International Proceedings. World Meeting on Minimally Invasive Surgery in Gynecology* 2003; 17-21.
28. Ar'Rajab A, Ahren B, Rozga J, et al. Phosphatidyl choline prevents post-operative peritoneal adhesions. An experimental study in the rat. *J. Surg. Res* 1991; 50: 212-215. doi:10.1016/0022-4804(91)90180-T.
29. Umme salma, Da bao xu, Md Sayed Ali Sheikh. Observational study of new treatment proposal for severe intrauterine adhesion. *IJB* 2011;1(1):43-56.
30. Hellebrekers B.W, Trimbos T.C.M, Emeis J.J, et al. Use of fibrinolytic agents in the prevention of postoperative adhesion formation. *Fertil. Steril* 2000; 74: 203-212. doi:10.1016/S0015-0282(00)00656-7.
31. Adoni A, Palti Z, MilWidsky et al. The incidence of intrauterine adhesion following spontaneous abortion. *Int J Fertil* 1982; 27:117-8. PMID:6126446.
32. Friedler S, Margalioth EJ, Kafka I, et al. Incidence of post abortion intrauterine adhesions evaluated by hysteroscopy-A prospective study. *Hum Reported* 1993;8:442-4. PMID:8473464.
33. Tam WH, Lau WC, Cheung LP, et al. Intrauterine adhesion after conservative and surgical management of spontaneous abortion. *J Am Assoc Gynecol Laparosc* 2002;9:182-5. doi:10.1016/S1074-3804(05)60129-6.
34. Bukulmez O, Yarali H, Gurgan T, et al. Total corporal synchiae due to tuberculosis carry a very poor prognosis following hysteroscopic synechialysis. *Hum Reported* 1999;14:1960-1. doi:10.1093/humrep/14.8.1960. PMID:10438408.
35. Fernandez H, Al Najjar F, Chauvenaud L, et al. Fertility after treatment of Asherman's syndrome stage 3 and 4. *Minim Invasive Gynecol* 2006; 13 (5): 398-402. doi:10.1016/j.jmig.2006.04.013. PMID:16962521.
36. Bukulmez O, Yarali H, Gurgan T, et al. Total corporal synchiae due to tuberculosis carry a very poor prognosis following hysteroscopic synechialysis. *Hum Reported* 1999;14:1960-1. doi:10.1093/humrep/14.8.1960. PMID:10438408.
37. Romer T. post abortion hysteroscopy-a method for early diagnosis of congenital and acquired intrauterine cause of abortion. *Eur J Obstet Gynaecol Report Biol*, 1994;57(3):171-3. doi:10.1016/0028-2243(94)90295-X.
38. Ferland R, Mulani D, Campbell PK. Evaluation of a sprayable polyethylene glycol adhesion barrier in a porcine efficacy model. *Hum Reprod* 2001;16:2718-2. doi:10.1093/humrep/16.12.2718. PMID:11726601.
39. Hamou J. intrauterine adhesion, hysteroscopy and microhysteroscopy 1991 ;139-150.
40. Chapman R, Chapman K. The value of two stage laser treatment for severe Asherman's syndrome. *Br J Obstet Gynecol* 1996;103:1256-1258. doi:10.1111/j.1471-0528.1996.tb09641.x.
41. C. Nappi, A. Di Spiezio Sardo, E. Greco, M. et al. Prevention of adhesions in gynaecological endoscopy. *Human Reproduction Update* 2007 13(4):379-394. doi:10.1093/humupd/dml061. PMID:17452399.