

**LAPAROSCOPIC CHOLECYSTECTOMY :
A NEW ERA IN THE FIELD OF SURGERY
IN BANGLADESH**

S. A. Naycem¹, M. Rahman¹, G. Rasul², A. K. Khan², F. A. Muazzam³ and D. Hashimoto⁴

Summary

Laparoscopic cholecystectomy which is the latest development in the field of general surgery has recently been introduced in Bangladesh. We performed this less invasive surgery successfully on two cases of cholelithiasis for the first time in Bangladesh, one in BIRDEM Hospital and another in IPGMR Hospital in December, 1991. Though for those demonstrative cases, the set-up was difficult in a new place but there was no major technical problem during the procedure. After that there was a long gap and our team has started this procedure from April, 1993 regularly at two hospitals in Dhaka. By September, 1993 we have already performed over 100 cases of laparoscopic cholecystectomy successfully. This paper will describe the patient selection, preoperative investigation, operative procedure and postoperative care of laparoscopic cholecystectomy, the newest treatment modality for gallbladder diseases.

Key Words : Laparoscopic cholecystectomy, laparoscopy with abdominal wall lifting, Cholelithiasis, Cholecystitis

Introduction

Causing less trauma and least pain to the patient are the prime considerations for any modern surgical procedure. In the development of surgery, surgeons and researchers have always put in ardent efforts to introduce least invasive ways of treatment with the best results. Laparoscopic cholecystectomy is one of those efforts which is considered as a revolutionary event in the field of surgery. This latest treatment modality for the management of gallbladder diseases has already been proved to be promising and gained a wide range of acceptability. Though the standard open cholecystectomy is established as

-
1. Department of Surgery, BIRDEM Hospital, Dhaka, Bangladesh
 2. Department of Surgery, IPGMR, Dhaka, Bangladesh
 3. Department of Surgery, Cancer Research Institute, Dhaka, Bangladesh
 4. Department of Surgery, Tokyo Metropolitan Police Hospital, Tokyo:

a highly safe and effective means of treating gallbladder diseases, especially cholelithiasis. For decades, the novel procedure has shown superiority regarding safety, efficacy and morbidity. Laparoscopic cholecystectomy is the milestone, which opened a new era in the field of general surgery. In 1987 P. Muret¹ and his colleagues in France performed the first complete removal of a diseased gallbladder in a patient by laparoscopic procedure. The procedure has rapidly evolved as the most appropriate therapeutic modality for the treatment of gallbladder diseases in the developed countries throughout the world. Bangladesh has also seen the introduction of this highly sophisticated procedure which is a landmark in her medical history. The first two demonstrative cases of laparoscopic cholecystectomies were performed at the end of 1991 by our group in Dhaka. From April of 1993 we have started this procedure regularly at two hospitals in Dhaka, Bangladesh. We have applied pneumoperitoneum and abdominal wall lifting by subcutaneous wiring for making the operative space inside the abdomen. There was no case selection for the methods: we randomly performed laparoscopic cholecystectomy with pneumoperitoneum in one hospital and with abdominal wall lifting without pneumoperitoneum in another. There was no significant difference in average operative time and the quality of operative view was almost the same. However, the risks of complications of pneumoperitoneum were completely eliminated by the newer procedure of abdominal wall lifting. The running cost of the operation was also significantly reduced by the lifting method. Of the reported complications of laparoscopic cholecystectomy we have encountered none in our series.

Patient Selection, Preoperative Investigation, Operative Procedure

Though the indications for laparoscopic cholecystectomy are essentially the same as open cholecystectomy, we avoided the patients with active inflammation and common bile duct (CBD) stones. An ultrasonography and an oral cholecystography or intravenous drip infusion cholangiography are recommended for preoperative evaluation. Suspected common bile duct stone can be evaluated by ERCP* and managed by removal of stone with endoscopic papillotomy^{2,3,4}.

Since the procedure is a unique combination of modern video and camera technology with sophisticated surgical techniques, a full set up with camera, video system and monitors is essential to go for this surgery (Fig. 1). Also a full set of specially designed equipments for this procedure is necessary, with special sterilization techniques.

General anesthesia is administered via endotracheal intubation. Adequate muscle relaxant is administered to facilitate the abdominal wall lifting or pneumoperitoneum, which is considered as the very first step of any laparoscopic procedure. Abdominal wall lifting or pneumoperitoneum is performed to make the adequate space inside the abdomen to perform the surgical maneuvers for cholecystectomy.

Pneumoperitoneum is achieved by an automatic machine which provides us the space in the abdomen to perform the procedure by peritoneal insufflation by CO₂ gas into the

* ERCP - Endoscopic Retrograde cholecysto-pancreaticography.

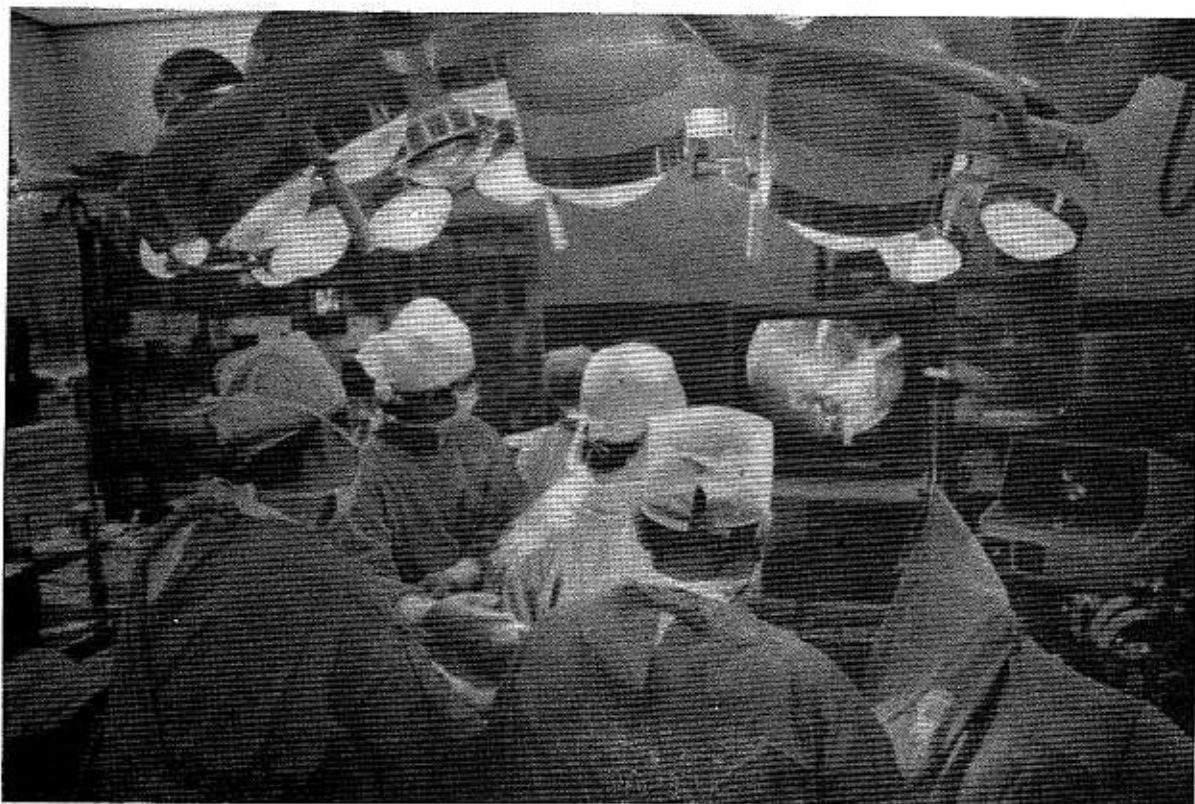

Fig. 1: Operation room set up; the monitor is placed in front of the surgeon and the assistants.

peritoneal cavity. The intraabdominal pressure is automatically regulated for maintaining a constant pressure during pneumoperitoneum. A high flow insufflating capacity is also required for a quicker attainment of pneumoperitoneum. In a supine position after the induction of general anesthesia, painting and drapping, the patient is brought into Trendelenburg's position and a veress needle is introduced through a small incision just below the umbilicus. Then pneumoperitoneum is created by insufflating CO₂ gas and an intra-abdominal pressure of 12 mm of Hg is achieved.

We^{5,6} devised an alternative method to make the same room by lifting up the abdominal wall, by the help of subcutaneous wires and thick sutures. Two 30 cm long and 2-3 mm diameter strong stainless steel wires were passed under the skin, one parallel to the right costal margin and another transversely above or below the umbilicus. Then lifting of the anterior abdominal wall was done by anterior, upward and little outward traction of these rods using No.-5 Ethibond suture and the traction was maintained by the help of hooks, an arch and clamp bars used in Kent extension retractor set for open abdominal surgery (Fig. 2). A fairly good room is produced intraabdominally which was enough for performing the cholecystectomy procedure.

The operation is performed through four small punctures (Fig. 3). A 10 mm trocar is introduced through the umbilicus through which the telescope is inserted and the intra-

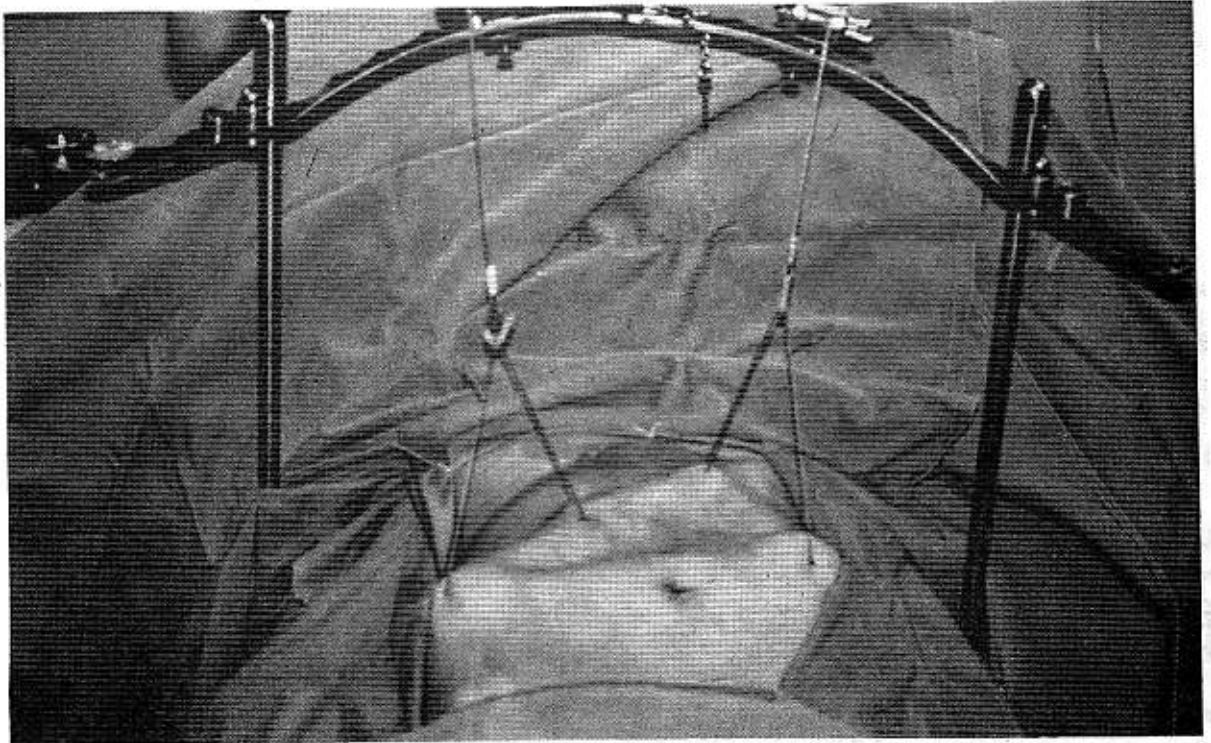


Fig. 2 : Abdominal wall lifting for creating the space inside the abdomen

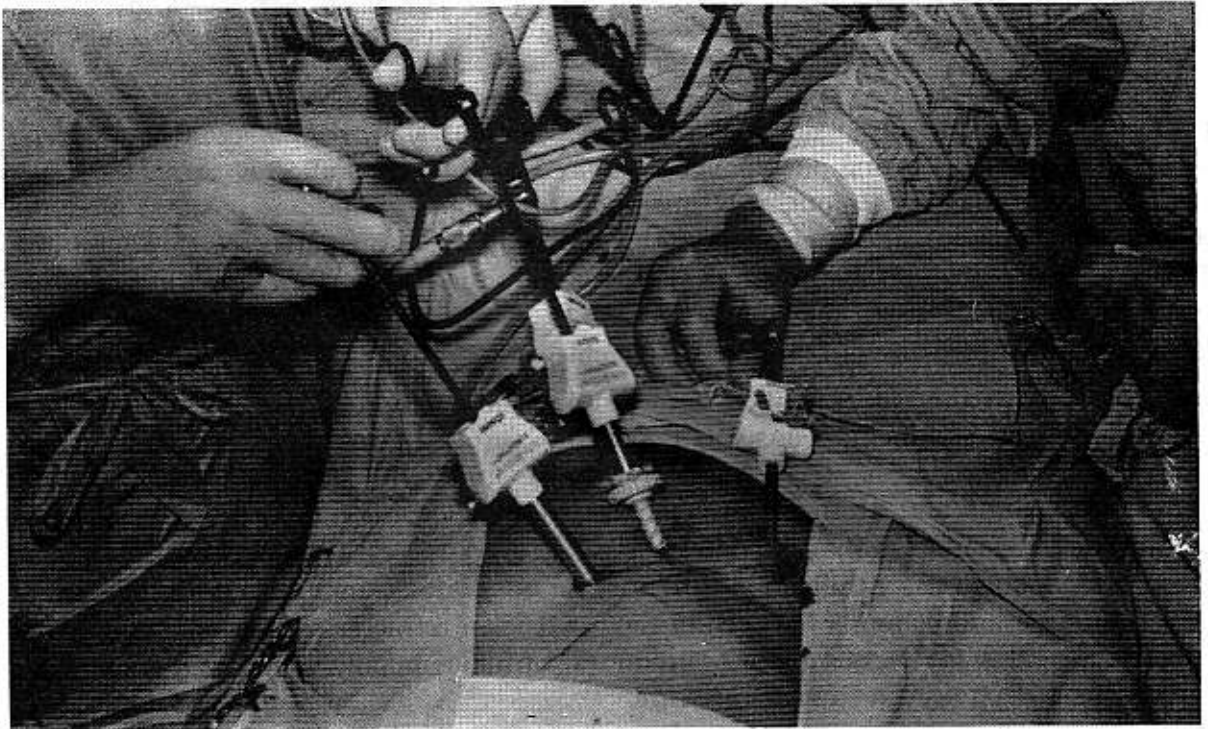


Fig. 3 : Four trocars in the abdominal wall, allowing the entry into the abdomen for operative maneuvers

abdominal view is found in the monitors (Fig. 4). After a circular inspection of the intra-abdominal structures and the gallbladder, other three trocar are inserted under direct observation in the monitors. Two 5 mm trocars are inserted in the midclavicular line two finger widths beneath the right costal margin and in the anterior axillary line three finger widths beneath the right costal margin. The second 10 mm trocar is inserted in 1/3rd distance between the xiphoid and the umbilicus just to the right of the midline.

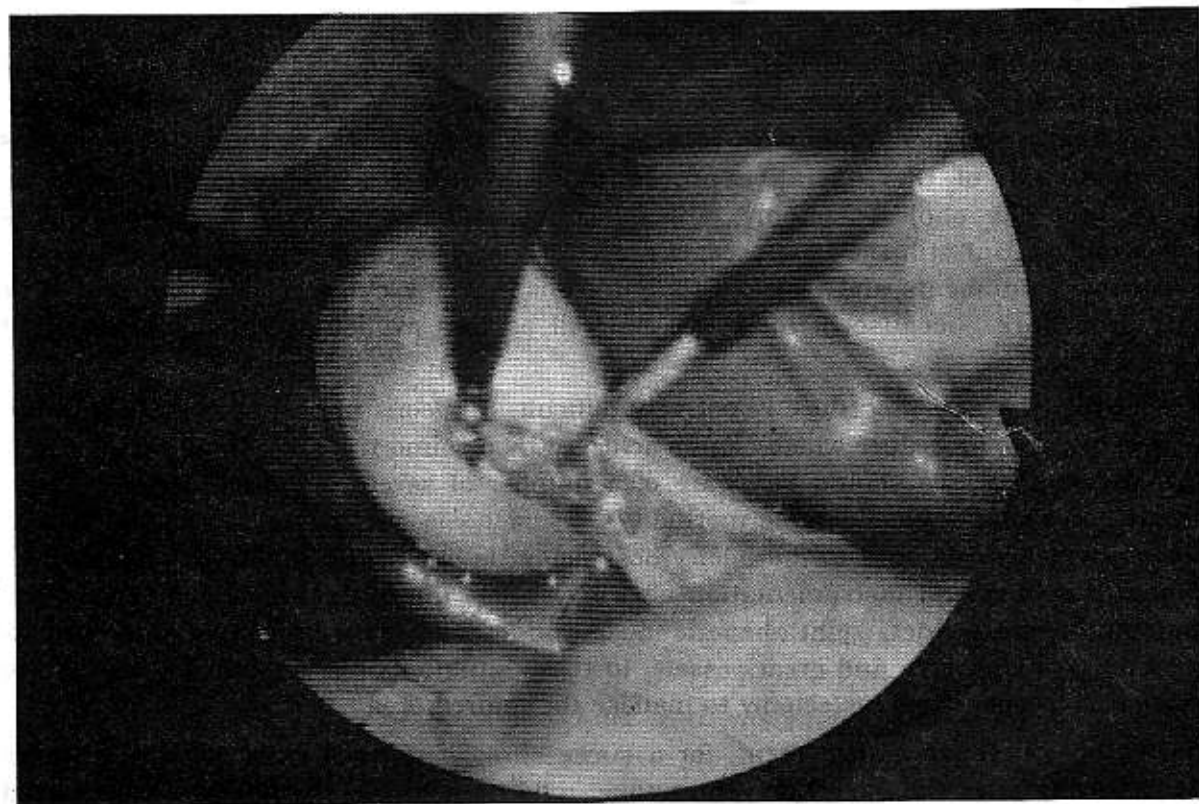


Fig. 4 : Laparoscopic view of the neck of the gallbladder in the monitor.

Keeping the fiberscope in the umbilical trocar and lifting and pushing the gallbladder fundus by an atraumatic forceps through the lateral (anterior axillary) portal, dissection and cleaning of the cystic duct and artery is performed using some especially designed instruments through the other two trocars. The next step is clipping the artery and duct and resection in between the clips. After resection of the duct and artery the gallbladder is freed from its liver bed in a retrograde manner either using simple electrocautery or blunt dissection. At the final stage the gallbladder was removed by the jaws forceps through the umbilical trocar under monitoring from inside through the midline trocar.

After confirming a complete hemostasis, small incisions are closed using one or two sutures in the peritoneum and muscle without any skin suture^{7,8}.

Discussion

Laparoscopic cholecystectomy is probably the best suited procedure among all endoscopic operations to receive a world wide acceptance. Though the procedure is very new and time has not come to comment on the safety, effectivity and also on the long term postoperative course of the procedure, it has gained a very high rate of popularity among surgeons and patients^{9,10}.

Excellent quality video camera, monitoring and high volume insufflator are among the most important equipments which made laparoscopic surgical procedures possible to perform successfully. Instead of a direct visualization with a long incision, two dimensional video monitoring of the operative field with a less invasive portal of entry is the main aim of this operative procedure and became widely preferred in some operations like cholecystectomy, appendectomy, adhesiolysis etc. because of less invasiveness. But still the laparoscopic procedure needs a number of sophisticated and expensive equipments and restricts the surgeons of many clinics to start and perform this procedure because of high cost as well as less availability of many essential equipments.

Technically the new procedure is not very difficult. Surgeons need an orientation before performing this procedure which can be achieved by a sound training. Though it is a less invasive surgery, we should be aware of a number of severe operative complications. These can cause a considerable morbidity. Misdiagnosis of the anatomy of the biliary system which might lead to the biliary obstruction is one of the serious complications. Trocar insertion and instrumentation also may cause injury to the common bile duct, common hepatic duct, right hepatic duct and other organs like liver, intestine & mesentery, diaphragm and great vessels. In these situations one should not hesitate to convert it to open cholecystectomy to manage the injured organ.

As for postoperative management, for a successfully performed case, patient recovers dramatically after the operation. Some time, mild pain in the wounds are experienced which even does not require any analgesic. In pneumoperitoneum cases, mild shoulder pain can be experienced due to stressing of the diaphragm, which recovers with mild dose of analgesic.

In conclusion this new treatment procedure for gallbladder disease will certainly take its place as the treatment of choice in the near future. It will in course reduce the morbidity, hospital cost as well as overloading pressure on the surgical departments in a country like Bangladesh.

References

1. Philippe Mouret et al. Laparoscopic cholecystectomy in human. Personal communication, France, 1987
2. Fitzgibbons RJ Jr, Schmid S, Santocoy R, Hinder R, Filipi CJ et al. Laparoscopic cholecystectomy : The beginning of a new era in general surgery (submitted for publication).

3. Filipi CJ., Fitzgibbons RJ, Salerno, GM, Historical Review : Diagnostic laparoscopy to laparoscopic cholecystectomy and beyond. Surgical Laparoscopy, Zucker KA (ed). pp. 3-21 1991.
1. Dubois F, Icard P, Berthelot G, Levard H. Coelioscopic Cholecystectomy. Ann Surg 1 : 60-62, 1990.
5. Hashimoto D, Nayeem SA, Kajiwara S, Hoshino T. Laparoscopic Cholecystectomy. An approach without pneumoperitoneum. Surg Endosc 7 : 54-56, 1993.
6. Hashimoto D, Nayeem SA, Kajiwara S, Hoshino T. Laparoscopic Cholecystectomy : A New Approach Without Pneumoperitoneum. (Abstract) SAGES Program, p 59 1992.
7. Reddick EJ, Olsen DO. Laparoscopic laser cholecystectomy. Surg Endosc 3 : 131-33, 1989.
8. Reddick EJ, Olsen DO. Outpatient laparoscopic laser cholecystectomy. Am J Surg 160 : 85-89, 1990.
9. Zucker KA, Bailey RB, Gadacz TR, Imbembo AL. Laparoscopic guided cholecystectomy. Am J Surg 161 : 36-44, 1991.
10. Phillips E, Daykhovsky L, Carrol B, et al. laparoscopic Cholecystectomy : Instrumentation and Technique. J Laparoscopic Surg 1 (1) : 3-15, 1990.

The Hippocratic Oath

I swear that I will follow that system of regimen which according to my ability and judgment, I consider for the benefit of my patients, and abstain from whatever is deleterious and mischievous. I will give no deadly medicine to any one if asked, nor suggest any such counsel; and in like manner I will not give to a woman a pessary to produce abortion. With purity and holiness I will pass my life and practise my art. I will not cut persons labouring under the stone but will leave this to be done by men who are practitioners of this work. Into whatever houses I enter, I will go into them for the benefit of the sick, and will abstain from every voluntary act of mischief and corruption. Whatever, in connection with my professional practice, or not in connection with it, I see or hear, in the life of men, which ought not to be spoken of abroad, I will not divulge, as reckoning that all such should be kept secret. While I continue to keep this Oath unviolated, may it be granted to me to enjoy life and the practice of the art, respected by all men, in all times: but should I trespass and violate this Oath, may the reverse be my lot.