

Case report

Oral myiasis: a case report

Sikder MA¹, Pradhan L², Ferdousi F³, Parvin MK⁴

Abstract

Oral Myiasis is a condition in which the soft tissues of different parts of oral cavity are invaded by the parasitic larvae of flies known as Maggots. This study presents a case of oral myiasis in 12 years old mentally retarded girl. Clinically, the patient had multiple perforations of the palatal mucosa at mid-hard palate and tunneling of the palatal gingivae from lateral incisor to the first molar on either side communicated to the palatal perforations. The patient was treated by mechanical removal of the maggots with simple curettage and irrigation with paraffin, povidone iodine and normal saline. After complete larvae removal, the wounds healed normally.

Key words: Oral myiasis, mentally retarded, fly larvae.

Introduction

The term myiasis (Greek: myi=fly) is used to refer the infestation of living tissues of humans and animals by eggs or larvae of house flies (diptera-two winged flies)¹. Oral myiasis was first described by Laurant in 1909². The most common anatomic sites for Myiasis are the nose, eye, lungs, ear, anus and vagina.³ The oral cavity is rarely affected by this infestation and is associated with poor oral hygiene, alcoholism, senility, suppurating lesions, severe halitosis and other conditions.⁴ Oral myiasis may present as an oral mucosal swelling, periodontal diseases, palatal swelling and ulceration. Secondary infestations may occur in cancrum oris, oral wounds such as extraction wound, jaw bone fractures, and oral leprosy lesion.

Depending on the conditions of the involved tissue, myiasis can be classified into 3 following categories: accidental myiasis; when larvae ingested along with food, semi-specific myiasis; where the larvae are laid on necrotic tissue of the wound, and obligatory myiasis; in which larvae affects undamaged skin.⁵ Myiasis can be classified clinically as primary; when larvae feed on the living tissue, secondary; when larvae feed on dead tissue.⁶

Maggots produce irritation, sneezing, itching, headache and lacrimation. Patients are also seen with oozing bloody discharge from nostrils. Some time larvae come out crawling out from nose or oral

cavity. They cause extensive damage to soft tissue, death may occur due to meningitis.

In our case report we presenting a rare case of Oral Myiasis in 12 years old mentally handicapped girl who visited to the department of Oral and Maxillofacial Surgery, Bangabandhu Sheikh Mujib Medical University and have received a subsequent management as described in detail.

A 12 years old girl, Kamrun Nahar visited to the department of Oral and Maxillofacial Surgery, BSMMU, on 16 october,2010. The patient was mentally retarded. She had a poor oral hygiene with multiple carious molars in all four quadrants. She was relatively well 5 days back. One day her parents noticed a live maggot exposing (crawling) from the palatal gingival sulcus. Her parents thus have removed 5-6 maggots then after.

On clinical examination, there was a perforation of the palatal mucosa at the mid-hard palate. The palatal gingivae was detached from the underlying alveolus from lateral incisor to the first molar on either side and was tunneled submucosally with the palatal perforation. The affected gingival and palatal mucoperiosteum was erythematous and edematous. The palatal perforation was about 2cm * 2cm in diameter. The oral hygiene was poor with multiple carious molar teeth on all four quadrants. The patient was a habitual mouth breather.

1. *Morshed Asadullah Sikder, Medical Officer,

2. Leeza Pradhan, Resident,

3. Fahmida Ferdousi, Resident,

4. Mahbuba Kafia Parvin, Medical officer,

Oral-Maxillofacial Surgery, Bangabandhu Sheikh Mujib Medical University.

*Corresponds to: Morshed Asadullah Sikder, Medical Officer, Oral-Maxillofacial Surgery, Bangabandhu Sheikh Mujib Medical University, Email: drmatanvir@yahoo.com.

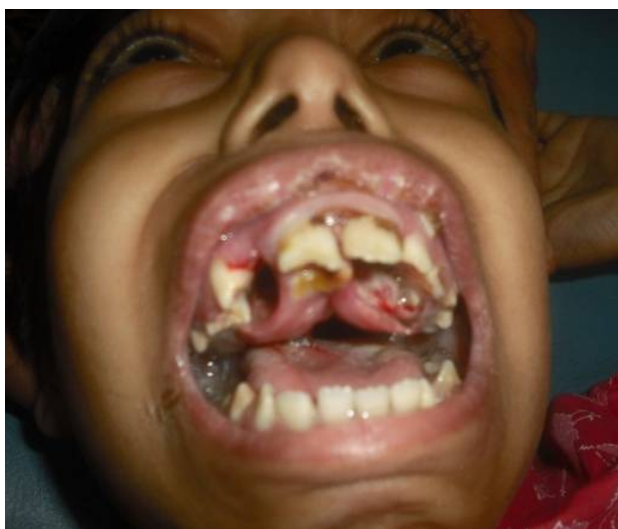

Figure 1A: Appearance of the patient at presentation

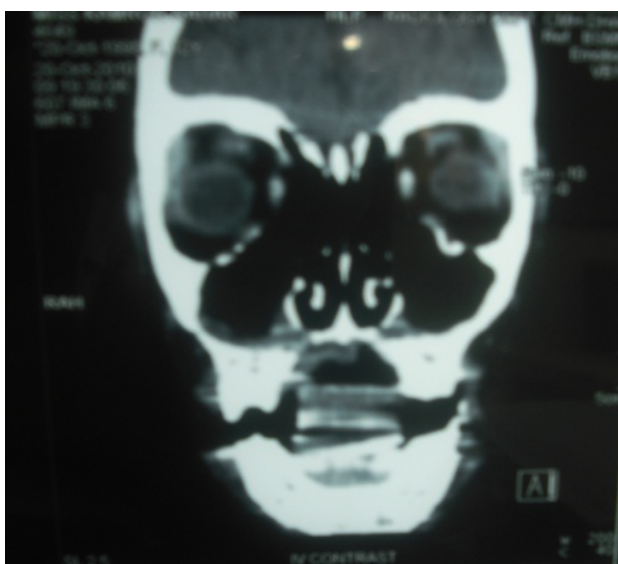


Figure 1B: CT scan of the PNS

Case Report

Orthopantomogram, X-ray PNS and later on Computed tomogram of the Maxillofacial skeleton revealed no changes in the bony structure.

The treatment was mechanical removal of the maggots after paraffin irrigation and curettage. On the first visit, 20 maggots were removed. On the second and third visits 5 maggots and 2 maggots were removed respectively. Further three more visits were made, where in each visit the wound was curetted and irrigated with liquid paraffin, povidone iodine and normal Saline. During the treatment period, the patient was prescribed Cefixime capsule 200mg for 7 days, Metronidazole tablet 200 mg for 7 days and

Chlorhexidine mouth wash. The parents were strictly instructed on proper mouth rinsing and tooth brushing of the patient.

Follow up examination on the 6th visit (28 October, 2010), revealed decrease in the gingival and palatal swelling and near complete reduction of palatal perforation with reattachment of the palatal gingivae and mucoperiosteum.

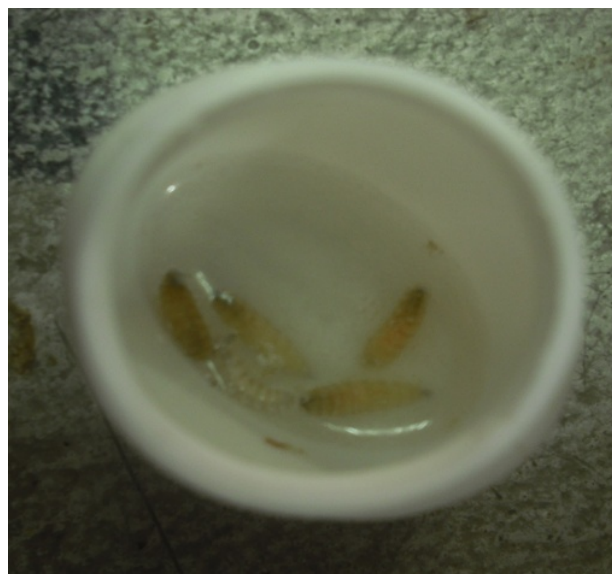

Figure 2A: Larvae removed from the wound

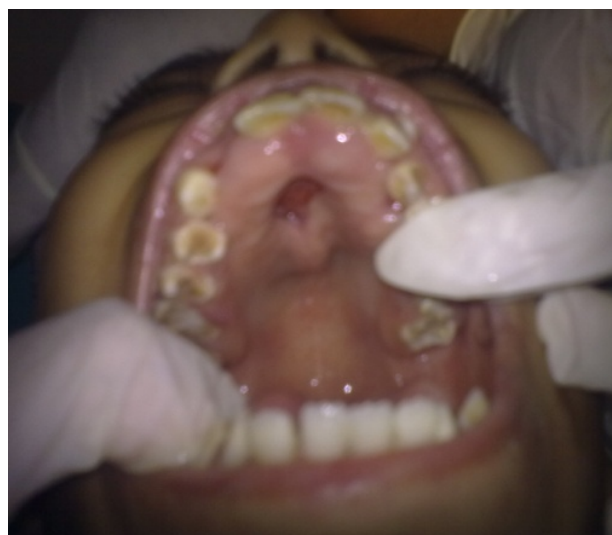


Figure 3A: Appearance of the wound on 6th visit

Discussion

Maggots are generally attracted toward foul smell of damaging tissues. The flies lay around 200 eggs at a time, larvae comes out within 24 hours; however patient is not aware of these till 3rd and 4th day. The larvae obtain nutrition from the surrounding tissues and burrow deeper into the soft

tissues by making multiple tunnels, then separated periosteum and gingivae from the bone.

The most frequently involved cases of oral myiasis are reported as being habitual mouth breathers, alcoholism, senility, mentally handicapped and cerebral palsy patients.⁷

Cases of oral myiasis have also been reported in epileptic patients with lacerated lips, children with incompetent lips and thumb sucking habits,⁸ patients with advanced periodontal disease⁹ and infected extraction wound.⁴ Ng, et al. (2003)¹¹ reported a case of oral myiasis in a woman with a history of ischaemic heart disease, pulmonary tuberculosis and a stroke which has resulted her being bed-ridden and dependent on nasogastric tube feeding.

Low socioeconomic status, immunocompromised state, debilitated and unhygienic living conditions are the main contributing factors responsible for myiasis. The risk factors for oral myiasis include suppurative lesions, facial trauma, mouth-breathers, extraction wounds, fungating carcinomas and others conditions.¹¹

There were several predisposing factors for the patient in this present study to be affected by this rare infestation. The patient was mentally handicapped, a habitual mouth breather and had a

poor oral hygiene with the lack of self-care ability and communication capacity.

The traditional management of myiasis is the mechanical removal of the maggots.⁴ Topical application of several substances like gentian violet,⁴ white head varnish¹⁰ has been used to compel any maggots, if present to come out of the lesion. In addition, systemic treatment with Ivermectin, a semi-synthetic macrolide antibiotic, has been used for treatment of oral myiasis.⁴ However, in the present case the patient was managed by mechanical removal of maggots, proper irrigation of the wound with paraffin, povidine iodine solution and normal saline and systemic treatment with Cefixime. Such a treatment proved to be effective with complete healing occurring by the end of about 2 weeks.

Conclusion

Mental retardation is a predisposing factor for oral myiasis in our case. Oral Myiasis is a very rare infestation occurring in human which can be prevented by education and awareness regarding maintenance of oral hygiene and the predisposing factors for the occurrence of the infestation. Early management is possible and needed to avoid life threatening conditions. So special care should be taken for mentally retarded person as they are more susceptible to be infested by oral myiasis.

References

1. Millikan LE. Myiasis. *Clin Dermatol* 1999; 17:191-5. [http://dx.doi.org/10.1016/S0738-081X\(99\)00011-5](http://dx.doi.org/10.1016/S0738-081X(99)00011-5).
2. Laurance SM. Dipterous larvae infection, *BMJ*, 1909; 9: 88.
3. Hall MJR, Wall R. Myiasis of Humans and Domestic Animals. *Adv Parasitol* 1995; 35:257-334. [http://dx.doi.org/10.1016/S0065-308X\(08\)60073-1](http://dx.doi.org/10.1016/S0065-308X(08)60073-1).
4. Abdo EN, Sette-Dias AC, Comunian CR, Dutra CEA, Aguiar EG. Oral myiasis: A case report. *Med Oral Patol Oral Cir Bucal* 2006; 11:E130-1. PMID:16505789.
5. Erfan F, Gingival myiasis caused by dipteral (sarcophaga) *Oral Surg Oral Med Oral pathol* 1980;49:148-150. [http://dx.doi.org/10.1016/0030-4220\(80\)90307-2](http://dx.doi.org/10.1016/0030-4220(80)90307-2).
6. Jyothi S, Gowda PM, Rachana A, Primary oral myiasis: a case report. *Med Oral Patol Oral Cir Bucal* 2008;1:13(II): E 714-6.
7. Moshref M, Ansari G, Lotfi A. Oral Gingival Myiasis: A Case Report 2008; *International Journal of Tropical Medicine* 3(4):97-100.
8. Shah HA, Daya PK. Dental Myiasis. *J. Oral Med.* 1984; 39:210-211. PMID:6594460.
9. Grennans S, Gutierrez Y. Diagnostic pathology of parasitic infections with clinical correlations. Philadelphia and London: Lea and Febiger 1990; 486-496
10. Ng KHL, Yip KT, Choi CH, Yeung KH et al. A case of oral myiasis due to *Chrysomya bezziana*. *Hong Kong Med J* 2003; 9:454-6. PMID:14660813.
11. Sankari LS, Ramkrishnan K. Oral myiasis caused by *Chrysomya bezziana* *J Oral Maxillofac Pathol* 2010;14:16-8. <http://dx.doi.org/10.4103/0973-029X.64304>. PMID:21180453. PMCid:2996000.