

Spontaneous Biliary Duct Perforation: Uncommon Diagnosis Using Cholescintigraphy

Sirajum Munira, Farzana Rahman, Rumana Parveen, Urnas Islam, Nasreen Sultana
National Institute of Nuclear Medicine and Allied Sciences (NINMAS), Dhaka, Bangladesh

Correspondence Address : Dr. Sirajum Munira, Phase-B MD Resident (Nuclear Medicine), NINMAS, Block-D, BSMMU Campus, Shahbag, Dhaka-1000. E-mail: smunira.02@gmail.com

ABSTRACT

Spontaneous bile duct perforation causing biliary peritonitis in children is an exceedingly rare occurrence. This condition poses an uncommon and potentially hazardous reason for acute abdominal symptoms. A pre-surgical diagnosis remains a rarity. We present a case of a five-month-old infant displaying gradual fever, jaundice, pale-colored stool, and abdominal distension for 12 days who was referred to NINMAS for a ^{99m}Tc -HIDA scan to investigate extrahepatic biliary atresia. The scan unveiled substantial radionuclide activity around the abdominal boundary in 2-hour, 4-hour, and 24-hour views, suggesting abnormal radioactivity in ascitic fluid due to bile leakage. Ultrasonography at NINMAS revealed a contracted gallbladder and moderate ascites. This study reviews and discusses the pathogenesis of this condition.

Keywords: Extrahepatic biliary atresia, ^{99m}Tc -HIDA scan, Bile duct perforation, Bile peritonitis, Biliary ascites.

Bangladesh J. Nucl. Med. Vol. 26 No. 2 July 2023
DOI: <https://doi.org/10.3329/bjnm.v26i2.71475>

INTRODUCTION

Neonatal spontaneous biliary perforation (NSBP), though relatively rare, is a critical cause of infantile jaundice that demands immediate diagnosis and surgical intervention (1). Bile leakage into the peritoneal cavity in infants and

children, unrelated to trauma, is not well-documented. Typically, this condition involves the escape of bile from a peritoneal cavity collection, resulting from the rupture of an extrahepatic biliary system component. Since such extrahepatic bile duct perforation causing biliary ascites in infants is uncommon, its recognition usually occurs only during surgery. Ascites and jaundice appearing in an otherwise healthy baby should raise suspicion (2, 3). In many cases, the combined use of abdominal ultrasonography and hepatobiliary scintigraphy aids in diagnosis, often avoiding the need for invasive procedures (4). Conservative surgical intervention with leak correction is the preferred approach, generally resulting in a favorable long-term prognosis (5)

CASE REPORT

A five-month-old baby presented symptoms of fever, jaundice, pale-colored stool, and abdominal distension for 12 days and was referred from Sir Salimullah Medical College Hospital to NINMAS for a Tc-^{99m} HIDA scan to rule out extrahepatic biliary atresia. There was no history of direct or indirect trauma or prior surgical procedures.

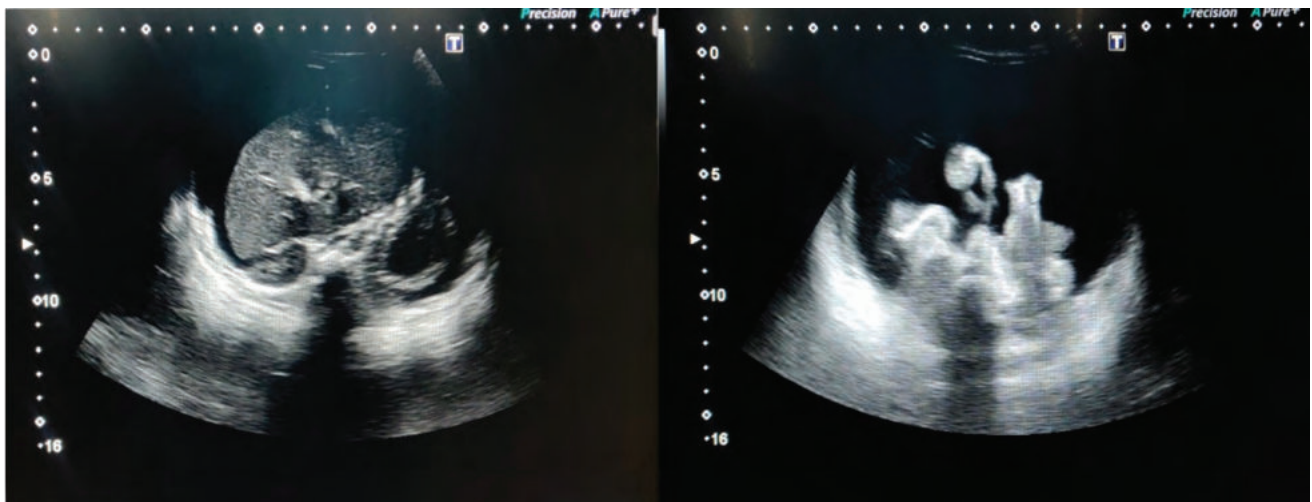


Figure 1: Ultrasound image displaying extensive ascites throughout the abdomen.

Serology for HBsAg and HIV was negative. Blood tests revealed elevated direct serum bilirubin, total serum bilirubin, serum alkaline phosphatase, SGPT, serum albumin, LDH, and GAMMA-GT levels. An ultrasound on November 3, 2022, showed a contracted gallbladder and moderate ascites. Subsequent ultrasounds on November 15, 2022, revealed significant ascites and a contracted

gallbladder (Figure 1). The Tc-99m HIDA scintigraphy exhibited considerable radionuclide activity around the abdominal boundary in 2-hour, 4-hour, and 24-hour views, suggestive of abnormal radioactivity presence in ascitic fluid, possibly due to bile leakage (Figure 2). Unfortunately, the baby did not survive; severe peritonitis led to the baby's demise before any surgical intervention could be initiated.

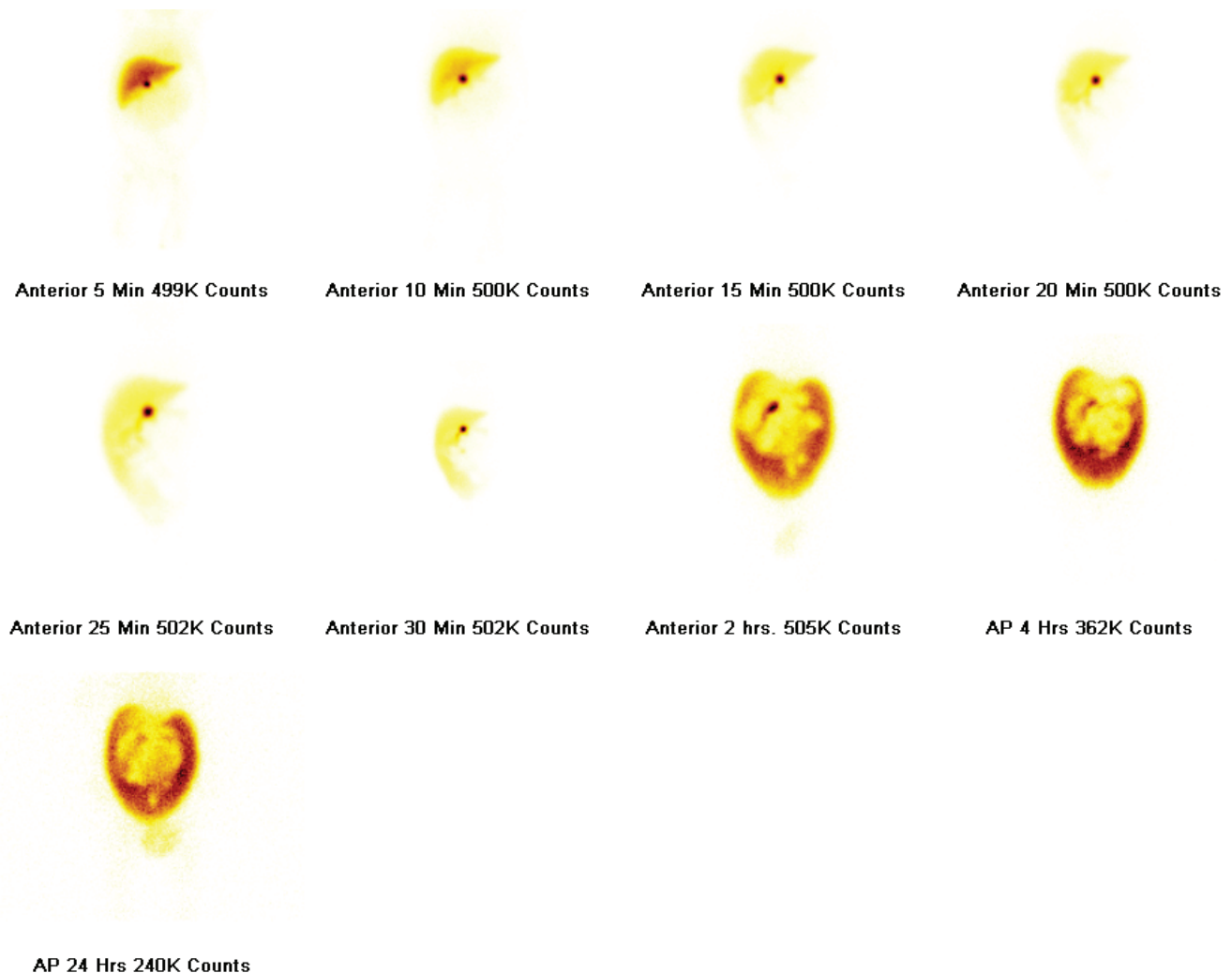


Figure 2: ^{99m}Tc - labeled HIDA scintigraphy scan showing significant radionuclide activity along the boundary of abdomen in 2 hrs, 4 hrs and 24 hrs views.

DISCUSSION

The precise etiology of spontaneous bile duct perforation (SPBD) remains unknown. Possible causes include biliary tract anomalies, trauma, ascariasis, and cholecystitis. The most common site of perforation is where the cystic and common bile ducts converge, often attributed to congenital weakening of the bile duct, possibly from a developmental mural malformation at this juncture. This weakness is likely

linked to ischemia of the bile duct's anterior wall due to its limited arterial blood supply, contributing to its vulnerability. Other rare causes include anomalies such as abnormal pancreaticobiliary ductal union, distal blockages, stones, ductal atresia, stenosis, or inspissated bile. Antenatal bile duct perforation, though extremely rare, has been documented. Manifestations often include chronic biliary ascites, pale stools, abdominal distension, and jaundice.

In some cases, acute biliary peritonitis may occur, presenting with pain, nausea, vomiting, fever, and sepsis without jaundice (2, 6). Conjugated bilirubin levels may be normal or elevated with raised alkaline phosphatase and possibly moderate leukocytosis. Although diagnosis often occurs during exploratory surgery, clinical suspicion can lead to a pre-surgical confirmation, commonly aided by an ultrasound examination revealing intraperitoneal fluid alongside healthy ducts. Bile-stained fluid with high bilirubin levels is typically discovered during a paracentesis guided by ultrasound or CT scan. Hepatobiliary scintigraphy aids in identifying the source of fluid, particularly when CT and ultrasound detect fluid collections (7). The method has proven useful in accurately diagnosing extrahepatic bile duct leaks preoperatively. Similar case reports from the USA (2018) and India (2016, 2017) further illustrate instances of spontaneous biliary perforation diagnosed through various imaging modalities (8-10).

CONCLUSION

Spontaneous biliary perforation is an infrequent occurrence in newborns. Previous cases have shown that combining abdominal ultrasonography with a HIDA scan offers superior diagnostic imaging when SPBD is suspected. This combined approach may obviate the necessity for other, more invasive diagnostic procedures. The English literature has only recently documented a small number of SPBD cases in children. For select patients without distal blockage, successful management involves simple drainage with spontaneous closure. However, due to the condition's rarity and the wide array of surgical options available, an accurate preoperative diagnosis remains crucial. Early diagnosis and treatment are pivotal in reducing mortality and morbidity associated with this condition.

CONFLICT OF INTEREST

The authors declare that there is no conflict of interests regarding publication of this paper.

REFERENCES

1. Patel RV, Durell J, Dagash H, Patwardhan N. Neonatal spontaneous bile duct perforation presenting as giant intraabdominal cyst. *Journal of Pediatric Surgery Case Reports*. 2013 Mar 1;1(3):36-8.
2. Kasat LS, Borwankar SS, Jain M, Naregal A. Spontaneous perforation of the extrahepatic bile duct in an infant. *Pediatric surgery international*. 2001 Jul; 17:463-4.
3. Sahnoun L, Belghith M, Jallouli M, Maazoun K, Mekki M, Ben Brahim M, Nouri A. Spontaneous perforation of the extrahepatic bile duct in infancy: report of two cases and literature review. *European journal of pediatrics*. 2007 Feb;166(2):173-5.
4. Saltzman DA, Snyder CL, Leonard A. Spontaneous Perforation of the Extrahepatic Biliary Tree in Infancy: A Case Report. *Clinical Pediatrics*. 1990 Jun;29(6):322-4.
5. Smethurst FA, Carty H. Spontaneous perforation of the common bile duct in infancy. *The British Journal of Radiology*. 1993 Jun;66(786):556-7.
6. Goel P, Jain V, Manchanda V, Sengar M, Gupta CR, Mohta A. Spontaneous biliary perforations: an uncommon yet important entity in children. *Journal of clinical and diagnostic research: JCDR*. 2013 Jun;7(6):1201.
7. Flynt L, Grant P, Seitz JP, Qing F. Hepatobiliary scintigraphy of evolving spontaneous biliary leak. *Clinical nuclear medicine*. 2015 Jul 1;40(7):592-5.
8. Hopper L, Hao SB, Rodeberg D, Longshore S. Spontaneous bile duct perforation in a neonate. *Journal of pediatric surgery case reports*. 2018 Nov 1;38:57-60.
9. Chauhan S, Pandit AG, Jacob MJ, Kumar P. Spontaneously ruptured choledochal cyst: Rare diagnosis on hepatic scintigraphy. *Indian Journal of Nuclear Medicine: IJNM: The Official Journal of the Society of Nuclear Medicine, India*. 2011 Jul;26(3):157.
10. Sood A, Parihar AS, Thapa BR, Kanojia RP, Mittal BR, Bhattacharya A. Hepatobiliary scintigraphy findings lead to the diagnosis of spontaneous common bile duct rupture in an infant. *Clinical nuclear medicine*. 2017 Mar 1;42(3):223-4.