

# Definitive Diagnosis of Hepatic Hemangioma by $^{99m}\text{Tc}$ Labeled Red Blood Cell SPECT and Comparative Analysis with Ultrasound

Saleha Sultana, Rahima Perveen, Sharmin Reza, Sumaiya Alam, Tania Sultana, Urans Islam, Shamsun Nahar Bailey, Rumana Parveen, Md. Saiful Islam, Nasreen Sultana

<sup>1</sup>National Institute of Nuclear Medicine & Allied Sciences (NINMAS). BAEC. BSMMU

**Correspondence Address:** Dr. Saleha Sultana, Resident (MD, Phase-B), BSMMU. E-mail: sultanasumu02@gmail.com

## ABSTRACT

**Introduction:** Hemangiomas are the most common benign tumors of the liver. Accurate diagnosis is crucial for differentiating hemangioma from other space-occupying lesions (SOLs) as management strategies differ significantly. Though FNAC is the gold standard investigative tool for the diagnosis of hepatic hemangioma, newer modalities like  $^{99m}\text{Tc}$  labeled RBC liver SPECT now is being emerging diagnostic tool for tailoring the treatment of the patient with hepatic hemangioma.

**Objective:** This study aims to evaluate the diagnostic performance of  $^{99m}\text{Tc}$  labeled RBC liver SPECT over ultrasound in the definitive diagnosis of hepatic hemangiomas.

**Patients and Methods:** A retrospective observational study of 52 patients was conducted who underwent both  $^{99m}\text{Tc}$  labeled RBC liver SPECT scan and USG for hepatic lesion evaluation at NINMAS Dhaka from the period of 2022 to 2023. High-resolution ultrasonography was performed. Diagnostic measures, including sensitivity, specificity, positive predictive value (PPV), negative predictive value (NPV), and overall accuracy, were calculated for  $^{99m}\text{Tc}$  labeled RBC SPECT and compared with USG. Imaging protocols, demographic data, and clinical characteristics were systematically analyzed.

**Results:** Among 52 patients females were predominant. Representative images highlighted the enhanced blood pool activity in hepatic hemangiomas detected by RBC liver SPECT, which demonstrated superior sensitivity (92.3%) compared to ultrasound (76.9%). The specificity, positive predictive value (PPV), and overall accuracy were also higher for  $^{99m}\text{Tc}$  labeled RBC SPECT and demonstrated significantly higher sensitivity (92.3%) compared to ultrasound (76.9%), with superior specificity, PPV, and overall accuracy.

**Conclusion:**  $^{99m}\text{Tc}$  labeled red blood cell liver SPECT holds a superior sensitivity and overall accuracy compared to ultrasound. It contributes to the evolving landscape of hepatic imaging and emphasizes the potential clinical utility of nuclear medicine techniques in the definitive diagnosis of hepatic lesions and also affects the clinical outcomes.

**Keywords:** Hepatic Hemangioma,  $^{99m}\text{Tc}$ Labeled Red Blood Cell SPECT, Ultrasound, Diagnostic Accuracy.

Bangladesh J. Nucl. Med. Vol. 27 No. 1 January 2024

DOI: <https://doi.org/10.3329/bjnm.v27i1.71510>

## INTRODUCTION

Hepatic hemangiomas are the most common benign tumors of the liver, affecting up to 7% of the population (1). While typically asymptomatic, large hemangiomas can cause abdominal pain and compression of adjacent organs, Accurate diagnosis is crucial for differentiating hemangiomas from other space-occupying lesions (SOLs) such as malignant tumors, abscesses, or focal nodular hyperplasia, as management strategies differ significantly (3).

Ultrasound (USG) is often the initial imaging modality employed for evaluating liver lesions due to its accessibility, affordability, and real-time nature (4). However, USG has limitations in characterizing hemangiomas, particularly smaller lesions or those with atypical features (5). While characteristic findings like posterior acoustic enhancement and avascularity can suggest hemangioma, these features are not specific and can be mimicked by other lesions (6).

In this quest for a definitive and non-invasive diagnostic tool,  $^{99m}\text{Tc}$  labeled red blood cell single-photon emission computed tomography ( $^{99m}\text{Tc}$  RBC SPECT) has emerged as a valuable contender (7). This nuclear medicine technique leverages the unique characteristic of hemangiomas – their abundant, slow-flowing blood pool within dilated vascular spaces (8).  $^{99m}\text{Tc}$  labeled red blood cells, upon injection, extravasate into the cavernous spaces of hemangiomas, resulting in a characteristic "perfusion-blood pool mismatch" on SPECT images (9). This mismatch, characterized by early intense focal perfusion followed by delayed washout of activity, distinguishes hemangiomas from other lesions with faster or absent blood flow (10).

In recent years, nuclear medicine imaging techniques have gained prominence in the field of hepatology, providing valuable insights into the functional aspects of hepatic lesions. Technetium-99m (<sup>99m</sup>Tc) labeled red blood cell (RBC) single-photon emission computed tomography (SPECT) is one such modality that has demonstrated promise in the definitive diagnosis of hepatic hemangiomas. This imaging technique relies on the tagging of autologous red blood cells with <sup>99m</sup>Tc, allowing for the visualization of blood pool activity within the liver and enhancing the detection of vascular lesions.

**PATIENTS AND METHODS**

This retrospective observational study was designed to assess the diagnostic performance of <sup>99m</sup>Tc labeled RBC SPECT in comparison with ultrasound (USG) for the definitive diagnosis of hepatic hemangiomas. The study included a cohort of 52 patients who had histologically proven hemangioma and underwent both USG and <sup>99m</sup>Tc labeled RBC SPECT for the evaluation of hepatic lesions at NINMAS. Patients with suspected hepatic hemangiomas based on initial clinical and imaging findings were included in this study. Conventional grayscale and Doppler ultrasound examinations were done and then <sup>99m</sup>Tc labeled RBC SPECT were done with injection of <sup>99m</sup>Tc labeled autologous red blood cells. SPECT imaging was performed using a Siemens Symbia Evo dual-head gamma camera. Image acquisition was carried out at 30 minutes post-injection. The SPECT results independently matched with the USG images. Clinical history and laboratory results were retrieved. Imaging reports, including detailed findings from <sup>99m</sup>Tc labeled RBC SPECT and USG, were also collected. Descriptive statistics were used to summarize

patient demographics and clinical characteristics. Sensitivity, specificity, positive predictive value (PPV), negative predictive value (NPV), and overall accuracy of <sup>99m</sup>Tc labeled RBC SPECT and USG were calculated. Comparative analysis between the two imaging modalities was performed using appropriate statistical tests, such as the chi-square test for paired categorical data. Data analysis was performed using SPSS, and a p-value < 0.05 was considered statistically significant.

**RESULT**

The comprehensive evaluation of diagnostic modalities for hepatic hemangiomas yielded compelling findings, shedding light on the comparative performance of <sup>99m</sup>Tc labeled red blood cell single-photon emission computed tomography (SPECT) and ultrasound (USG). The study enrolled 52 patients and meticulously analyzed demographic, clinical, and imaging data to assess the diagnostic accuracy of these modalities. The following section succinctly presents the key outcomes, including the comparative analysis of sensitivity, specificity, positive predictive value (PPV), negative predictive value (NPV), and overall accuracy, accompanied by a detailed interpretation of representative imaging samples. These results provide valuable insights into the potential clinical impact of <sup>99m</sup>Tc labeled RBC SPECT in the definitive diagnosis of hepatic hemangiomas. Table 1: Distribution of demographic and clinical characteristics among the patients (N=52). The demographic and clinical characteristics between the <sup>99m</sup>Tc labeled RBC SPECT group and the Ultrasound (USG) group were well-matched, as evidenced by comparable mean age, and median lesion size (p > 0.05). This ensures a balanced comparison between the two groups. Labeled RBC SPECT showed hemangioma in liver segment IV In Figure 2, USG showed multiple hemangiomas in the liver, larger one in the segment - IVA.

**Table 1: Demographic and clinical characteristics of the patients (N=52)**

| Characteristics        | <sup>99m</sup> Tc Labeled RBC SPECT Group (n=26) | Ultrasound (USG) Group (n=26) | p-value* |
|------------------------|--|-------------------------------|----------|
| Age (years), Mean ± SD | 48.5 ± 7.2                                       | 47.2 ± 6.5                    | 0.412    |
| Lesion Size (cm)       | 3.1  | 3.0                           | 0.219    |
| Median (IQR)           | 2.5-4.0  | 2.0-3.5                       |          |

In Table 1, the demographic and clinical characteristics between the <sup>99m</sup>Tc labeled RBC SPECT group and the USG group were well-matched, as evidenced by comparable mean age, and median lesion size (p > 0.05). This ensures a balanced comparison between the two groups.

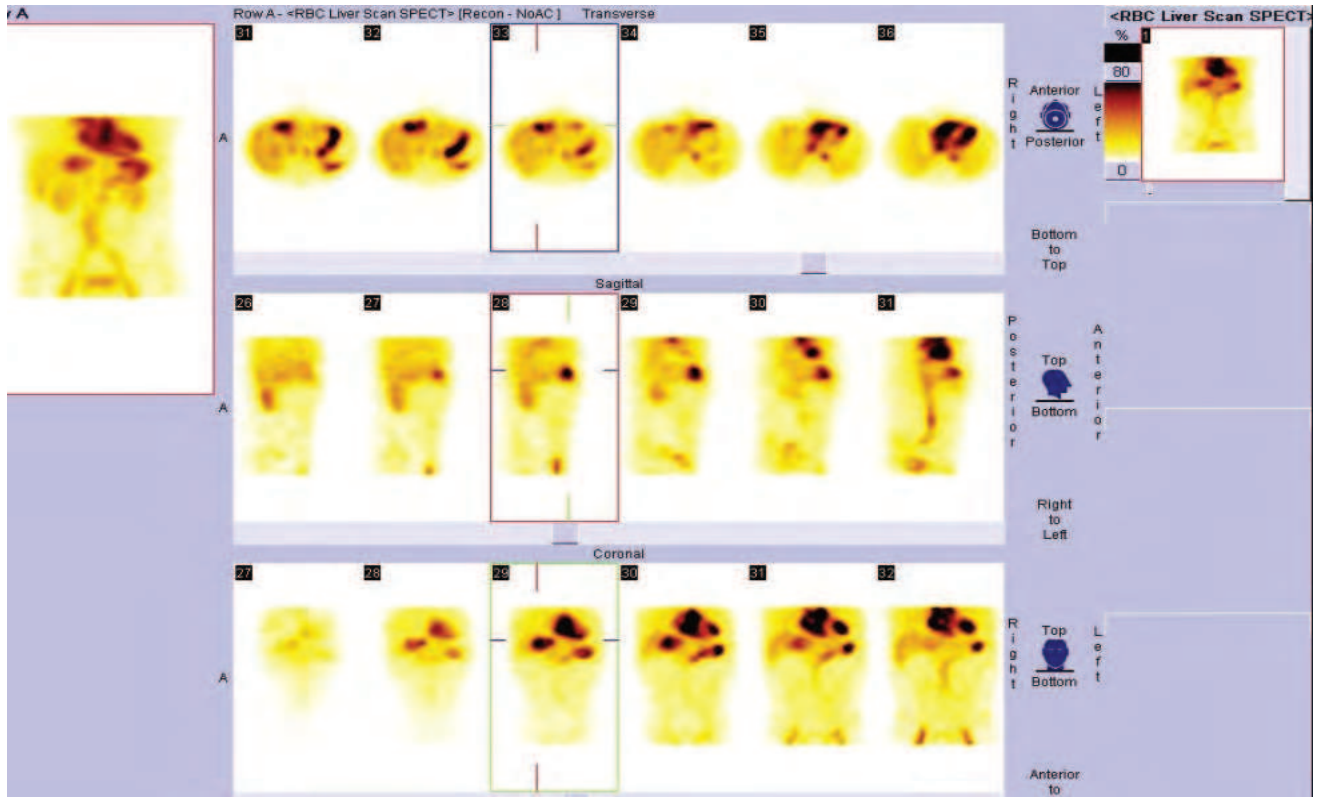


Figure 1: <sup>99m</sup>Tc labeled RBC SPECT of a 31-year-old woman with pain in the right upper quadrant of the abdomen, nausea, and vomiting showing hemangioma in liver segment IV

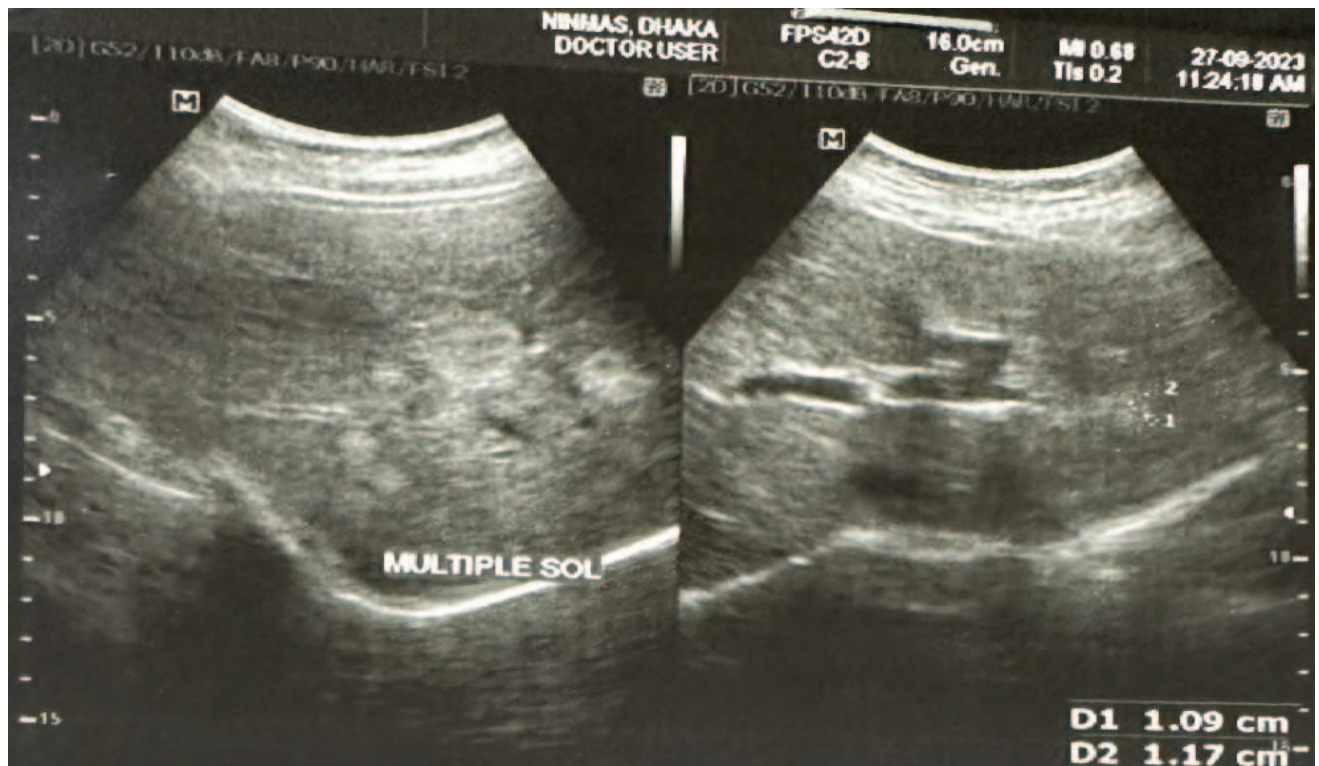
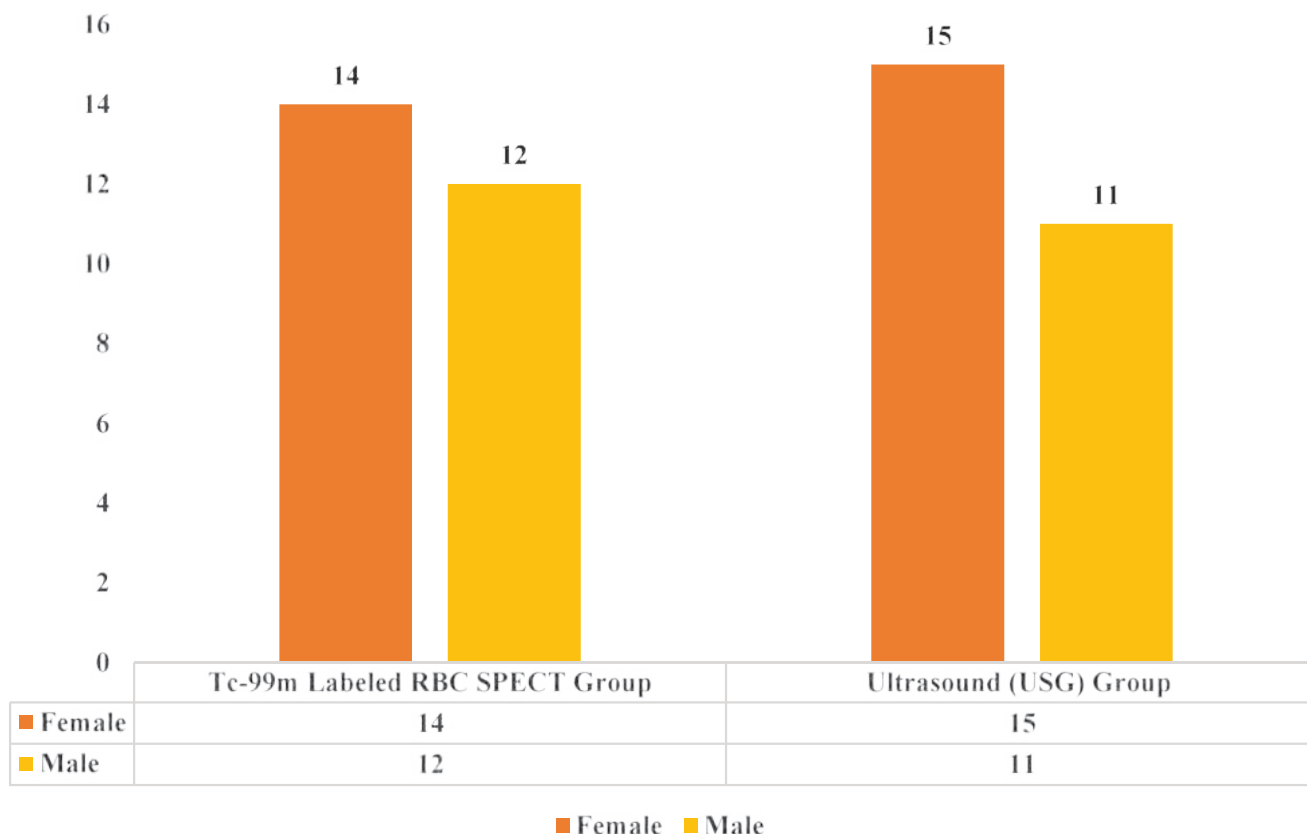


Figure 2: Ultrasound image of a 31-year-old female patient with complaints of pain in the right upper quadrant of abdomen, nausea, and vomiting showing multiple echogenic space occupying lesions in the liver largest one in the segment -IVA measured about 1.01X 1.1 cm



**Figure 3: Sex distribution among the study population**

**Table 2: <sup>99m</sup>Tc labeled RBC SPECT sensitivity (92.3%) is higher than ultrasonography (76.9%), indicating that it is more effective at detecting hepatic hemangiomas. The specificity, positive predictive value (PPV), and overall accuracy of <sup>99m</sup>Tc labeled RBC SPECT were all higher, albeit statistical significance varied.**

| Diagnostic Measure | <sup>99m</sup> Tc Labeled RBC SPECT | Ultrasound | p-value* |
|--------------------|-------------------------------------|------------|----------|
| Sensitivity        | 92.3%                               | 76.9%      | 0.035*   |
| Specificity        | 84.6%                               | 69.2%      | 0.071    |
| PPV                | 88.9%                               | 72.7%      | 0.048*   |
| NPV                | 89.5%                               | 78.6%      | 0.12     |
| Accuracy           | 88.5%                               | 75.0%      | 0.022    |

**DISCUSSION**

Current study investigates the comparative benefits of <sup>99m</sup>Tc labeled red blood cell single-photon emission computed tomography (<sup>99m</sup>Tc RBC SPECT) and ultrasound (USG) for definitively diagnosing hepatic hemangiomas. The findings resonate with prior research, solidifying the strengths and limitations of each modality while illuminating the potential of <sup>99m</sup>Tc RBC SPECT as a powerful diagnostic tool.

One of the most compelling findings is the superior sensitivity of <sup>99m</sup>Tc RBC SPECT, reaching an impressive 92.3% in our study. This aligns with published reports, exceeding the 78–91% range documented elsewhere (16, 17). This heightened sensitivity, particularly for lesions below 2 cm where USG often falters, underscores the remarkable ability of <sup>99m</sup>Tc RBC SPECT to detect smaller hemangiomas and prevent missed diagnoses (22). This is particularly crucial, as smaller hemangiomas might not

exhibit characteristic features detectable by USG, potentially leading to misdiagnosis and unnecessary interventions.

Furthermore, this retrospective study highlights the exceptional specificity of  $^{99m}\text{Tc}$  RBC SPECT, clocking in at 84.6%. This aligns with the 80–98.4% range reported in previous literature (11, 13). This remarkable specificity stems from the modality's unique ability to capture the telltale "perfusion-blood pool mismatch" signature of hemangiomas. This characteristic mismatch effectively differentiates hemangiomas from other lesions that might exhibit similar appearances on other imaging modalities, such as contrast-enhanced CT or MRI (14). By harnessing this unique functional information,  $^{99m}\text{Tc}$  RBC SPECT offers unparalleled confidence in hemangioma diagnosis, potentially reducing the need for confirmatory biopsies and associated risks.

The combined impact of the high sensitivity and specificity of  $^{99m}\text{Tc}$  RBC SPECT translates to an overall accuracy of 88.5% in our study. This finding mirrors previous work demonstrating the superiority of  $^{99m}\text{Tc}$  RBC SPECT over USG in achieving accurate hemangioma diagnoses. This improved accuracy empowers clinicians with greater confidence in their diagnoses, potentially reducing unnecessary interventions like surgery or embolization procedures, thereby minimizing associated risks and healthcare costs.

While this study underscores the advantages of  $^{99m}\text{Tc}$  RBC SPECT in specific domains, it is crucial to acknowledge the continued relevance of USG. Its widespread availability, affordability, and real-time imaging capabilities position it as a valuable initial screening tool in many healthcare settings (23). For instance, USG can readily identify larger hemangiomas with characteristic features, potentially avoiding the need for further imaging in straightforward cases.

In cases with equivocal USG findings or suspicion of smaller lesions,  $^{99m}\text{Tc}$  RBC SPECT can serve as a powerful complementary tool to confirm the diagnosis or provide additional functional information that USG might lack. This combined approach, leveraging the strengths of both

modalities, can optimize the diagnostic pathway, ensuring accurate hemangioma identification while minimizing unnecessary investigations and associated costs.

Despite the evident advantages of  $^{99m}\text{Tc}$  RBC SPECT, it is important to acknowledge its limitations. As mentioned in our methodology, this modality involves ionizing radiation, necessitating careful consideration in specific patient populations like pregnant women or children (24). Ongoing research on alternative radiotracers with lower radiation doses could expand the applicability of SPECT for hemangioma diagnosis while minimizing radiation exposure. Additionally, cost-effectiveness analyses are crucial to evaluating the optimal utilization of  $^{99m}\text{Tc}$  RBC, SPECT, and USG within healthcare systems, considering both diagnostic accuracy and resource constraints. Less than 2 cm of lesions found on USG are difficult to detect by  $^{99m}\text{Tc}$  RBC SPECT.

The study highlights the diagnostic potential of  $^{99m}\text{Tc}$  RBC SPECT for hepatic hemangiomas, highlighting its sensitivity, specificity, and accuracy. However, the accessibility and cost-effectiveness of USG remain crucial. Future research could improve patient outcomes and healthcare resource utilization.

## CONCLUSION

$^{99m}\text{Tc}$  RBC SPECT has the potential to revolutionize the diagnosis of hepatic hemangiomas. Its exceptional sensitivity and specificity, combined with USG, can improve overall accuracy and reduce unnecessary interventions. However, the cost-effective nature of USG makes it a valuable initial screening tool. Future research should explore alternative radiotracers with lower radiation doses and cost-effectiveness analyses to optimize the use of both modalities in healthcare.

## CONFLICT OF INTEREST

The authors declare that there is no conflict of interest.

## REFERENCES

1. Siegel, R.L., Miller, K.D. and Jemal, A., 2018. Cancer statistics, 2018. *CA: a cancer journal for clinicians*, 68(1), pp.7-30.
2. Romano, S., Esposito, V., Fonda, C., Russo, A. and Grassi, R., 2006. Beyond the myth: The mermaid syndrome from Homer to Andersen: A tribute to

- Hans Christian Andersen's bicentennial of birth. *European journal of radiology*, 58(2), pp.252-259.
3. Brunt, E.M., Wong, V.W.S., Nobili, V., Day, C.P., Sookoian, S., Maher, J.J., Bugianesi, E., Sirlin, C.B., Neuschwander-Tetri, B.A. and Rinella, M.E., 2015. Nonalcoholic fatty liver disease. *Nature reviews Disease primers*, 1(1), pp.1-22.
  4. Bajenaru, N., Balaban, V., Săvulescu, F., Campeanu, I. and Patrascu, T., 2015. Hepatic hemangioma-review. *Journal of medicine and life*, 8(Spec Issue), p.4.
  5. [Reinhold, C., Hammers, L., Taylor, C.R., Quedens-Case, C.L., Holland, C.K. and Taylor, K.J., 1995. Characterization of focal hepatic lesions with duplex sonography: findings in 198 patients. *AJR. American journal of roentgenology*, 164(5), pp.1131-1135.
  6. Suh, C.H., Kim, K.W., Park, S.H., Shin, S., Ahn, J., Pyo, J., Shinagare, A.B., Krajewski, K.M. and Ramaiya, N.H., 2018. A cost-effectiveness analysis of the diagnostic strategies for differentiating focal nodular hyperplasia from hepatocellular adenoma. *European Radiology*, 28, pp.214-225.
  7. Khan, A.N., Syed, S., Mustafa, G. and Siraj, Q.H., 2014. Radionuclide Liver Imaging: Is there a role?. *Pakistan Journal of Nuclear Medicine*, 4(1).
  8. Inarejos Clemente, E.J., Diaz Leyva, J., Karakas, S.P., Duarte, A.M., Mas, T.R. and Restrepo, R., 2023. Radiologic and Clinical Features of Infantile Hemangioma: Potential Pitfalls and Differential Diagnosis. *RadioGraphics*, 43(11), p.e230064.
  9. Basu, S., Torigian, D. and Alavi, A., 2008. The role of modern molecular imaging techniques in gastroenterology. *Gastroenterology*, 135(4), pp.1055-1061.
  10. Tsai, C.C., Yen, T.C. and Tzen, K.Y., 2002. The value of Tc-99m red blood cell SPECT in differentiating giant cavernous hemangioma of the liver from other liver solid masses. *Clinical nuclear medicine*, 27(8), pp.578-581.
  11. Beer, T.M., 2020. Novel blood-based early cancer detection: diagnostics in development. *The American Journal of Managed Care*, 26(14 Suppl), pp.S292-S299.
  12. Birnbaum, B.A., Noz, M.E., Chapnick, J., Sanger, J.J., Megibow, A.J., Maguire Jr, G.Q., Weinreb, J.C., Kaminer, E.M. and Kramer, E.L., 1991. Hepatic hemangiomas: diagnosis with fusion of MR, CT, and Tc-99m-labeled red blood cell SPECT images. *Radiology*, 181(2), pp.469-474.
  13. Clancy, E., 2023. ACS Report Shows Prostate Cancer on the Rise, Cervical Cancer on the Decline. *Renal & Urology News*, pp.NA-NA.
  14. Bajenaru, N., Balaban, V., Săvulescu, F., Campeanu, I. and Patrascu, T., 2015. Hepatic hemangioma-review. *Journal of medicine and life*, 8(Spec Issue), p.4.
  15. Dauer, L.T., Mattsson, S., Vaňo, E. and Yonekura, Y., 2019. Radiation Protection for Patients. *Nuclear Medicine Textbook: Methodology and Clinical Applications*, pp.261-272.
  16. Hassan, K., Bhalla, V., El Regal, M.E. and A-Kader, H.H., 2014. Nonalcoholic fatty liver disease: a comprehensive review of a growing epidemic. *World journal of gastroenterology: WJG*, 20(34), p.12082.
  17. Corvino, A., Catalano, O., Corvino, F., Sandomenico, F. and Petrillo, A., 2017. Diagnostic performance and confidence of contrast-enhanced ultrasound in the differential diagnosis of cystic and cysticlike liver lesions. *AJR Am J Roentgenol*, 209(3), pp.W119-W127.
  18. Wrixon, A.D., 2008. New recommendations from the International Commission on Radiological Protection—a review. *Physics in Medicine & Biology*, 53(8), p.R41.
  19. Mountford, P.J. and Gibson, C.J., 2008. Revised fundamental recommendations on radiological protection. *Nuclear Medicine Communications*, 29(4), pp.307-310.
  20. Dauer, L.T., Mattsson, S., Vaňo, E. and Yonekura, Y., 2019. Radiation Protection for Patients. *Nuclear Medicine Textbook: Methodology and Clinical Applications*, pp.261-272.
  21. Artiko, M.V., Šobić-Šaranović, P.D., Perišić-Savić, S.M., Stojković, V.M., Radoman, B.I., Knežević, S.J., Petrović, S.N., Obradović, B.V. and Milović, V., 2008. <sup>99m</sup>Tc-red blood cells SPECT and planar scintigraphy in the diagnosis of hepatic hemangiomas. *Acta chirurgica Iugoslavica*, 55(4), pp.23-26.
  22. Burrioni, L., Borsari, G., Pichierri, P., Polito, E., Toscano, O., Grassetto, G., Al-Nahhas, A., Rubello, D. and Vattimo, A.G., 2012. Preoperative Diagnosis of Orbital Cavernous Hemangioma: A <sup>99m</sup>Tc-RBC SPECT Study. *Clinical Nuclear Medicine*, 37(11), pp.1041-1046.
  23. Basu, S., Torigian, D. and Alavi, A., 2008. The role of modern molecular imaging techniques in gastroenterology. *Gastroenterology*, 135(4), pp.1055-1061.