

## **$^{99m}\text{Tc}$ -DMSA renal scan and $^{99m}\text{Tc}$ -DTPA renography findings in patients with horseshoe kidneys: experience of a single institute**

**Zeenat Jabin, Shamim M.F. Begum, Rahima Perveen**

National Institute of Nuclear Medicine & Allied Sciences

**Address for correspondence:** Dr. Zeenat Jabin, Associate Professor & PMO, National Institute of Nuclear Medicine & Allied Sciences, BAEC, Block-D, BSMMU campus, Dhaka-1000, Email: zeenatjabin@yahoo.com

### **ABSTRACT**

**Purpose:** Horseshoe kidney is a congenital malformation that is found incidentally in many of the asymptomatic patients undergoing  $^{99m}\text{Tc}$ -DTPA renography and  $^{99m}\text{Tc}$ -dimercaptosuccinic acid (DMSA) renal scans in the nuclear nephrology division of National Institute of Nuclear Medicine & Allied Sciences (NINMAS). Scan findings of year 2012 and 2013 are demonstrated in this study. **Methods:** Few of the patients had known ultrasound reports of ectopic positioned or non-visualized kidney and mostly referred to our institute for  $^{99m}\text{Tc}$ -DTPA renogram. Each diuretic renogram consisted of dynamic renal scan images obtained with camera in both anterior and posterior positions and 15% window centered at 140 keV using 64 X 64 matrix. Acquisition started with bolus injection of  $^{99m}\text{Tc}$ -DTPA and dynamic images were acquired at 16-seconds/ frame for 75 frames. Intravenous injection of furosemide (1 mg / kg body weight) was given between 10-15 minutes of the study. They each underwent a  $^{99m}\text{Tc}$ -DMSA renal cortical scan to confirm the horseshoe kidney. **Results:** In a 2-year period, 14 patients (5 children and 9 adults) with horseshoe kidney were found with age ranging from 6 to 43 yrs (mean + SD, 23.93 ± 9.19) and a male to female ratio of 9:5. Nearly one third of patients (35.8%) were asymptomatic. Urinary tract infections or infection like symptoms were present in five (35.8%), whereas few showed vague symptoms like flank pain (7.1%), abdominal pain (7.1%), gastrointestinal symptoms such as nausea (7.1%), abdominal distension and fullness (7.1%). Three kidneys (21.42%) showed stasis of radioactive urine in the renal pelvic region prior to diuretic injection, suggesting functional obstruction. Only one kidney (7.17%) showed frank unilateral hydronephrosis and 2 (14.28%) showed obstructive nephropathy. There was no incidence of bilateral hydronephrosis. Gross parenchymal disease was seen in 2 (14.28%) and mild parenchymal insufficiency in 4 (28.57%). In 2 (14.28%) cases normal renal function with low GFR were observed. 35.71% patients show horseshoe kidneys with normal function and GFR with variation of sizes of two distinct kidneys. Of the 14 patients, asymmetrical renal cortical function between the two kidneys was found in 10 (71.4%). **Conclusion:**  $^{99m}\text{Tc}$ -DMSA renal scan and diuretic renogram with  $^{99m}\text{Tc}$ -DTPA are the simple techniques for the assessment of the patency of horseshoe shaped kidneys, because they can evaluate functional anatomy and urodynamics.

**Key words:** Renal Scintigraphy, Horseshoe Kidney

## **INTRODUCTION**

The horseshoe kidney is usually an incidental finding in most cases during renal scans in the Nuclear Nephrology division of NINMAS. The findings of diuretic DTPA renography and static DMSA scans are demonstrated to emphasize the functional status as well as combined position, fusion and rotation anomalies of the kidneys which are unusual congenital anomalies of the urinary tract.

## **MATERIALS AND METHODS**

Referred patients presented with suspected or sonographically proven horseshoe kidneys and were asked for DTPA renogram and DMSA renal scan in NINMAS. Few patients were incidentally diagnosed while scanning. Each diuretic renogram consisted of dynamic renal scan images obtained with camera in both anterior and posterior position and a 15% window centered at 140 keV using 64 X 64 matrix. Acquisition started with bolus injection of <sup>99m</sup>Tc-DTPA and dynamic images were acquired at 16-seconds / frame for 75 frames. Intravenous injection of furosemide (1 mg / kg body weight) was given between 10-15 minutes of the study. They each underwent a <sup>99m</sup>Tc-dimercaptosuccinic acid (DMSA) renal cortical scan 2-3 hours after intravenous injection of 4-7 mCi of <sup>99m</sup>Tc- DMSA to confirm the horseshoe kidney.

## **RESULTS**

In a 2-year period, 14 patients (5 children and 9 adults) with horseshoe kidney were found with age ranging from 6 to 43 yrs (mean  $\pm$  SD, 23.93  $\pm$  9.19) and a male to female ratio of 9:5. Nearly one third of patients (35.8%) were asymptomatic. Urinary tract infections or infection like symptoms were present in five (35.8 %), whereas few showed vague symptoms like flank pain (7.1 %), abdominal pain (7.1 %), gastrointestinal symptoms such as nausea (7.1 %), abdominal distension and fullness (7.1 %). The symptoms, findings and relevant results of DMSA renal scan and diuretic DTPA renogram are summarized in Table-1.

Three kidneys (21.42 %) showed stasis of radioactive urine in the renal pelvic region prior to diuretic injection, suggesting functional obstruction. Only one kidney (7.17 %) showed frank unilateral hydronephrosis and 2(14.28%) showed obstructive nephropathy. There was no incidence of bilateral hydronephrosis. Gross parenchymal disease was seen in 2 (14.28%) and mild parenchymal insufficiency in 4 (28.57%). In 2 (14.28%) cases normal renal function with low GFR were observed. 35.71% patients show horseshoe kidneys with normal function and GFR with variation of sizes of two

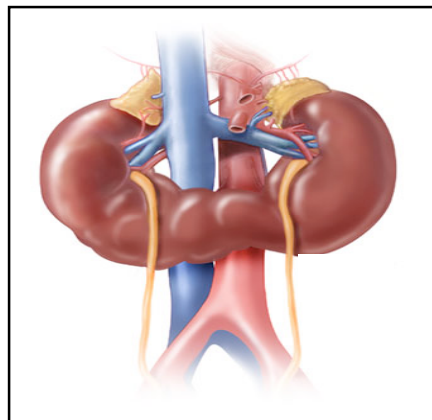
distinct kidneys. Of the 14 patients, asymmetrical renal cortical function between the two kidneys was found in 10 (71.4%).

**Table-1. Summary of DMSA renal scan and DTPA diuretic renogram findings of the 14 cases of horseshoe kidney**

Parameter	Number & Details
Age in years (mean ± SD)	6 -43 (23.93 ± 9.19)
Gender	9 male, 5 female
Symptoms	Asymptomatic (35.8%) UTI & related symptoms (35.8%) Flank pain (7.1%) Abdominal pain (7.1%) Distension and fullness (7.1%)
Asymmetrical cortical function	10 (71.4%)
Functional obstruction prior to diuretic injection	3 (21.42%)
Unilateral Hydronephrosis	1(7.17%)
Parenchymal disease	Marked in 2 (14.28%) Mild in 4 (28.57%)

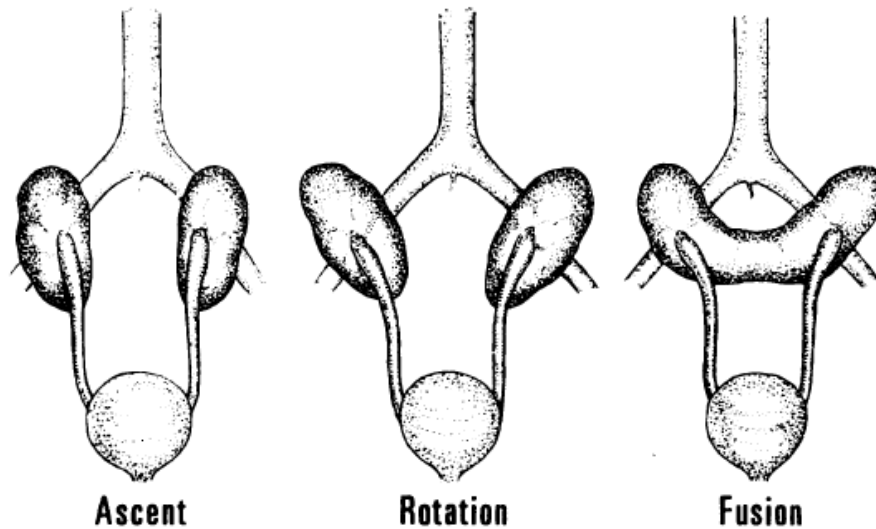
## DISCUSSION

The horseshoe kidney is the most common type of renal fusion anomaly, which can be found with an incidence of 1 in 304 in the general population, with an increased incidence in men (1). It consists of two distinct functioning kidneys on each side of the midline, connected usually at the lower poles by an isthmus of functioning renal parenchyma or fibrous tissue that crosses the midline of the body (Fig 1).



**Figure 1: The typical horseshoe kidney**

This anomaly results from an embryological fault, which develops between the 4th and 8th week of intrauterine life. The renal blastemata become fused before rotation and migration, which prevents independent rotation, and the vessels develop an abnormal relation to the renal pelvis and ureters (2) (Fig 2).



**Figure 2: The development of horseshoe kidney (Horseshoe Kidneys by F R Kilpatrick MS FRCS, Guy's and St Peter's Hospitals, London) <http://europepmc.org/articles/PMC1901808/pdf/procrsmed00169-0011.pdf>**

Nearly one third of patients with a horseshoe kidney remain asymptomatic, and the horseshoe kidney is an incidental finding during radiological examination. We also experienced the same in our institute. Only a few of our patients had known ultrasound reports of horseshoe, ectopic positioned or non-visualized kidney. All the patients were studied in both anterior and posterior positions to avoid underestimation of the function of an anteriorly placed renal moiety. Hydronephrosis is a common complication of horseshoe kidney (3). The anomalous position of the kidneys, pelvis, and ureter predisposes to poor drainage and may result in extensive hydronephrosis (4). The ureters are also short in fused pelvic kidneys and have a tangential course, which increases the risk of ureteric obstruction, stone formation, and infection (5).

Kao PF et al observed that the isthmus in all of the horseshoe kidneys was connected at the lower pole and the functioning isthmus portion was better seen in the anterior view images (6), which correlates with our observation too. Abrar AW et al found that clinical diagnosis changed after DTPA and DMSA scans (7) that matches with the patients we studied. Radionuclide scan is an effective, easy to perform,

reproducible and objective technique to investigate various functional renal parameters in obstructive uropathy before and after surgical intervention.

<sup>99m</sup>Tc-DMSA cortical scintigraphy can delineate the connecting bridge of the renal parenchyma as well as malrotation. Diuretic renography with <sup>99m</sup>Tc-DTPA has proved to be a reliable, non-invasive test for the diagnosis of upper urinary tract obstruction.

## CONCLUSION

<sup>99m</sup>Tc-DMSA renal scan and diuretic renogram with <sup>99m</sup>Tc-DTPA are the simple techniques for the assessment of the functional evaluation of horseshoe shaped kidney, because they can evaluate anatomy and urodynamics. A follow-up cohort study on these patients would be valuable for monitoring the development of complications and prognosis.

## REFERENCES

1. Basar H, Basar R, Basar M, Erbil M: The comparison of the incidence of horseshoe kidney in autopsy cases versus urologic patient population. *Okajimas Folia Anat Jpn* 1999, 76:137-139.
2. Cook WA, Stephens FD. Fused kidneys: morphologic study and theory of embryogenesis. *Birth Defects Orig Artic Ser* 1977; 13: 327–340.
3. Evans WP, Resnick MI: Horseshoe kidney and urolithiasis. *J Urol* 1981, 125:620-621.
4. Chavis CV, Press HC Jr, Gumbs RV. Fused pelvic kidneys: case report. *J Natl Med Assoc* 1992; 84: 980–982.
5. Masih S, Bakhda RK, Collins JD. Pelvic fused kidneys: magnetic resonance imaging and intravenous pyelogram correlation. *J Natl Med Assoc* 1988; 80: 925–927.
6. Kao PF, Sheih CP, Tsui KH, Tsai MF, Tzen KY. The <sup>99m</sup>Tc-DMSA renal scan and <sup>99m</sup>Tc-DTPA diuretic renogram in children and adolescents with incidental diagnosis of horseshoe kidney. *Nucl Med Commun*. 2003 May; 24(5): 525-30.
7. Abrar A. W. et al – Functional recovery in ureteropetric junction obstruction other surgery. *Indian Journal of Surgery*, Vol. 65, No. 3, May-June 2003, pp 260-262.