

Papillary Thyroid Carcinoma Presented with Huge Bone Metastases – Right Ileum and Frontal Bones

Fatima Begum, Sadia Sultana, Nabeel Fahmi Ali, Mohshi Um Mokaddema, Nurun Nahar

National Institute of Nuclear Medicine and Allied Sciences.

Correspondence: Dr Fatima Begum, Associate Professor, National Institute of Nuclear Medicine and Allied Sciences, Dhaka, Bangladesh. Email: fkbegum@yahoo.com

ABSTRACT

Papillary thyroid carcinoma (PTC) without metastases is most curable cancer. However, it rarely metastasizes to bone and in those cases prognosis is poor. A 55 years old female has presented with history of painless swelling on frontal region of skull for one year and limping gait to National Institute of Nuclear Medicine and Allied Sciences (NINMAS) in September 2013. She also had total thyroidectomy for multinodular goiter in early 2013. She had history of excision of swelling on frontal region in July of same year. Histopathological report of excised mass confirmed metastatic PTC. The patient again developed visible swelling on frontal region of skull suggesting recurrence. Her serum TSH was low 0.89 mIU/L without levothyroxine supplement may be due to thyroid hormones produced from metastatic masses. Serum thyroglobulin level was 464 ng/ml.

X-ray of pelvis and skull showed huge soft tissue masses arising from right ileum and a lytic lesion on posterior aspect of frontal region. Whole body bone scan with ^{99m} Technetium methylene diphosphonate (MDP) revealed a ‘doughnut’ lesion of frontal bone and a big lesion with ‘hot’ and ‘cold’ areas in right ileum and. On ultrasound scan, there was huge solid mass (about 10.0 cm× 7.0 cm) with some inhomogeneity and central cystic changes in medial aspect of right hip bone extending to pelvic cavity. Similar mass corresponded the visible swelling on skull. This mass was extended to intracranial region. Color Doppler study showed vascularity within and at margins of masses. To avoid risk of raised intracranial pressure following radioiodine therapy we sent the patient for external beam radiation therapy (EBRT) for reduction of the size of masses. Patient under went 5 cycles of EBRT (total 2000 c Gy in each lesion) but there were no reductions of sizes within one month follow up period. Small bony metastatic lesions from PTC in early stage are curable by surgical removal and repeated dose of radioiodine therapy. PTC with multiple advanced bony metastases shows poor prognosis.

Key words: PTC-Papillary thyroid carcinoma, Metastatic bony lesions.

INTRODUCTION

Papillary thyroid carcinoma (PTC) is most common variety of differentiated thyroid carcinoma (DTC). This disease is curable in low risk group with proper management having excellent prognosis. Bone metastases from DTC had been ranged from 2-13 % cases in different studies. After the age of 40 years, PTC showed 10% distant metastases. Most common sites of metastases from PTC are cervical lymphnodes and they rarely metastasize to distant regions like bone. PTC patients with history of metastases showed bony metastases in 1.4-7%. Although, PTC patients without metastases showed 10 years survival in >90% cases, poor prognosis was found in patients with bony metastases in previous studies. About 13-21% patients with bony metastases showed 10 years survival (1). Early diagnosis and staging of the tumor, ¹³¹I avidity, and presence of distant metastases at diagnosis and age of the patient affect the treatment outcome of these types of patients (2, 3). Here, a rare case of elderly female patient with PTC having huge bony metastases in right hip bone and frontal bone is reported.

CASE REPORT

PTC without metastases is most curable cancer among all DTC. However, it rarely metastasizes to bone and in those cases prognosis is poor. A 55 years old female has presented with history of painless swelling on frontal region of skull for one year and limping gait to National Institute of Nuclear Medicine and Allied Sciences (NINMAS) in September 2013. She had total thyroidectomy on April 2013 for multinodular goiter. She was not on levothyroxine supplementation. Thereafter, swelling on frontal region was excised as it increased further. Histopathological report of excised mass confirmed metastatic PTC. The patient again developed visible swelling on frontal region of skull suggesting recurrence (Figure-1). Her serum TSH was low 0.89 m IU/L without levothyroxine supplement may be due to thyroid hormones produced from metastatic masses. Serum thyroglobulin (Tg) level was 464 ng/ml. Her anti Tg antibody was within normal limit.

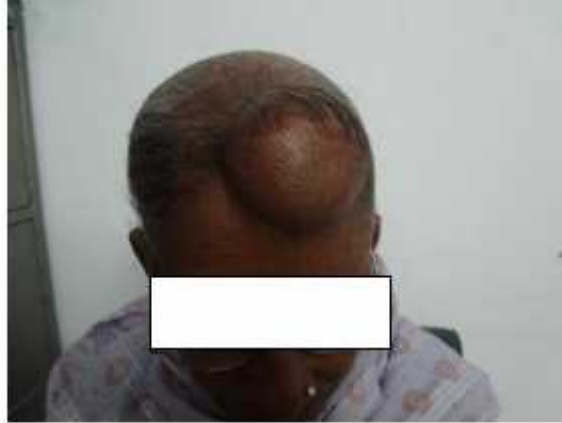

Figure 1: A 55 years old female presented with papillary thyroid carcinoma with metastatic mass in frontal region.

X-ray of pelvis showed huge soft tissue mass arising from right iliac bone (Figure-2, a). Similarly X-ray of skull depicted lytic lesion on posterior aspect of frontal region (Figure-2, b).

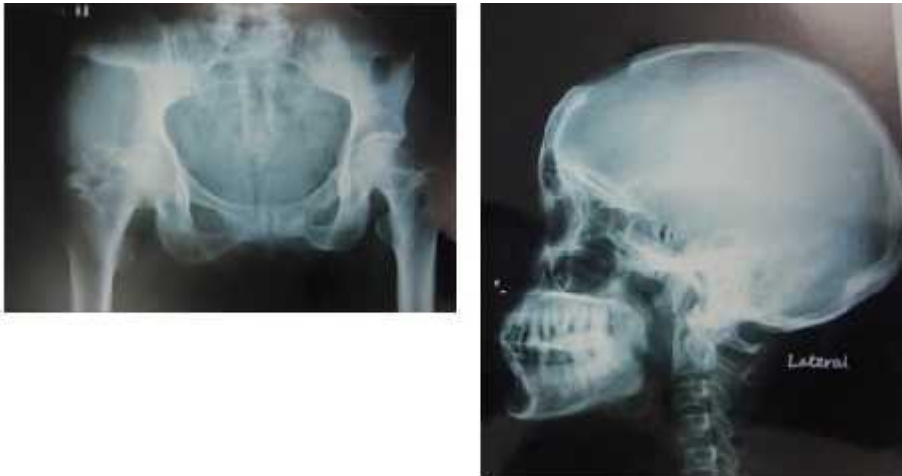

Figure 2. a) X-ray of pelvis showed huge soft tissue mass in right ilium. b) Lateral view X-ray of skull showed lytic lesion on frontal skull bone

Whole body bones scan with ^{99m}Tc methylene diphosphonate (MDP) a big lesion with 'hot' and 'cold' areas in right pelvic bone and 'doughnut' lesion of frontal bone (Figure-3). On ultrasound scan, there was huge solid mass (about 10.0 cm \times 7.0 cm) with some inhomogeneity in medial aspect of right iliac bone extending to pelvic cavity (Figure-4, a). Similar mass (3.0 cm \times 2.0 cm) corresponded the visible swelling on skull.

This mass was extended to intracranial region, this portion measured about 2.5 cm× 2.0 cm (Figure-4, b).

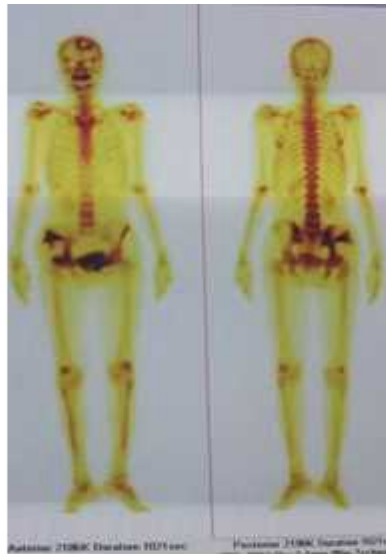


Figure 3: Whole body bone scan by ^{99m}Tc MDP showed 'hot' and 'cold' areas in right hip bone and 'doughnut' sign lesion on frontal bone suggesting metastatic lesions

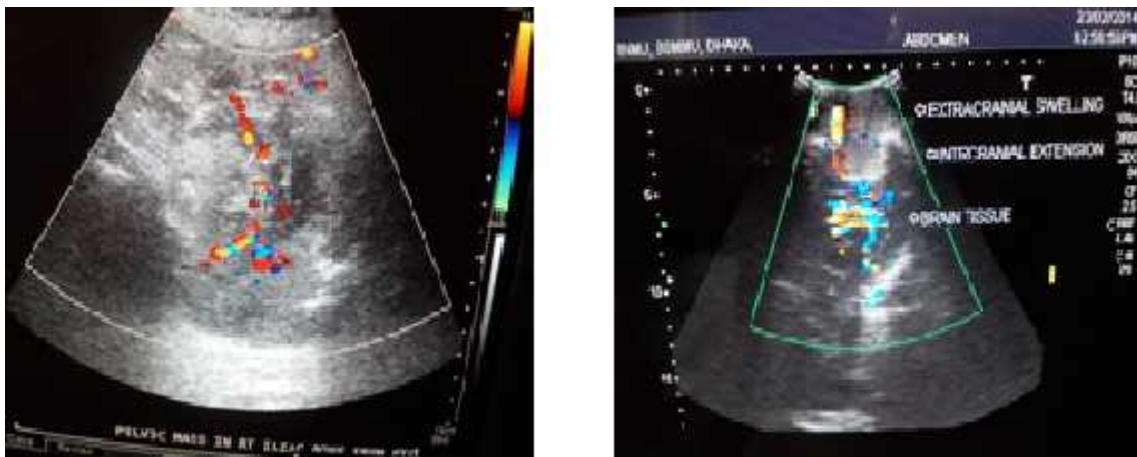


Figure 4: a) Ultrasound imaging by 3.5 MHz probe of right side of pelvis of patient with PTC showed huge solid, irregular mass with vascularity inside on color Doppler application. b) Ultrasound image of skull swelling is showing extra cranial soft tissue mass with intracranial extension by destruction of skull bone even made window to visualize brain tissue.

Color Doppler study showed vascularity within and at margins of masses. To avoid risk of raised intracranial pressure following radioactive iodine (RAI) therapy we sent the patient for external beam radiation therapy (EBRT) for reduction of the size of masses. Patient received 5 cycles of EBRT (total 2000 cGy in each lesion) but there was no reduction of sizes within one month follow up period. Surgeons decided to excise the masses. Thereafter, decision about radioiodine would be taken. She had also consulted palliation department, Bangabandhu Sheikh Mujib Medical University and being followed up by Thyroid Division, NINMAS. Patients with PTC with multiple advanced bony metastases have poor prognosis and suffers from degradation of quality of life.

DISCUSSION

Papillary thyroid carcinoma is the most common type of differentiated thyroid carcinoma. PTC shows excellent prognosis by proper management with thyroidectomy and radioiodine therapy. Metastases from PTC usually occur in regional lymph nodes (2,4-6). Bony metastases from DTC are rare and show poor prognosis. Cancer registry of NINMAS, showed total 466 new patients with DTC received radioiodine therapy during the year 2013, among them PTC was 94.85% and follicular thyroid carcinoma (FTC) was 5.15%. Among them 30.9% presented with metastases. Cervical lymphnodes metastases were found in most of the metastatic cases 126 (87.4%), lungs and bony metastases were evaluated in same number 5 (3.5%) and local infiltration was seen in 8 (5.6%). Bony metastases were mainly occurred in patients with FTC in 4 (80%) and one case was follicular variant of papillary carcinoma. Only this case was PTC with bony metastases and was not included in above-mentioned data as patient was waiting for radioiodine therapy. In presented case, the patient had history of painless small swelling on frontal region for one year. She had total thyroidectomy for multinodular goiter in early 2013. Unfortunately, histopathology of thyroid tissue could not reveal any malignancy. Following total thyroidectomy she was not on levothyroxine supplementation. When the masses become bigger then she felt mild pain and biting sensation over the swelling of the mass of skull. Thereafter, excision of skull mass was done. Histopathological report of excised mass confirmed metastatic PTC. At this stage she noticed a painless swelling in right pelvis. Investigations at NINMAS, revealed low serum TSH level (0.89 m IU/L) without levothyroxine supplement may be due to thyroid hormones produced from

metastatic masses. Serum thyroglobulin (Tg) level was 464 ng/ml. Her anti Tg antibody was within normal limit.

Similar case was reported in a previous study having painless metastases on right iliac bone, had history of surgical removal and subsequent radioiodine therapy. Patient was in disease free condition (5). Our reported patient developed recurrence on skull at same site after first surgical removal shortly which is gradually increasing in size. It also extended internally and invaded the intracranial tissue destroying skull bone. X-ray of skull showed a big lytic lesion on posterior aspect of frontal bone. Then she gradually developed limping gait and mild pain on right pelvic bone. On X-rays, huge lytic lesion on right pelvic bone was found. Whole body bone scan by 99m Technetium MDP showed a 'doughnut' lesion of frontal bone and a big lesion with 'hot' and 'cold' areas in right pelvic bone suggesting metastatic lesions. Two metastatic bony lesions from PTC were found on sternum in female patients in another study. These patients had sternectomy followed by radioiodine therapy and were in remission of disease (7). Another study reported an older female patient with PTC with aggressive metastases in left parieto-occipital lobe, bilateral lungs, left caput humeri, left triceps brachii muscle, right femur and left thumb (4). In our reported case, ultrasound imaging evaluated huge soft tissue masses in the mentioned areas. Vascularity was noted within and at margins of masses on color Doppler application. Similarly, ultrasound imaging was found as a good tool to image and mapping of metastatic bony mass as evaluated in other study (4). Ultrasonography is a good supportive tool for assessment of bony metastases from thyroid cancer in initial stage and in subsequent follow up. It gives information about the size and extension of the mass. There are different options of treatment PTC with bony metastases. If the lesions are smaller and ^{131}I avid repeated radioiodine doses are recommended at 4-6 months interval until metastatic lesions disappear. Surgical removal of masses and followed by radioactive iodine (RAI) therapy is another option of treatment (1,2,8). External beam radiation therapy (EBRT) can be given to reduce the size before surgery and RAI therapy. The patient of this report received EBRT for reduction of sizes of masses. Within one month of EBRT, no reduction of sizes was noted. Rather increasing of sizes was noted. The size of pelvic mass measured 12 cm \times 10 cm and that of skull mass became 3.0 cm \times 2.5 cm on ultrasonography at one month follow up after EBRT.

Previous data of different studies showed that osseous metastases and non-radioiodine avid tumor had poor prognosis with decreased cancer specific survival (6). Surgical removal of distant metastatic masses and followed by radioiodine therapy are recommended by British Thyroid Association guidelines, 2014 (8). These measures improve the quality of life of patient and are associated good prognosis. In our case, patient only received EBRT and pain palliation presently. Expert surgeons of Bangabandhu Sheikh Mujib Medical University have agreed to excise the masses, which would be followed by RAI therapy.

CONCLUSION

PTC with metastatic multiple bony lesions is a very rare condition. Bony metastases of PTC may present in advanced stages may be due to initial painless condition. Prognosis is better in early detected cases when lesions are confined to bone marrow or bone. Morbidity is higher and survival is poor in advanced cases. Ultrasonography is a good supportive tool for assessment of bony metastases from thyroid cancer in initial stage and in subsequent follow up. It gives information about the size and extension of the mass. This case of PTC with huge bony lesions could not be treated by radioiodine therapy yet due to intracranial extension of skull mass. Surgical excision of masses followed by radioiodine therapy has been planned for this patient.

REFERENCES

- 1 Muresan MM, Olivier P, Leciere J, Sirveaux F, Brunaud L, Klein M et al. Bone metastases from differentiated thyroid carcinoma. *Endocrine-Related Cancer* 2008;16: 39-49
- 2 Cooper DS, Deherty GM, Haugen BR, Kloos RT, Lee SL, Mandel SJ, et al. Revised American Thyroid Association Management Guidelines for Patients with Thyroid Nodules and Differentiated Thyroid Cancer. *Thyroid*. 2009;19(11):Available from- DOI:10.1089=thy.2009.0110.
- 3 Hindi E, Zanotti-Fregonara P, Keller I, Duron F, Devaux JY, and Calzada-Nocaudie MC. Bone metastases of differentiated thyroid cancer: impact of early ¹³¹I-based detection on outcome. *Endocrine-Related Cancer* 2007;14:799–807.
- 4 Zhou XC, Hu KQ, Zhou H, Ye YH, Li XY, Jiang Y. Unusual metastases from

- papillary thyroid carcinoma. *Head Neck Oncol* 2012;4(4):75-7.
- 5 Siddiq S, Ahmad I, Colloby P. Papillary thyroid carcinoma presenting as an Asymptomatic pelvic bone metastases. *JSCR*. 2010 3:21 / 4. Downloaded from <http://jscr.oxfordjournals.org/> accessed on February 21, 2014
 - 6 Lang BHH, Wong KP, Cheung CY, Wan KY and Lo CY. Evaluating the Prognostic Factors Associated with Cancer-specific Survival of Differentiated Thyroid Carcinoma Presenting with Distant Metastasis. *Ann Surg Oncol* 2013; 20:1329–35.
 - 7 Luna-Ortiza K, Salcedo-Hernández RA, Lino-Silva LS, Gómez-Pedraza A. Two cases of sternectomy for bone metastasis due to aggressive variants of thyroid papillary carcinoma. *Medical Science Monitor* 2004. (10):108–111.
 - 8 Perros P, Boelaert K, Colley S, Evans C, Evans RM, Gerrard G. Guidelines for the management of thyroid carcinoma. Third Edition, draft, 14 th Feb 2014, British Thyroid Association. Accessed on 23 Feb 2014