

Pattern of Renogram Findings in Patients Attending INMAS, Rajshahi

¹M.M. Arif Hosen, ¹Nasrin Begum, ¹Parvez Ahmed, ¹Mosharruf Hossain, ¹Kabiruzzaman Shah,
¹Shafaly Khatun, ¹Shariful Islam Chowdhury, ²F.F. Shimu

¹Institute of Nuclear Medicine and Allied Sciences (INMAS), Rajshahi. ²MS Resident, Rajshahi Medical College Hospital, Rajshahi

Correspondence Address: Dr. M.M. Arif Hosen, SMO/Assistant Professor, Institute of Nuclear Medicine and Allied Sciences, Rajshahi. E-mail- dr.arif43@gmail.com

ABSTRACT

Objective: Renogram using ^{99m}Tc DTPA (Technetium diethylene-triamine-pentaacetic acid) with diuretic challenge provides important functional data to assist in the diagnosis and management of suspected renal diseases. Renogram is a routinely performed study at the Institute of Nuclear Medicine and Allied Sciences (INMAS), Rajshahi. This is a referral institute of northern part of the country. The objective of this study was to see the pattern of renogram findings in INMAS, Rajshahi.

Patients and Methods: A total 98 patients underwent renogram using ^{99m}Tc-DTPA with diuretic challenge from July 2015 to June 2016 were included in this study and a retrospective observation study was done. A total 98 (male to female ratio 1: 0.75) with a mean age 38.6 ± 18.5 years (age range two months to 80 years) patients data were analyzed. Some additional imaging and biochemical tests were available at the time of renography eg. Ultrasonography of renal system and serum creatinine level in all cases, X-ray of KUB (kidney-ureter-bladder) region in 44 cases, IVU (intravenous urogram) in 38 cases and urinary routine and microscopic examination in 32 cases only were done.

Results: Renogram findings showed obstructive renal disease in single or both kidneys in 57.14% cases, non-obstructive abnormalities in single or both kidneys in 28.57% cases and normal study in 14.29% cases.

Conclusion: In this study a variety of renographic diagnosis was observed, most common was obstructive renal disease in 57.14% cases and non-obstructive abnormalities in 28.57% cases.

Key words: Renogram, ^{99m}Tc DTPA (diethylene- triamine -pentaacetic acid), diuretic challenge, obstructive renal disease.

INTRODUCTION

Renogram using ^{99m}Tc DTPA with diuretic challenge provides important functional data to assist

in the diagnosis and management of suspected renal diseases (1). Application of nuclear imaging technique in the diagnosis of renal pathology plays a major part at Institute of Nuclear Medicine and Allied Sciences (INMAS). This institute is located in a small town Rajshahi, and a nuclear medicine referral institute of northern part of Bangladesh. Different radiopharmaceuticals are used for renal scanning to evaluate renal function or renal morphology (2). Diuretic renography is used to differentiate the dilated non-obstructed collecting system from urodynamically significant obstruction (3). ^{99m}Tc-DTPA renogram is an easy, safe, non-invasive, and cheaper imaging technique. The burden of radiation hazard is much lower than other radiological imaging modalities (4). In the study we have analyzed the pattern of findings of diuretic renogram and different types of renal diseases at INMAS Rajshahi, like obstructive and non-obstructive renal disease, renal parenchymal disease with their functions as well.

PATIENTS AND METHODS

It is a retrospective study, carried out from July 2015 to June 2016 at INMAS, Rajshahi. A total 98 patients were referred for renogram with diuretic challenge at INMAS was included in this study. In this institute SPECT digital dual head gamma camera (e-cam series, Siemens from Germany) with a low-energy high resolution parallel hole collimator was used. Patients were well hydrated and then void before starting study. After an intravenous bolus injection of

3-5 m Ci 99mTc DTPA for adult patient and 1-2 mCi 99mTc DTPA for children, perfusion images were obtained in every 01 second for the first minute, every 10 seconds between one and four minutes followed by acquisition of dynamic images every 20 seconds for 30 minutes with the patient in a supine position and with detector placed behind. At 10th minute injection furosemide 20 mg for adult patient and 10 mg for children was administered intravenously. We also calculated the full syringe count prior to 99mTc DTPA injection and empty syringe count at the end of the study. Images were collected in to a 64 x 64 matrix in word mode. The energy window around the 140 Kev photon peak of Tc99m was 20%.

Data analysis:

Data analysis was done by using X-ring v7.02 software.

RESULTS

Out of 98 patients (mean age 38.6 ± 18.5 years, age range 2 months to 80 years) a wide variety of renographic findings are observed. Forty-two patients (42.86%) had pathology in right kidney, twenty-four patients (24.49%) had in left kidney, eighteen patients (18.37%) had bilateral disease and fourteen patients (14.29%) had normal findings in renogram (Figure-1).

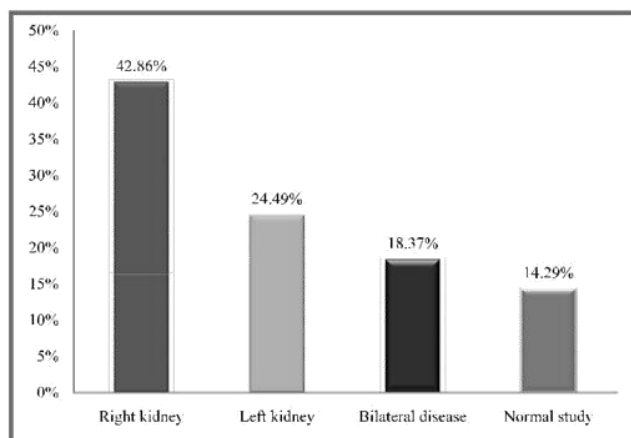


Figure 1: The distribution of renal diseases in renogram (in percentage) in study population (n=98).

Among the 98 patients twenty-six patients (26.53%) had right renal obstruction, six (6.12%) had right renal

obstruction with parenchymal disease, five (5.10%) had right renal parenchymal disease, five (5.10%) had non-functioning right kidney, ten (10.20%) had non-functioning left kidney, nine (9.19%) had left renal obstruction, five (5.10%) had left renal obstruction with parenchymal disease, ten (10.20%) had bilateral renal obstruction with parenchymal disease, eight (8.17%) had bilateral renal parenchymal disease (Table-1). Overall renographic findings showed obstructive renal disease in single or both kidneys in fifty-six (57.14%) patients, non-obstructive abnormalities in single or both kidneys in twenty-eight (28.57%) patients and normal study in fourteen (14.29%) patients (Figure2).

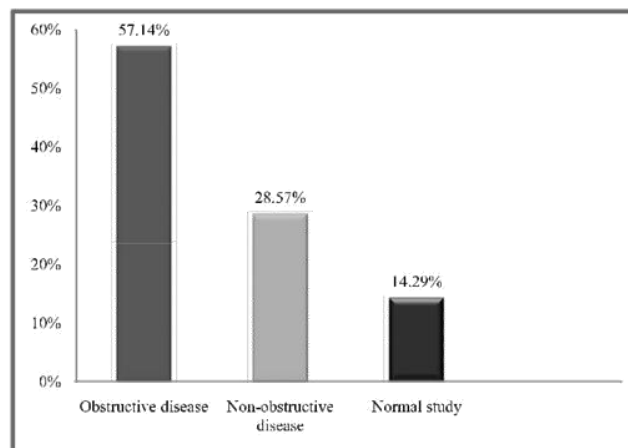


Figure 2: The distribution of obstructed and non-obstructed renal disease (in percentage) in study population (n=98).

Table1: The pattern of renogram findings in number and percentage in study population (n=98).

Pattern of renogram findings		No. of patients	In percentage
Right kidney	Right renal obstruction	26	26.53%
	Right renal obstruction with parenchymal disease	6	6.12%
	Right renal parenchymal disease	5	5.10%
	Non-functioning right kidney	5	5.10%
Left kidney	Left renal obstruction	9	9.19%
	Left renal obstruction with parenchymal disease	5	5.10%
	Non-functioning left kidney	10	10.20%
Bilateral disease	Bilateral renal obstruction with parenchymal disease	10	10.20%
	Bilateral renal parenchymal disease	8	8.17%
Normal study		14	14.29%

DISCUSSION

Renogram is the graphical record of the passage of radioactivity through the renal system after injection of a radioactive tracer (5). In our institute we use ^{99m}Tc DTPA as a radioactive tracer for renogram along with diuretics. Renogram objectively measures individual renal function and it is considered as the imaging modality of choice for assessment of the individual function (6). Conventional radiographic contrast technique (CT) give valuable information about the anatomical structure of the kidney and collecting systems, they provide only qualitative information on differential renal function. On the other hand diuretic renogram can differentiate obstructed from non-obstructed renal disease as well as assess functional and urodynamic result (7). So the gold standard to determine differential renal function is the nuclear imaging that is diuretic renogram (8). ^{99m}Tc DTPA is the least expensive radio-pharmaceuticals and is excreted by the kidneys through glomerular filtration (9). Obstruction to urinary outflow may lead to obstructive uropathy (dilatation of the calyces, pelvis, or ureter) and parenchymal damage (10). Obstruction could be functional or anatomical (11).

No data are available on incidence and prevalence of urinary obstruction in unselected populations. However the prevalence of obstructive uropathy in adults ranges from five in 10,000 to five in 1,000, depending on the type of obstructive uropathy (12-15). Most epidemiologic studies of obstruction are in selected populations or autopsy studies. In large surveys of elderly men for symptoms of urinary obstruction, a prevalence of 20-35% has been estimated (16). In this study population, obstructive renal disease in single or both kidneys were evident in fifty-six (57.14%) patients, which were more than the reported studies, might be due to selected group of patients.

Among 98 patients 56 were male and 42 were female and their age ranging from two months to 80 years

(mean age 38.6 ± 18.5 years). Clinically 55 patients had flank pain, either right or left side or both and 20 patients had features of UTI. Ten patients had DM, nine patients had HTN and six patients had both DM and HTN. The range of serum creatinine was 0.5-12.9 mg/dl (mean 1.75 ± 12.1). Thirty-two patients had urinary routine and microscopic examination and among them 22 patients had significant pus cell and only one patient had pus cell with albumin with RBC. 13 patients had IVU and among them 13 patients had hydronephrosis without PUJ obstruction in right kidney; ten had hydronephrosis due to PUJ obstruction in right kidney and five had hydronephrosis due to PUJ obstruction in left kidney; two patients had poorly functioning right kidney and two patients had poorly functioning left kidney and six patients had normal findings. Forty-four patients had X-ray of KUB region and among them three patients had bilateral renal calculi and two patients had left renal calculi.

In this institute we routinely performed renal ultrasonogram prior to renogram. In this study population a wide variety of ultrasonography findings were evident, thirty patients had moderate to gross hydronephrosis (twenty patients in right kidney and ten in left), fourteen patients had mild hydronephrotic change (ten patients in right kidney and four in left), nine patients had bilateral hydronephrosis, eight patients had bilateral renal parenchymal disease with obstruction, two had bilateral chronic renal parenchymal disease, ten had chronic renal parenchymal disease in either kidney (seven patients in right kidney and three patients in left), four had right renal parenchymal disease with hydronephrosis, three patients had bilateral renal calculi, two patients had left renal calculi, one had right renal calculi and others had normal sonological findings.

We interpret the whole study by seeing perfusion and dynamic images, computer generated renographic curves and $T_{1/2}$ values. In case of obstructive renal disease – perfusion and dynamic images shows

enlargement of the obstructed kidney, cortical tracer uptake is normal, dilatation of pelvis with delayed and prolonged cortico-calyceal transit. Renographic curve shows blunted cortical uptake phase and delayed excretory phase. T1/2 value shows > 20 minutes. In case of parenchymal renal disease the kidney size appears normal or smaller, cortical tracer uptake is low or minimum, pelvi-calyceal transit is often delayed. Persistence tracer activity is seen throughout the study. Renographic curve may shows blunted cortical uptake phase and delayed excretory phase. In case of poorly functioning / non-functioning kidney – size of the kidney is usually small with minimal cortical tracer activity, no activity in delayed images. Cortical uptake phase and excretory phases are absent in renographic curve.

CONCLUSION

Renogram with 99m Tc DTPA with diuretic challenge is a widely used nuclear imaging procedure to evaluate renal pathology and its function at INMAS, Rajshahi. In this study a variety of renographic diagnosis was observed, most common was obstructive renal disease in 57.14% cases and non-obstructive abnormalities in 28.57% cases. As the study was carried out in a single institution, a large scale multicentric study can be done for comparison with other parts of the country.

REFERENCES

- Andrew T. Taylor. Radionuclides in nephrourology, part1: radiopharmaceuticals, quality control, and quantitative indices. *J Nucl Med* 2014; 55(4):608-15.
- Schlegel JU, Halikiopoulos HL, prima R. Determination of filtration fraction using the gamma scintillation camera. *J Urol* 1979;122(3):447-50.
- Zubal IG, Caride VJ. The technetium-99m-DTPA renal uptake-plasma volume product: a quantitative estimation of glomerular filtration rate. *J Nucl Med* 1992; 33(9):1712-16.
- Nawfel RDI, Judy PF, Schleipman AR, Silverman SG. Patient radiation dose at CT urography and conventional urography. *Radiology* 2004 Jul; 232(1):126-32.
- <http://www.thefreedictionary.com/renogram>
- Yalcin H, Ozen A, Gunay EC, Ozaslan IA, Ozer C. Can Tc-99m-DTPA be used in adult patient in evaluation of relative renal function measurement as the reference Tc-99m-DMSA method? *Mol Imaging Radionucl Ther* 2011; 20(1):14-18.
- Soga SI, Britz-Cunningham S, Kumamaru KK, Malek SK, Tullius SG, Rybicki FJ. Comprehensive comparative study of computed tomography based estimates of split renal function for potential renal donors: modified ellipsoid method and other CT based methods. *J compute Assist Tomogr* 2012; 36(3):323-29.
- Mulligan JSI, Blue PW, Hasbergen JA. Methods for measuring GFR with Tc-99m-DTPA: an analysis of several common methods. *J Nucl Med*. 1990 Jul; 31(7):1211-19.
- Goates, JJ, KA Morton, WW Whooten, HE Green berg, FL Datz, JE Handy. Comparison of methods for calculating glomerular filtration rate: Tc99m-DTPA scintigraphic analysis, protein free and whole plasma clearance of technetium 99m-DTPA and iodine125-iodothalamate clearance. *J Nucl Med*. 1990; 31:424-29.
- Taylor A, Lallone R. Differential renal function in unilateral renal injury: possible effects of radiopharmaceutical choice. *J Nucl Med* 1985; 26:77-80.
- <http://emedicine.medscape.com/article/436259-overview#a4>
- A.D.A.M. medical encyclopedia [Internet] Acute bilateral obstructive uropathy. Atlanta (GA): A.D.A.M., Inc.; Mar 22, 2010. [cited 2011;14] c1997-2011. Available from: <http://www.nlm.nih.gov/medlineplus/ency/article/000485.htm>
- A.D.A.M. medical encyclopedia [Internet] Chronic unilateral obstructive uropathy. Atlanta (GA): A.D.A.M., Inc.;22, 2010. [cited 2011 Apr 14] c1997-2011. Available from: <http://www.nlm.nih.gov/medlineplus/ency/article/000498.htm>
- A.D.A.M. medical encyclopedia [Internet] Acute unilateral obstructive uropathy. Atlanta (GA): A.D.A.M., Inc.; Mar 17, 2011. [cited 2011 Apr 14] c1997-2011. Available from: <http://www.nlm.nih.gov/medlineplus/ency/article/000509.htm>
- A.D.A.M. medical encyclopedia [Internet] Chronic bilateral obstructive uropathy. Atlanta (GA): A.D.A.M., Inc.; Mar 22, 2010. [cited 2011 Apr 14] c1997-2011. Available from: <http://www.nlm.nih.gov/medlineplus/ency/article/000467.htm>
- <http://emedicine.medscape.com/article/778456-overview#a8>