

Assessment of Agreement Between Peak Systolic Velocity of Inferior Thyroid Artery and Thyroid Scan in Differentiating Diffuse Toxic Goiter and Subacute Thyroiditis

Khaleda Mushtary, Nasreen Sultana and Sharmin Quddus

National Institute of Nuclear Medicine and Allied science

Correspondence Address: Dr.KhaledaMushtary, M Phil student,NINMAS,BAEC,Dhaka,
e-mail:khaledamushtary@gmail.com

ABSTRACT

Objective: To analyze agreement between Peak Systolic Velocity (PSV) of inferior thyroid artery (ITA) and Tc99m Thyroid Scan for evaluation of thyrotoxicosis(diffuse toxic goiter and sub-acute thyroiditis).

Patients and Methods: This prospective cross sectional study was conducted in National Institute of Nuclear Medicine and Allied Sciences (NINMAS) from July 2016 to June 2017. Total sixty four patients with thyrotoxicosis were included in the study. History, clinical examination and thyroid function tests were done for all patients. The thyroid gland of all patients were evaluated by gray scale ultrasonography for size, shape and echotexture. Color-flow Doppler ultrasonography (CFDS) of the thyroid tissue was performed and spectral flow analysis of both inferior thyroid arteries were assessed. Tc99m Thyroid scan was done for all patients. The patients were divided into two groups. Group A- Diffuse toxic goiter(DTG) and Group B-Subacute thyroiditis(SAT). The diagnosis of diffuse toxic goiter and subacute thyroiditis was supported by the clinical picture, RAIU uptake and Thyroid Scan.

Results: All patients had suppressed thyrotropin. Thyroid blood flow, measured by PSV of ITA (CFDS) was higher than normal in DTG patients, while low PSV of ITA than normal was found in SAT. According to Thyroid Scan on Radiotracer concentration (RTC) was diffusely increased with low background (BKG) and almost absent RTC with high BKG was noted in DTG and SAT respectively. In our study Tc99m Thyroid Scan shows agreement with Peak Systolic Velocity of ITA. Here Kappa value was 0.818 and 0.871 in DTG and SAT respectively with P value <0.05 which was statistically significant with almost perfect agreement.

Conclusion: An Almost perfect agreement between the two modality (PSV of ITA and Tc99m Thyroid Scan) establishes that they are useful alternative in the differential diagnosis of thyrotoxicosis (Diffuse toxic goiter and Subacute thyroiditis).

Bangladesh J. Nucl. Med. Vol. 21 No. 2 July 2018

Doi : <https://doi.org/10.3329/bjnm.v21i2.40359>

INTRODUCTION

Thyrotoxicosis refers to clinical syndrome that results from metabolic effect of excess thyroid hormone at the tissue level, regardless of the etiology. Thyrotoxicosis may be caused either by hyperthyroidism or by inflammation of the thyroid gland with release of stored thyroid hormone but not accelerated synthesis (1). Thyrotoxicosis has multiple etiologies, manifestations, and potential therapies. Appropriate treatment requires an accurate diagnosis. Hyperthyroidism is high synthesis & secretion of thyroid hormone by thyroid gland. Diffuse toxic goiter (DTG) is an autoimmune, diffuse, chronic disease of thyroid gland with evidence of genetic predisposition and unknown etiology (2). In clinical practice first steps of DTG patient's management is to distinguish it from other types of destructive thyrotoxicosis. Subacute thyroiditis (SAT) is an inflammatory painful viral infectious disease of thyroid gland, frequently accompanied by fever. SAT is a self-limiting thyroid condition associated with a triphasic clinical course of hyperthyroidism, hypothyroidism, and/or return to normal thyroid function (3). Differentiation between diffuse toxic goiter and subacute thyroiditis is very important as management of each case is different. Nuclear imagings, RAIU (Radio iodine uptake test) of thyroid gland and Tc99m thyroid scan are helpful in differentiation of DTG and SAT (4).

Now a days, with the wider popularity of physical health screening many cases of atypical diffuse toxic goiter have been identified. Typical symptoms are often absent or not prominent, at the same time the incidence of painless thyroiditis is rising and commonly found in clinical practice (5). Tc99m is a metastable radio-isotope of technetium. Thyroid Scan by Tc99m is used for differentiation of diffuse toxic goiter (DTG) and subacute thyroiditis (SAT) by measuring the functional status of the thyroid gland (Increased/decreased RTC). Tc99m thyroid scan is not widely available and done by using ionizing radiation. Moreover it cannot be done in pregnancy and lactation. It can be influenced by iodine containing diet and medications. On the other hand peak systolic velocity of inferior thyroid artery is non-invasive, easily available, rapidly obtained in Nuclear Medicine and Radiology department and it can also be done in pregnancy and lactation.

Duplex study of thyroid gland provide valuable information in diagnosis of thyrotoxicosis. It is a technique combining the gray scale view of the conventional sonography with a color display of blood flow (6). Peak systolic velocity (PSV) obtained from the inferior thyroid artery is the parameter commonly employed for the quantitative Doppler evaluation of thyroid gland (6,7). Other estimation of thyroid blood flow is vascularization index and high-resolution power Doppler USG. Assessment is at the same time qualitative (gland visual vascularization impression) and quantitative (inferior thyroid arteries peak systolic velocity). The limits of normal PSV was accepted as 23–25 cm/s for ITA as supported by many literature (8,9,10).

PATIENTS AND METHODS

The study was approved by Medical Research Ethics Committee (MREC) of the National Institute of Nuclear Medicine and Allied Sciences (NINMAS). Total sixty-four referred patients were

selected from thyroid division of NINMAS. Patients who came for the evaluation of suspected or known thyrotoxicosis by Tc99m thyroid scan along with RAIU, were included in this study. Pregnancy and lactating mother, previously treated with radioiodine therapy, thyroid tumor, history of thyroidectomy, nodular goiter, were excluded from the study. Details of the history were taken with special emphasis on palpitations, weight loss, ophthalmic complaints, and recent history of flue like episode (fever, malaise, neck pain) and family history of thyroid illness. Clinical examination (general & thyroid) were done, including assessments of radial pulse, blood pressure, ophthalmopathic problems, skin and nail changes related to hyperthyroidism and goiter. Patient's biochemical tests findings (Thyroid hormone profile, Anti-thyroid antibody) were recorded from their medical file. Gray Scale USG done to exclude nodule. By inclusion and exclusion criteria patients were selected for the study. All the patients were informed about the potential risk and benefit of the procedure and informed consent was taken from each patients before the Duplex study of thyroid gland. Peak Systolic Velocity (PSV) of both inferior thyroid artery were calculated by advanced USG machine of Samsung, C43X and Toshiba, Aplio-500 with 12 MHz multi-frequency linear transducer, Color pulse repetition frequency was 2-8 KHz and wall filter was 25-80 Hz. Patient position was supine with neck hyper-extended. Echogenicity of the thyroid parenchyma was graded as diffuse homogeneous or mild, moderate, or extremely heterogeneous in grey scale. Color Doppler parameters were standardized and, for all studies, the same presets were used for the acquisition. The inferior thyroid artery was examined in the oblique transversal plane, close to the transition between the Medical and the inferior third of the thyroid. The Doppler angle was corrected to values 45°-60°. The mean value found in the right and left lobes was used

as a representative parameter. The intra-parenchymal vascular patterns of the thyroid gland graded as high, normal or low. PSV of ITA less than normal reference range, that is <20cm/s considered as SAT, supported by many literature (6,7) and >40cm/s is considered significantly higher and is suggestive of diffuse toxic goiter (1,6).

Then RAIU by ¹³¹I was done in all patient by single head gamma camera with 1cc of ¹³¹I, administered orally. Uptake was calculated using the software application programmed in E-cam. Normal range of uptake for our laboratory (NINMAS) is in 2 hours:4-10% and in 24 hours:10-25%. Measurement allows the diagnosis of hyperthyroidism and distinguishes other causes of thyrotoxicosis from hyperthyroidism. ^{99m}Tc Thyroid Scan was performed in all patients using a single headed gamma camera with low energy all-purpose/pinhole collimator with 20% energy window centered at 140 Kev and patient in supine position. Ultrasound is done first followed by an IV injection of tracer. The images were obtained after 20 minutes of intravenous injection of 111-185 MBq (2 mCi) of ^{99m}Tc. The number of counts present in the thyroid was determined by outlining a manual Region of Interest (ROI) drawn around the thyroid gland and their respective backgrounds. Anterior static view with 300Kcts at 20 minutes post injection was taken. Diffusely increased RTC and absent/low BKG (Background concentration) were compatible with diffuse toxic goiter while almost absent RTC and high BKG were indicative of subacute thyroiditis.

Statistical analysis: Data editing, clearing and analysis were carried out by using the Statistical Package for Social Sciences version 23 for windows. Quantitative data was expressed as mean ± standard deviation and Qualitative data was expressed as frequency and percentage. Statistical analysis was done between PSV of Inferior thyroid artery and Tc^{99m} Thyroid Scan, where Diffuse toxic goiter belongs to group =

AandSubacute thyroiditis belongs to group = B. In each analysis level of significance was 0.05 and P value ≤ 0.05 was considered as significant.

RESULTS

Agreement between two diagnostic modality (PSV of ITA & ^{99m}Tc Thyroid scan) are given in Table-I A & I B.

Table IA: Kappa agreement statistical analysis between PSV of ITA with ^{99m}Tc Thyroid Scan for evaluation of DTG. (n=32)

Mean PSV of ITA Cm/Sec.	^{99m} Tc Thyroid Scan		Total	Kappa value	P value
	Positive	Negative			
Positive (>40)	24	0	24	0.818	<0.001 ^S
Negative(<20)	2	6	8		
Total	26	6	32		

S = significant

Table IA shows, there are total 24 positive scan and total 8 negative scan among them 2 were positive and 6 were negative. Here Kappa value = 0.818 with P value <0.05 which is statistically significant with almost perfect agreement.

Table IB: Kappa agreement statistical analysis between PSV of ITA with ^{99m}Tc Thyroid Scan for evaluation of SAT. (n = 32)

Mean PSV of ITA Cm/Sec	^{99m} Tc Thyroid Scan		Total	Kappa value	P value
	Positive	Negative			
Positive (≤20)	27	1	28	0.871	<0.001 ^S
Negative(≥40)	1	3	4		
Total	28	4	32		

TableS=SignificantIB shows, there were total 28 positive cases among them 27 were scan positive and 1 was negativeand total 4negative cases among them 1 was positive and 3 were negative. Here Kappa value = 0.871 with P value <0.05 which is statistically significant with almost perfect agreement.

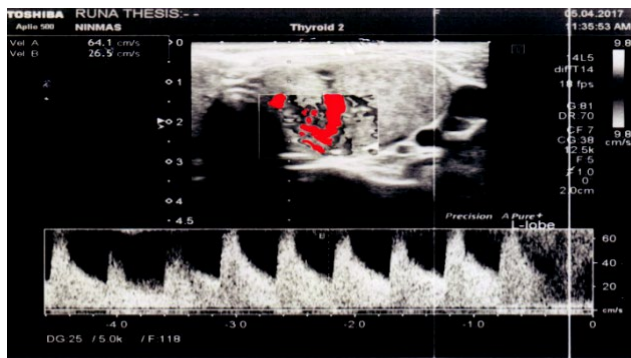


Figure 1 a: High PSV in ITA in DTG.

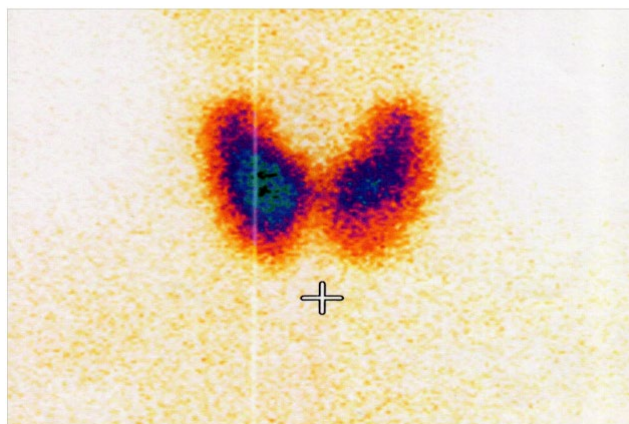


Figure 1 b: ^{99m}Tc Thyroid Scan showing diffusely increased RTC and absent BKG.

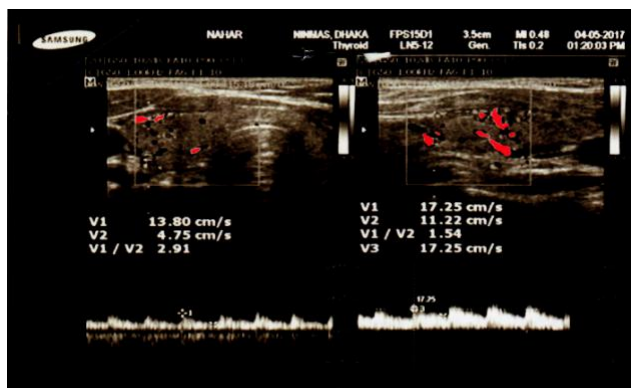


Figure 2 a: Showing low PSV in SAT patients.




Figure 2 b: ^{99m}Tc Thyroid Scan showing almost absent RTC & high BKG.

DISCUSSION

This study was carried out with an aim to see agreement between two methods PSV of ITA and ^{99m}Tc Thyroid Scan for differentiation of diffuse toxic goiter and subacute thyroiditis. In our study it was observed that majority of the patients were in 3rd decade in both group. Female was predominant (68.75% and 75%) with male to female ratio of 1:2.2 and 1:3 in DTG and SAT respectively. Common clinical findings were marked weight loss, palpitation, tachycardia and warm hand/skin in case of DTG, while palpitation and history of recent flue like episode was noted in SAT.

According to Duplex study of thyroid gland by USG it was observed that majority of the patients had thyromegaly (87.5%), heterogenous parenchymal echotexture (93.8%), increased parenchymal blood flow (90.6%) and higher PSV of ITA (75%) than reference range in case of DTG. But in case of SAT majority of the patients had thyromegaly (84.4%), non-homogenous parenchymal echotexture (81.3), decreased parenchymal blood flow (90.6%) and lower PSV of ITA (87.5%) was noted.

It was observed that majority of the patient had diffusely increased RTC with low BKG (81.3%) and almost absent RTC with high BKG (87.5%) in case of DTG and SAT respectively. According to Kappa agreement statistics it was observed that there were total 24 positive cases and no negative case among them and total 8 negative case among them 2 were positive and 6 were negative and here Kappa value=0.818 with P value <0.05 which is statistically significant with almost perfect agreement in case of DTG. It also observed that there were total 28 positive cases among them 27 were positive, 1 was negative and total 4 negative cases among them 1 was positive and 3 were negative, here Kappa value=0.871 with P value <0.05 which is statistically significant with almost perfect agreement in case of SAT.

CONCLUSION

An almost perfect agreement establishes this two modality (PSV of ITA and Tc99m Thyroid Scan) as an acceptable alternative diagnostic tools in differentiating the cause of thyrotoxicosis (Diffuse toxic goiter and Subacute thyroiditis). This results will be helpful in patients, especially pregnant and lactating mother where nuclear imagine is contraindicated.

REFERENCES

1. Donkol RH, Nada AM and Boughattas S. Role of color doppler in differentiation of Graves' disease and thyroiditis in thyrotoxicosis. *World J Radiol* 2013 Apr 28;5(4):178-83. doi:10.4329/wjr.v5.i4.178 .
2. Ross DS, Burch HB, Cooper DS, Greenlee MC, Laurberg P. American Thyroid Association Guidelines for Diagnosis and Management of Hyperthyroidism and Other Causes of Thyrotoxicosis. *Open Access J Clin* 2016 Oct;26(10):1343-1421. doi: 10.1089/thy.2016.0229.
3. Abdel Ghany AF and Nassef MA. Co-relation between color Duplex and Tc99m thyroid scan in identifying the cause of Toxic goitre. *IJNMR* 2014 Aug 12;1(1):17-22. <http://www.ijnmr.org/licenses/by-nc/3>.
4. Bhargava A, Thyroid Disorders & Their Differentiation. *Open Access Journ* 2015;4(1):167-71. doi: 10.4172/2167-7948.1000e117.
5. Vitti P, Rago T and Mazzeo S. Thyroid blood flow evaluation by color-flow Doppler sonography distinguishes Graves' disease from Hashimoto's thyroiditis. *J Endocrinol Invest* 1995 Dec;18(11):857-61. doi:10.1007/BF03349833
6. Banaka I, Thomas D and Kaltsas G. Value of the left inferior Thyroid Artery Peak Systolic Velocity in Diagnosing Autoimmune Thyroid Disease. *J Ultrasound Med* 2013 Nov;32(11):1969-78. doi: 10.7863/ultra.32.11.1969.
7. Shyh CC, Peng YS, Chen PY and Yeh HY. Color Doppler Ultrasonography of Inferior Thyroid Artery and Its Relation with Thyroid Functional State. *Med Ultrason* 2006;14(3):51-56. doi:10.1186/1471-2342-5-6
8. Kim TK and Lee EJ. The value of the mean peak systolic velocity of the superior thyroidal artery in the differential diagnosis of thyrotoxicosis. *Ultrasonography* 2015 Mar 24;34(4):292-96. doi: 10.14366/usg.14059
9. Che Han C, Chou S C, Peng YS and Weng HH. Reliable Parameters of Colour Doppler Ultrasonography for Predicting Thyroid Function. *Chin J Radiol* 2009; 34:21-26.
10. Dos Santos TA RR, Pina ROG, De Souza MTP and Chammas MC. Graves' Disease Thyroid Color-Flow Doppler Ultrasonography Assessment: Review Article 2014;6: 1487-1497.