

A Case Report on Parathyroid Carcinoma: A Diagnostic Dilemma

Farida Yasmin¹, Hosne Ara Rahman¹, Samira Sharmin¹ and Monir Uddin²¹ Institute of Nuclear Medicine and Allied Sciences, Mitford, Dhaka ²Department of Radiology and Imaging, Cumilla Medical College, Cumilla.
Address of Correspondence: Dr. Farida Yasmin, Medical Officer, Institute of Nuclear Medicine and Allied Sciences, Mitford, Sir Salimullah Medical College Campus, Dhaka. Email: farida.sb.38@gmail.com

ABSTRACT

Parathyroid Carcinoma is a rare cause of primary hyperparathyroidism. Pre-operative diagnosis remains a challenge. Here we report a case referred to us for suspicious goiter with hypercalcemia. Cytological findings suggested it to a possible thyroid mass rather than parathyroid neoplasm. Serum parathormone level was high and the patient underwent surgery. Histopathology confirmed the diagnosis of parathyroid carcinoma. A diagnostic approach to parathyroid neoplasm, combining multimodality imaging and clinico-pathologic features, is discussed.

Keywords: Hypercalcemia, Hyperparathyroidism, Parathyroid carcinoma.

Bangladesh J. Nucl. Med. Vol. 21 No. 2 July 2018

Doi : <https://doi.org/10.3329/bjnm.v21i2.40368>

INTRODUCTION

Parathyroid carcinoma is a rare endocrine malignancy which usually accounts for less than 1% of all cases of hyperparathyroidism (1). The 45-55year age group is the most affected with a slight predominance of cases in women (2). The sign and symptoms of parathyroid carcinoma are bone pain, osteoporosis, renal stones, abdominal pain and weight loss. Physical examination may reveal a cervical mass and the biochemical abnormalities are elevated serum calcium and parathormone levels. Here we report an interesting case of parathyroid carcinoma because of its rarity as well as possible cytological and histological diagnostic dilemmas.

CASE REPORT

A 44 years old female was referred to INMAS, Mitford with neck swelling and hypercalcemia. She also complained of bony pain, abdominal pain, weight loss

and difficulty in movement for one year. On clinical examination, a mass was palpable in the region of thyroid gland Serum biochemistry was showing features of severe hyperparathyroidism [Parathormone 2183.1pg/ml (range 10-65pg/ml); Calcium 12.9 mg/dl (range 8.5-10.2 mg/dl)]. Serum creatinine (0.88 mg/dl) was however normal. Thyroid function tests also indicated normal status (FT4- 8.88 pmol/L, TSH- 3.08 mIU/L). Ultrasonogram (USG) neck revealed 5.3 × 3.8 cm U3 nodules with both solid and cystic components in right thyroid bed which was more likely to be thyroid origin rather than parathyroid origin (Figure 1). X-ray of right hip joint showed fracture at the neck of right femur. X-ray Mandible showed multiple lytic lesions in the body of the mandible. Contrast enhanced CT scan of neck was suggestive of malignant thyroid mass having mediastinal extension with expansible lytic lesions noted at body of the mandible, right sided angle of mandible and anterior aspect of maxilla (Figure.2).

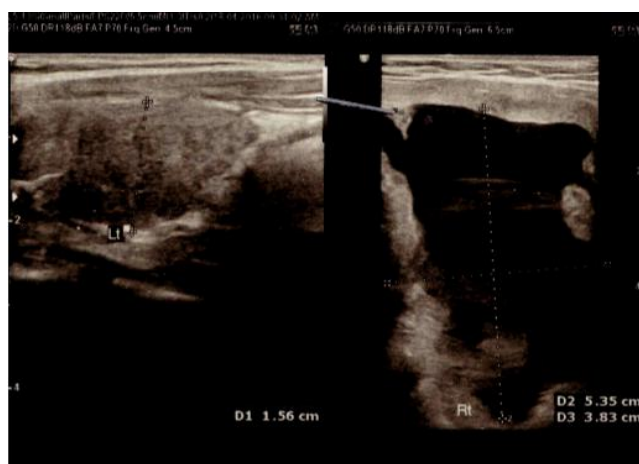

Figure 1. Ultrasound imaging of Neck region.

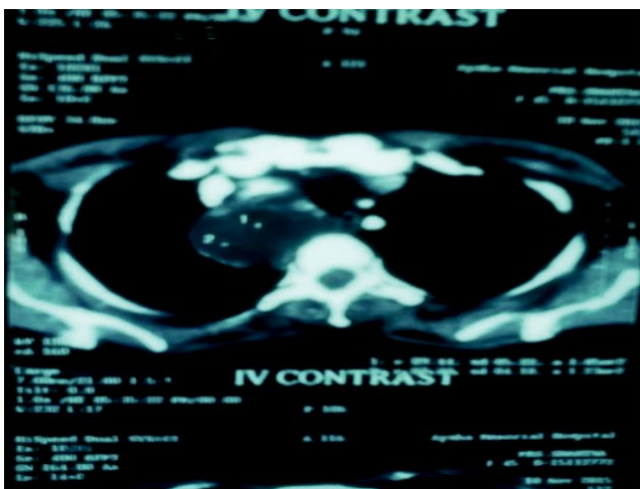

Figure 2. CT scan of Neck

FNAC revealed malignant lesion of thyroid origin. As severe hyperparathyroidism could not be explained by CT and FNAC findings of possible thyroid origin, Tc-99m MIBI parathyroid scintigraphy was then performed to evaluate the parathyroid gland. A single tracer dual phase SPECT was done with intravenous injection of 20 mCi of Tc-99m MIBI. Early phase images showed diffuse area of increased tracer uptake in the anterior neck with central large photon deficient area (corresponding to the palpable mass previously identified as cystic in nature by USG) (Figure 3). Delayed (post 2 hour) phase images showed significant washout of tracer (Figure 4) which was more in favor of thyroid origin of the mass rather than parathyroid. Finally, the patient underwent surgery and histopathology report confirmed parathyroid carcinoma.

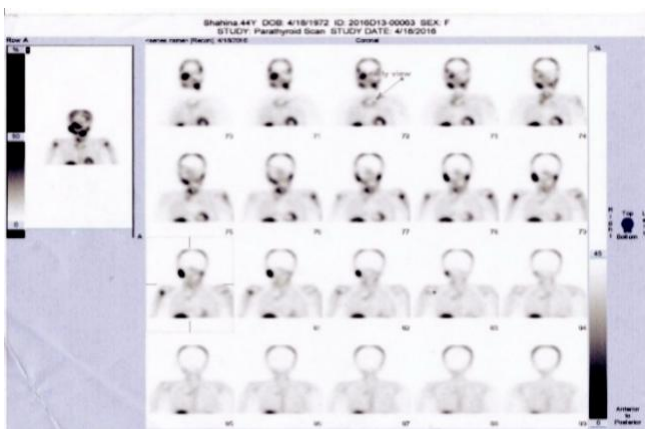


Figure 3. Early phase of parathyroid scan

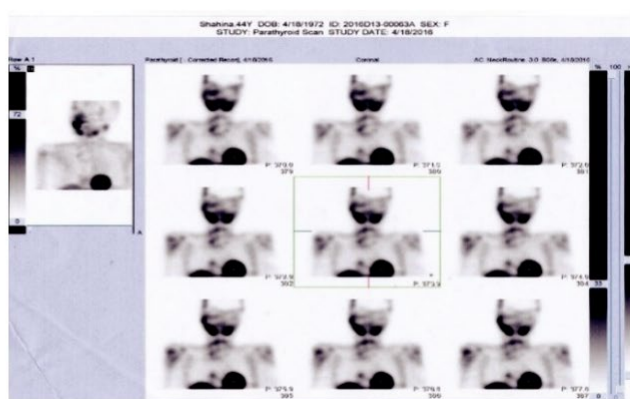


Figure 4. Delayed phase of parathyroid scan

DISCUSSION

Parathyroid carcinoma is a rare cause of primary hyperparathyroidism. The clinical criteria for suspicion of malignant parathyroid neoplasm as said by Obara et al are: age below 55years; marked hypercalcemia and hyperparathormonaemia; severe bone symptoms and kidney symptoms; recurrent laryngeal paralysis due to tumor invasion; palpable cervical swelling that are rare in benign disease (3, 4). Definitive diagnosis of parathyroid carcinoma requires multimodality approaches including clinico-pathological, biochemical, radiological, scintigraphy findings and finally histopathology.

Our patient had markedly high level of serum parathormone and high level of calcium with a palpable neck mass which all were in favor of parathyroid origin of mass.

USG is a good tool to localize parathyroid tumor. But in our patient USG neck showed large complex mass in right thyroid bed and its origin, whether thyroid or parathyroid, could not be ascertained.

Cytologically, often it is impossible to differentiate between thyroid and parathyroid tumor because there is significant overlapping in the cytomorphologic features of cells derived from parathyroid and thyroid gland (5). Although FNAC report of our patient gave false negative result but parathyroid neoplasm should be kept in mind as differential diagnosis in case of palpable neck mass with hyperparathyroidism.

Tc-99m- MIBI parathyroid scintigraphy is extremely useful in preoperative localization of parathyroid neoplasm (sensitivity 89% - 98%), although it is less reliable in distinguishing adenoma from carcinoma (6, 7). Mitochondrial uptake of sestamibi in abnormal parathyroid tissue is the primary mechanism underpinning lesion localization (8). The nodular mass in our case showed sestamibi uptake, confined to the solid components of the tumor with no uptake in the central cystic part. Delayed imaging showed significant washout of tracer which was more consistent with thyroid origin of the mass because parathyroid lesion usually shows retention of tracer. As cystic parathyroid lesions are a recognized cause of false negative sestamibi imaging (9), it made a diagnostic dilemma in our case in spite of its high sensitivity to diagnose parathyroid neoplasm.

Ultimate gold standard is histopathology which revealed that it was a case of parathyroid carcinoma and solved all the dilemmas.

CONCLUSION

Parathyroid carcinoma, although rare, must be considered in the differential diagnoses of a nodular thyroid mass. They are often under diagnosed preoperatively, resulting in diagnostic dilemma.

REFERENCES

1. Shane E. Parathyroid carcinoma. *J Clin Endocrinol Metab* 2001;86(2):485-93. doi:10.1210/jcem.86.2.7207
2. Sturniolo G, Gagliano E, Tonante A. et al. Parathyroid carcinoma: case report. *G Chir* 2013;34(5-6):170-172. doi: 10.11138/gchir/2013.34.5.170
3. Obara T, Fujimoto Y. Diagnosis and treatment of patients with parathyroid carcinoma: an update and review. *World J Surg* 1991;15(6):738-44. doi:10.1007/bf01665308
4. Givi B, Shah JP. Parathyroid carcinoma. *Clin Oncol (R Coll Radiol)* 2010; 22(6):498-507. doi: 10.1016/j.clon.2010.04.007
5. Dimashkieh H, Krishnamurthy S. Ultrasound guided fine needle aspiration biopsy of parathyroid gland and lesions. *Cytojournal* 2006;3:6. doi: 10.1186/1742-6413-3-6
6. Abdelgadir Adam M, Untch BR, Olson JA., Jr. Parathyroid carcinoma: Current understanding and new insights into gene expression and intraoperative parathyroid hormone kinetics. *Oncologist* 2010;15(1):61-72. doi: 10.1634/theoncologist.2009-0185
7. Chen CC, Holder LE, Scovili WA, Tehan AM, Gann DS. Comparison of parathyroid imaging with technetium-99m-pertechnetate/sestamibi subtraction, double-phase technetium-99m-sestamibi and technetium-99m-sestamibi SPECT. *J Nucl Med* 1997;38(6):834-9
8. Hetrakul N, Civelek AC, Stagg CA, Udelsman R. In vitro accumulation of technetium-99m-sestamibi in human parathyroid mitochondria. *Surgery* 2001;130(6):1011-8. doi: 10.1067/msy.2001.118371
9. Johnson NA, Yip L, Tiblin ME. Cystic parathyroid adenoma: sonographic features correlation with 99m Tc-sestamibi SPECT findings. *AJR Am J Roentgenol* 2010;195(6):1385-1390. doi: 10.2214/AJR.10.4472