

Sentinel Lymph Node Mapping with Gamma Probe in Carcinoma of Breast: Initial Experience in Evercare Hospital Dhaka

¹Sharmin Farhana, ¹Taslima Sifat, ¹Mohammed F. Hossain, ³Shohag Mia, ¹Ruhul Quddus, ³Mizanul Hasan, ⁴Jasmine Ara Haque, ¹Raihan Hussain and ¹Mohammed F. Kabir

¹Department of Nuclear Medicine & Molecular Imaging, Evercare Hospital Dhaka;

²Department of General & Laparoscopic Surgery, Evercare Hospital Dhaka;

³National Institute of Nuclear Medicine and Allied Sciences (NINMAS), BSMMU Campus, Dhaka;

⁴Institute of Nuclear Medicine and Allied Sciences (INMAS), DMCH Campus, Dhaka

Correspondence Address: Dr. Sharmin Farhana, Sr. Specialist, Nuclear Medicine & Molecular Imaging Department, Evercare Hospital, Dhaka - 1229, Bangladesh, Email: sharmin.farhana@evercarebd.com

ABSTRACT

Background: The sentinel lymph node (SLN) is the first draining node from a cancer-bearing area and therefore can manifest metastasis. In breast cancer SLN has been shown to predict the axillary nodal stage. Axillary dissection provides information determining prognosis and need for adjuvant therapy but often carries certain morbidities. Our aim was to determine the feasibility of detecting the SLN and whether the SLN accurately predicts the axillary status.

Materials and Methods: Twelve patients having mean age of 40.5 ± 10.9 years, ranging from 28 to 56 years with stage I and II breast cancer and non-palpable axillary nodes from November 2016 to December 2018 were included in this study. The sentinel node was detected with Tc-99m-labelled nano colloid (radiotracer). Dual Head SPECT Gamma Camera and Gamma Probe was used in the same sitting for identification and surface marking of the SLN. Surgical resection of SLN was done followed by frozen section biopsy.

Results: The tumor size ranged from $<2\text{cm}$ to $\leq 5\text{cm}$, SLNs were identified in 11 out of 12 cases, one SLN in 9 patients and two SLNs in remaining two patients during SLN mapping.

Conclusion: This was an initial experience in a single hospital, where SLN mapping and biopsy proved feasible and successful. By this method, patients who are negative on frozen section biopsy would be spared from axillary lymph node dissection. However, further practice is required to reach a firm conclusion and long term follow up is also essential.

Key words: Sentinel lymph node, Gamma probe, Breast Cancer.

Bangladesh J. Nucl. Med. Vol. 24 No. 1 & 2 2021

Doi: <https://doi.org/10.3329/bjnm.v24i1-2.59330>

INTRODUCTION

Breast cancer is a major health problem and is among the top three most common malignancies globally (1). It ranks fifth among the most common causes of

cancer-related mortality worldwide, while it is the most frequent cause of cancer death in less developed countries (2). At present, almost 90% of patients diagnosed with breast cancer survive up to 5 years, with survival being strongly associated with the stage at time of diagnosis (3).

The axillary lymph nodal status is one of the most important prognostic factor in women with early stage breast cancer. Axillary dissection provides information, determining prognosis and need for adjuvant therapy, but often carries certain morbidities (4,5). Sentinel lymph nodes (SLN) are the regional nodes that directly drain lymph from the primary tumour. Thus, SLNs are the first nodes to receive lymph-borne metastatic cells (6). Since two decades, SLN mapping and biopsy have become routine techniques in breast cancer management, contributing to the development of less-invasive surgical procedures (7-14). This procedure has replaced routine staging axillary nodal dissection in patients with early-stage biopsy-proven breast carcinoma without cytologically or histologically proven axillary lymph node metastases (15,16). Our aim was to determine the feasibility of detecting the SLN and whether the SLN accurately predicts the axillary status.

PATIENTS AND METHODS

Twelve patients with mean age 40.5 ± 10.9 years, ranging from 28 to 56 years were selected, who had early stages (I and II) of breast cancer with non-palpable axillary lymph

nodes. The exclusion criteria were pregnancy, having history of previous axillary surgery and having advanced cancer with enlarged axillary nodes. The radiopharmaceutical used was nanocolloid, Nanoscan produced by Radiopharmacy Laboratory Ltd, Budaros, Hungary. Siemens E.CAM Dual Headed SPECT was used for SLN mapping and Capintec Gamma Probe (Europrobe) for identification and surface marking of the SLN.

In this study, 0.5 - 0.8mCi (20-30MBq) of nanocolloid was taken in a 1-ml syringe and was injected intradermally (Figure 1) in areola of the affected breast in approximately equal four divided doses in four quadrants of breast (Figure 2).

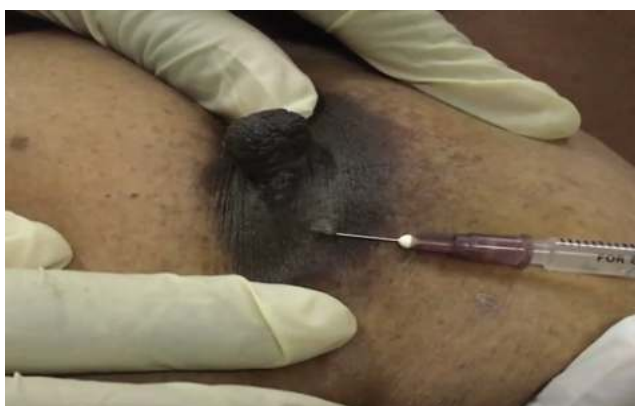

Figure 1: Intradermal injection with bleb formation in site I



Figure 2: Immediately after injections at four sites around the nipple showed early lymphatic drainage towards axilla.

Dynamic sequential 10 sec images were obtained in anterior and lateral projections for 5 minutes immediately after injections. Then images were taken every 5 minutes for 1 minute till 45 minutes (Figure 3).

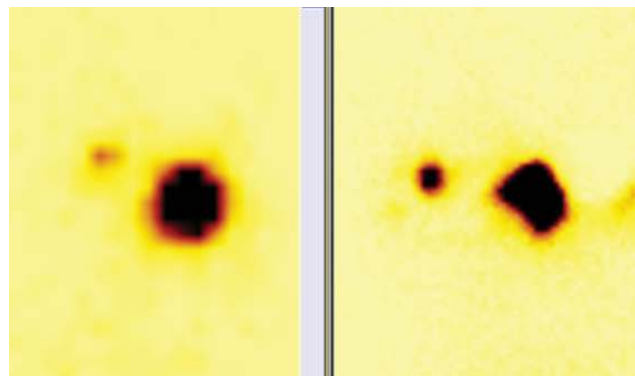


Figure 3: Injection sites with gradual prominence of the sentinel lymph node activity

If SLN was not visualized, delayed imaging was done after 2 hours. Radioactive marker was used to correspond with the SLN activity and location was marked on the skin. Gamma probe was used to reconfirm the SLN (Figure 4). Surgical resection of SLN was done (Figure 5, 6) followed by frozen section biopsy.

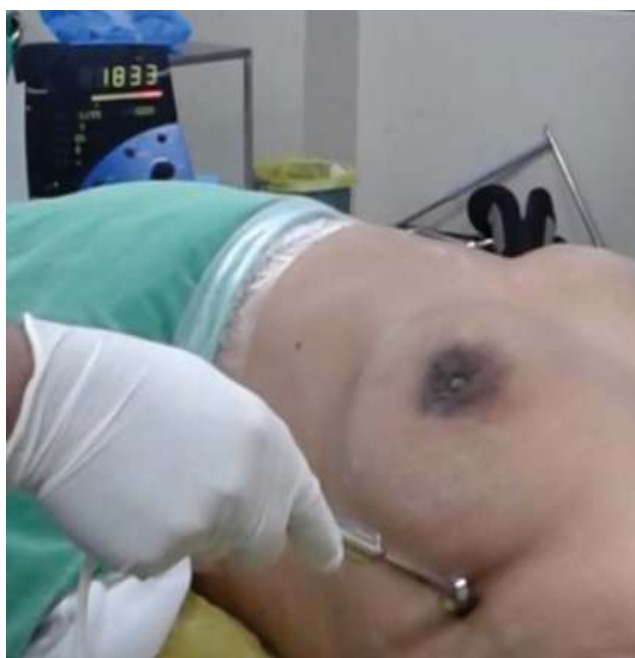

Figure 4: Confirmation of SLN with Gamma Probe before surface marking; high count rate is seen in the machine display.

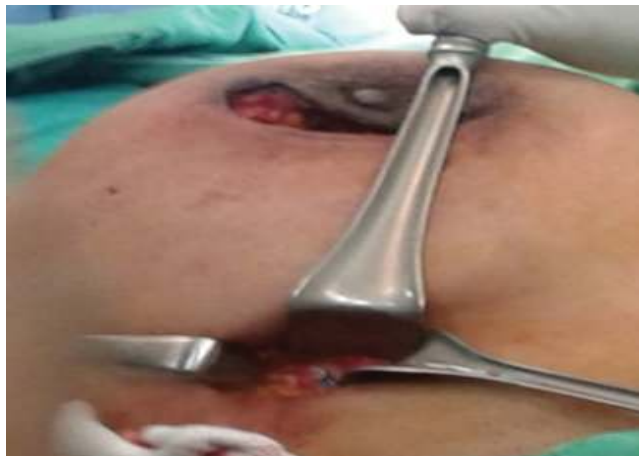

Figure 5: Surgical exploration and extraction of SLN from axilla

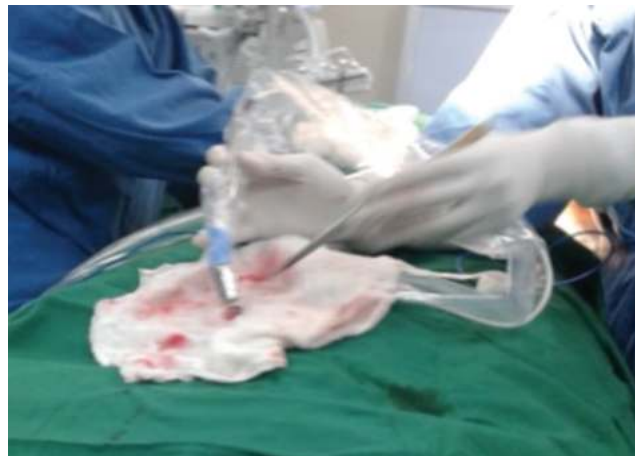

Figure 6: Confirmation of SLN in excised sample by Gamma Probe

RESULTS

Among the 12 patients (the tumor size ranged from <2cm to ≤5cm), tumour lump was palpable in all 12 patients (6 on right & 6 on left breasts). SLNs were successfully identified in 11 out of 12 cases, one SLN in 9 patients and two SLNs in remaining two patients during SLN mapping (Table 1). Intra-operative Gamma probe findings were well correlated.

Table 1 : Demographic data, investigative findings & management

Pt. No.	Age (Yrs)	Stage	Preoperative Findings (Lump)	SLN Detected (number)	Intra-operative Surgical Correlation	Frozen Section Biopsy for metastasis of SLN	Management
1	56	I	Lt. breast	0	x	x	x
2	30	II	Rt. breast	1	Correlates	-ve	Lumpectomy
3	46	II	Rt. breast	2	Correlates	-ve	Lumpectomy
4	42	I	Rt. breast	1	Correlates	-ve	Lumpectomy
5	50	II	Lt. breast	1	Correlates	+ve	Mastectomy
6	30	I	Rt. breast	1	Correlates	-ve	Lumpectomy
7	52	II	Rt. breast	2	Correlates	-ve	Lumpectomy
8	54	II	Lt. breast	1	Correlates	+ve	Mastectomy
9	40	I	Rt. breast	1	Correlates	-ve	Lumpectomy
10	30	II	Lt. breast	1	Correlates	-ve	Lumpectomy
11	28	I	Lt. breast	1	Correlates	-ve	Lumpectomy
12	28	II	Rt. breast	1	Correlates	-ve	Lumpectomy

Frozen section biopsy to confirm metastases was positive in two cases. These two cases had mastectomy whereas the rest had only lumpectomy.

DISCUSSION

The presence of tumor cells in regional nodes is merely a sign of regional progression and an indicator of systemic dissemination of disease (17). Accurate lymph node staging is essential for both prognosis (of early-stage disease)

and treatment (for regional control of disease) in patients with breast cancer. Lymphoscintigraphy (LS) method helps the surgeon to easily identify and the biopsy of a SLN. No imaging modality is so accurate to detect lymph node metastases when a primary breast cancer is at an early stage, but SLN biopsy is a very reliable method for screening axillary nodes and for identifying metastatic and micrometastatic disease in regional lymphatic nodes (14, 18, 19).

The role of Axillary Lymph Node Dissection (ALND) in patients with N_0 disease has been scrutinized as most of them (70%–80%) will have pathologically free nodes (pN_0) (20). Thus, subjecting these patients to ALND exposes most of them to unnecessary morbid outcomes, such as arm lymphedema, axillary numbness, and shoulder abduction deficits (7,21)

SLN biopsy is a safe and reliable operation that gives an accurate assessment of nodal metastasis for the early breast cancer patients (22). Several ^{99m}Tc based agents have been used for radioguided SLN biopsy in breast cancer including colloid particles e.g. (Antimony trisulphide commonly used in Australia and Canada; Nanocolloid Albumin in Europe; Sulphur Colloid in USA) (23). SLNs are generally visualized within 1–2 h, and the patient should be in the operation theater (O.T.) within 2–30 h of the injection of the colloid, depending on the facility's schedule (6, 15, 24). If surgery is scheduled for early morning, injection and imaging may be safely performed in the previous afternoon prior to the day of surgery (25).

Among the 12 patients this study, SLN was successfully identified in 11 patients; one SLN in 9 patients and two SLNs in remaining two patients during SLN mapping. All SLNs were identified within 45 minutes. No SLN was observed in the contralateral side. After SLN mapping these patients were sent to OT Gamma probe was used during surgery to identify the SLNs and surgical resection of SLN was done followed by frozen section biopsy, which showed positive metastases in two cases. Out of these 11 (91.7%) patients, two (16.7%) with metastases underwent mastectomy with axillary clearance; whereas only lumpectomy was done in the remaining 9 (75%) patients who had no metastasis.

Sentinel Lymph Node Biopsy (SLNB) is recommended for early staging in patients with T1-2 invasive breast cancer and clinically negative axillary nodes irrespective of surgical therapy on the breast (26). Inflammatory breast disease and patients with clinically positive axillary nodes are the two absolute contraindications for a SLNB (27). These patients would require axillary dissection. SLN biopsy has significantly lower morbidity than axillary lymphadenectomy (28), and it has nodal relapse rates at 5 years similar to those of axillary lymphadenectomy (29).

CONCLUSION

SLN mapping has been performed and tested in different countries since long, but there has not been any significant activity reported in Bangladesh. Although it was the initial experience in a single hospital, SLN mapping and biopsy proved feasible and successful. By this method, patients who are negative on frozen section biopsy would be spared from axillary node dissection. However, further work on this is required to reach a firm conclusion and long term follow up is also essential.

REFERENCES

1. International Agency for Research on Cancer. Estimated number of incident cases, worldwide (top 10 cancer sites) in 2012.
2. World Health Organization. GLOBOCAN: International Agency for Research on Cancer. Section of Cancer Information. 2018 Sep.
3. Hankey BF, Ries LA, Edwards BK. The surveillance, epidemiology, and end results program: a national resource. *Cancer Epidemiology and Prevention Biomarkers*. 1999 Dec 1;8(12):1117-21.
4. Lyman GH, Giuliano AE, Somerfield MR, Benson AB, Bodurka DC, Burstein HJ, Cochran AJ, Cody HS, Edge SB, Galper S, Hayman JA. American Society of Clinical Oncology guideline recommendations for sentinel lymph node biopsy in early-stage breast cancer. *Journal of clinical oncology*. 2005;23(30):7703-20.
5. McMasters KM, Tuttle TM, Carlson DJ, et al. Sentinel lymph node biopsy for breast cancer: a suitable alternative to routine axillary dissection in multi-institutional practice when optimal technique is used. *J Clin Oncol* 2000;18(13):2560–6.
6. Keshtgar MRS, Ell PJ. Sentinel lymph node detection and imaging. *Eur J Nucl Med* 1999;26:57–67.
7. Krag DN, Weaver D, Alex JC, Fairbank JT. Surgical resection and radiolocalization of sentinel lymph node in breast cancer using a gamma probe. *Surg Oncol* 1993;2:335–9.
8. Giuliano AE, Kirgan D, Guenther JM, Morton DL. Lymphatic mapping and sentinel lymphadenectomy for breast cancer *Ann Surg* 1994;220:391–401.

9. Noguchi M, Katev N, Miyazaki I. Diagnosis of axillary lymph node metastases in patients with breast cancer. *Breast Cancer Res Treat* 1996;40:283–93.
10. Taylor A, Murray D, Herda S, Vansant J, Alazraki N. Dynamic lymphoscintigraphy to identify the sentinel and satellite nodes. *Clin Nucl Med* 1996;21:755–8.
11. Pijpers R, Meijer S, Hoekstra OS, Collet GJ, Comans EF, Boom RP, et al. Impact of lymphoscintigraphy on sentinel node identification with technetium-99m-colloid albumin in breast cancer. *J Nucl Med* 1997;38:366–8.
12. Giuliano AE. Lymphatic mapping and sentinel node biopsy in breast cancer. *JAMA* 1997;277:791–2.
13. Veronesi U, Paganelli G, Galimberti V, Viale G, Zurrada S, Bedoni M, et al. Sentinel node biopsy to avoid axillary dissection in breast cancer patients with clinically negative lymph-nodes. *Lancet* 1997;349:1864–7.
14. Benson JR, Della Rovere GQ, Axilla Management Consensus Group. Management of the axilla in women with breast cancer. *Lancet Oncol* 2007;8:331–48.
15. De Cicco C, Cremonesi M, Luini A, Bartolomei M, Grana C, Prisco G, et al. Lymphoscintigraphy and radioguided biopsy of the sentinel axillary node in breast cancer. *J Nucl Med* 1998;39:2080–4.
16. Kaufmann M, Morrow M, von Minckwitz G, Harris JR, Biedenkopf F, Expert Panel Members. Locoregional treatment of primary breast cancer: consensus recommendations from an International Expert Panel. *Cancer* 2010;116:1184–91.
17. Borgstein PJ, Pijpers R, Comans EF, et al. Sentinel lymph node biopsy in breast cancer: guidelines and pitfalls of lymphoscintigraphy and gamma probe detection. *J Am Coll Surg* 1998; 186(3):275–83.
18. Veronesi U, Paganelli G, Viale G, Luini A, Zurrada S, Galimberti V, et al. A randomized comparison of sentinel-node biopsy with routine axillary dissection in breast cancer. *N Engl J Med* 2003;349:546–53.
19. Veronesi U, Paganelli G, Viale G, Luini A, Zurrada S, Galimberti V, et al. Sentinel-lymph-node biopsy as a staging procedure in breast cancer: update of a randomized controlled study. *Lancet Oncol* 2006;7:983–90.
20. Morton DL, Wen DR, Wong JH, et al. Technical details of intraoperative lymphatic mapping for early stage melanoma. *Arch Surg* 1992; 127(4):392–9.
21. Schwartz GF. Clinical practice guidelines for the use of axillary sentinel lymph node biopsy in carcinoma of the breast: current update. *Breast J* 2004; 10(2):85–8.
22. Chatterjee A, Serniak N, Czerniecki BJ. Sentinel lymph node biopsy in breast cancer: a work in progress. *Cancer Journal*, 01 Jan 2015, 21(1):7-10
23. Wilhelm AJ, Mijnhout GS, Franssen EJF. Radiopharmaceuticals in sentinel lymph-node detection – an overview. *Eur J Nucl Med* 1999;26:S36–42.
24. Buscombe J, Paganelli G, Burak ZE, Waddington W, Maublant J, Prats E, et al. Sentinel node in breast cancer procedural guidelines. *Eur J Nucl Med Mol Imaging* 2007;34:2154-9.
25. Babiera GV, Delpassand ES, Breslin TM, Ross MI, Ames FC, Singletary SE, et al. Lymphatic drainage patterns on early versus delayed breast lymphoscintigraphy performed after injection of filtered Tc-99m sulfur colloid in breast cancer patients undergoing sentinel lymph node biopsy. *Clin Nucl Med* 2005; 30(1):11–5.
26. Lyman GH, Temin S, Edge SB, et al. Sentinel lymph node biopsy for patients with early- stage breast cancer: American Society of Clinical Oncology clinical practice guideline update. *J Clin Oncol* 2014; 32(13):1365–83.
27. Krontiras H, Bland KI. When is sentinel node biopsy for breast cancer contraindicated? *Surg Oncol* 2003; 12(3):207–10.
28. Purushotham AD, Upponi S, Klevesath MB, Bobrow L, Millar K, Myles JP, et al. Morbidity after sentinel lymph node biopsy in primary breast cancer: results from a randomized controlled trial. *J Clin Oncol* 2005;23:4312–21.
29. Van der Ploeg IM, Nieweg OE, van Rijk MC, Valdes Olmos RA, Kroon BB. Axillary recurrence after a tumor-negative sentinel node biopsy in breast cancer patients: a systematic review and meta-analysis of the literature. *Eur J Surg Oncol* 2008;34:1277–84.