

# Osteoporosis in an Adolescent Female: A Case Report

<sup>1</sup>Abdullah Al Persi, <sup>1</sup>Muhammad Farhan Muhtasim, <sup>2</sup>Noor-e Amrin Alim, <sup>3</sup>Mohammad Sazzad Hossain, <sup>3</sup>Anjuman Ara Akhter, <sup>3,4</sup>Pabitra Kumar Bhattacharjee

<sup>1</sup> Medical Officer, <sup>2</sup>Senior Medical Officer, <sup>3</sup> Chief Medical Officer, <sup>4</sup> Director  
Institute of Nuclear Medicine & Allied Sciences (INMAS), Chattogram.

**Correspondence Address :** Dr Abdullah Al Persi, Medical Officer, INMAS, CMCH Campus, Chattogram-4203. Email: abdullah.persi@gmail.com

## ABSTRACT

Osteoporosis constitutes a significant disease burden globally. While this disease has been historically associated with postmenopausal women and elderly men, osteoporosis in younger adults does occur in the setting of chronic disease, medications that affect bone metabolism, and other risk factors. Among those, glucocorticoids are an important risk factor for bone fragility in children or young adults with serious illnesses, largely due to their direct adverse effects on skeletal metabolism. In this report, we present a case of a 16-year-old female diagnosed with glucocorticoid-induced osteoporosis (GIO). She had been on prednisolone for more than a year owing to progressive glomerulonephritis with a nephrotic picture. She developed severe low back pain and restricted mobility and sought urgent care. Spine radiographs showed osteoporotic changes, which warranted further investigations including bone mineral densitometry (BMD) by dual energy x-ray absorptiometry (DXA). BMD revealed a T-score and Z-score of -3.1 at lumbar spine, suggestive of osteoporosis. In light of her medical history and the BMD findings along with a low basal cortisol level, a diagnosis of glucocorticoid-induced osteoporosis (GIO) was made. She was commenced on Teriparatide, a recombinant human parathyroid hormone analog and subsequently discharged upon regaining ambulation.

**Keywords:** Secondary Osteoporosis; Adolescent; Nephrotic syndrome; Glomerulonephritis; Glucocorticoids; Bone mineral densitometry (BMD); Dual energy x-ray absorptiometry (DXA).

Bangladesh J. Nucl. Med. Vol. 26 No. 2 July 2023

DOI: <https://doi.org/10.3329/bjnm.v26i2.71473>

## INTRODUCTION

Osteoporosis in children or adolescents differs from adults in terms of definition, diagnosis, monitoring and treatment options. In addition to primary osteoporosis, there are significant other causes of bone fragility in children. Secondary osteoporosis can be a result of a plethora of conditions including leukemia and other cancers, systemic inflammatory and autoimmune disorders (such as, but not limited to, inflammatory bowel disease, and rheumatic conditions including systemic lupus erythematosus, systemic-onset juvenile arthritis, juvenile dermatomyositis,

systemic vasculitis, and overlap syndromes), renal diseases (e.g., nephrotic syndrome), neuromuscular conditions and organ transplantation. The reported adolescent female of secondary osteoporosis was exposed to prolonged glucocorticoid therapy.

## CASE REPORT

A 16-year-old teen age girl presented with severe low back pain that restricted her mobility to the extent that she was bedridden and sought urgent medical care. Dorso-lumbar spine x-rays were requested, which revealed osteoporotic changes (Figure 1). Given the oddity of these findings in such an age group along with the severity of her symptoms, she was admitted to Chittagong Medical College Hospital (CMCH) to be treated as an in-patient.

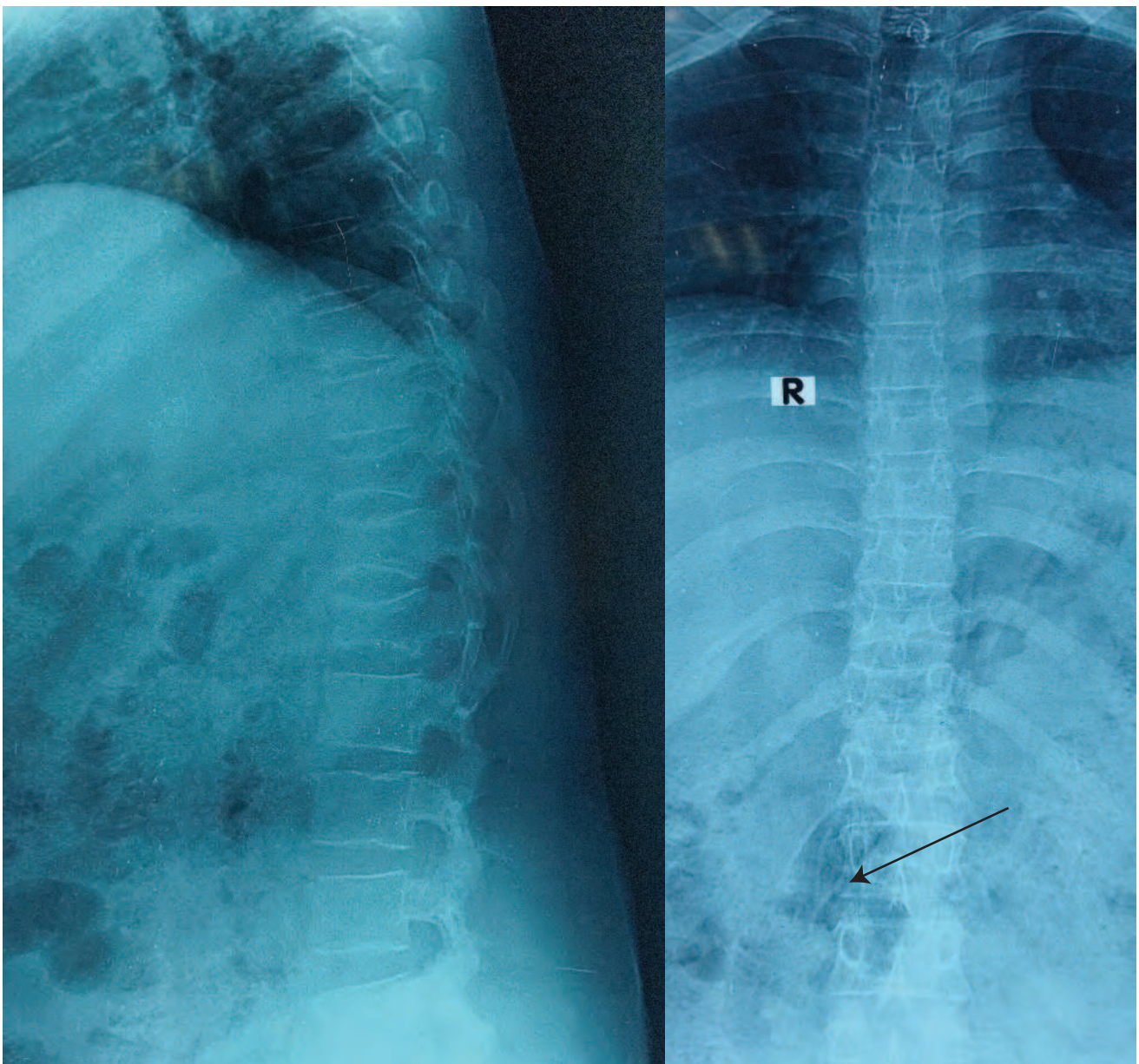
She had an eventful medical history, which was significant for glomerulonephritis with a nephrotic picture and three relapses. Her first presentation was in late 2022, with the complaints of generalized swelling and weakness. Proteinuria, hypoalbuminaemia and elevated urinary protein-creatinine ratio (PCR) supported the diagnosis and she was commenced on prednisolone, which was later tapered gradually. Three months later her condition relapsed, likely triggered by down-titration of glucocorticoids. This necessitated the increase in dosage of prednisolone.

However, she experienced another relapse about 3 months after the first one which warranted hospitalization. Prednisolone was resumed in therapeutic dosage and subsequently, a renal biopsy was performed. Histopathology revealed mild segmental mesangial cell hyperplasia as well as patchy acute tubular injury, tubular atrophy and interstitial fibrosis along with arterial endothelial cell hyperplasia: all of which were of mild grade. Direct immunofluorescence panel was negative for IgA, IgG, IgM, C3 and C1q. A diagnosis of focal segmental mesangial proliferative glomerulonephritis

(MesPGN) was established. Upon recovery, she was discharged from the hospital and continued to be on glucocorticoids.

Although it was back pain that compelled her latest visit to the hospital, it was characterized as a third relapse as evidenced by proteinuria and deranged urinary PCR upon investigation. The unexpected finding of decreased bone density on dorso-lumbar spine radiographs called for further tests, which included basal cortisol and bone mineral densitometry (BMD). Early morning cortisol level was recorded as 0.765  $\mu\text{g/dL}$  (reference range: 3.7-19.4  $\mu\text{g/dL}$ ) which was low, and therefore indicated adrenal

suppression. BMD measurement by dual energy x-ray absorptiometry (DXA) was done at our institution and revealed a T-score of -3.1 and a Z-score of -3.1 as well at spine (L1-L4), consistent with osteoporosis and a high fracture risk (Figure 2, Table 1). Thus, a diagnosis of glucocorticoid-induced osteoporosis (GIO) was made. Definitive therapy with Teriparatide, a recombinant human parathyroid hormone analog (PTH 1-34) subcutaneous injection to be administered once daily was prescribed, along with vitamin-D supplement as adjunct. Patient was discharged upon regaining ambulation with the advice to follow up regularly.

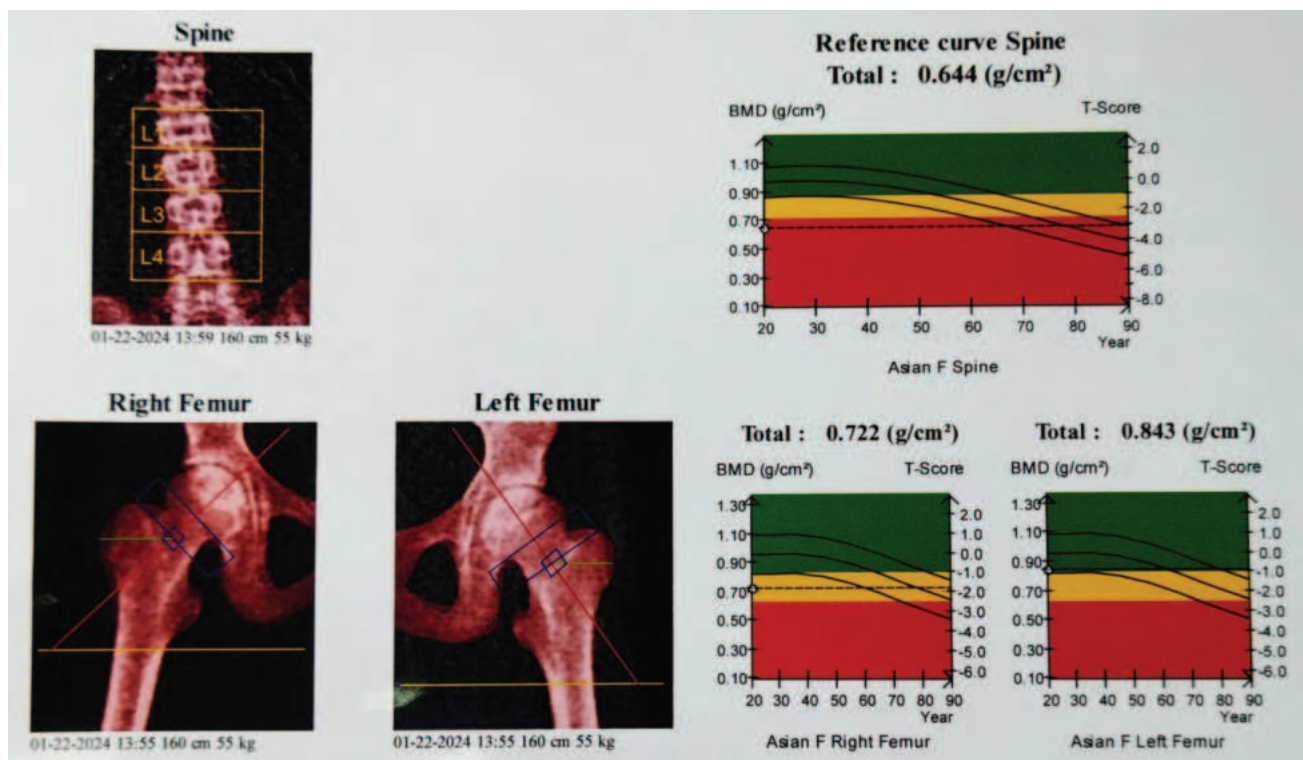


**Figure 1:** X-rays of dorso-lumbar spine in lateral (right) and antero-posterior (left) view showing decreased bone density, reduced height of D12 and L1 vertebral bodies (arrow) suggesting partial collapse along with straightening of curvature.



**Table 1: Bone mineral densitometry (BMD) by dual energy x-ray absorptiometry (DXA) results**

ROI	BMD (gm/cm <sup>2</sup> )	BMC (g)	Area (cm <sup>2</sup> )	T-score	Z-score
Spine: L <sub>1</sub> –L <sub>4</sub>	0.644	32.57	50.56	-3.1	-3.1
Right femur	0.722	22.07	30.55	-1.7	-1.7
Left femur	0.843	25.21	29.89	-0.8	-0.8



**Figure 2: DXA scan images with appropriate reference curves for age, sex, height and race.**

**DISCUSSION**

Glucocorticoids (GC) are the mainstay in the management of numerous systemic childhood illnesses. However, they are one of the most potent osteotoxic drugs that are routinely prescribed despite major advances in the management of those diseases. Glucocorticoids have diverse direct, and indirect, effects on the growth plate and developing skeleton. Osteoporosis in younger adults (YAs: premenopausal women and men aged <50 years) is less common but does occur in the setting of chronic disease, medications that affect bone metabolism, and other risk factors (1). Although rare, idiopathic osteoporosis (IOP) with no identifiable secondary cause is also associated with abnormal bone microarchitecture (2).

Optimal management of osteoporosis in younger adults is beset by many hurdles. Firstly, the pathophysiology of fracture in this age group is poorly understood. Secondly, the BMD criteria for

diagnosis of osteoporosis in this demographic are debated. In addition, optimal investigations for the diagnosis and monitoring of osteoporosis in adolescents are unclear. Finally, best practice management of osteoporosis or low bone density in young adults is poorly understood due to scarcity of focused research (3).

Through a variety of processes, chronic illness during childhood and early adulthood can impede the accumulation of peak bone mass. Bone loss is facilitated by a number of disease-specific factors, including low nutrition, weight loss, hypogonadism, increased exposure to inflammatory cytokines, and others. Glucocorticoid-induced osteoporosis (GIO) can occur in the context of excess glucocorticoids due to Cushing’s syndrome and in those prescribed long-term, moderate-dose to high-dose glucocorticoids (equivalent to ≥5 mg prednisolone for ≥3 months). Glucocorticoids inhibit osteoblast maturation

and osteoclast apoptosis, which results in increased bone resorption and decreased bone formation (4, 5).

For young adults (YAs) with underlying secondary causes, the ISCD (International Society for Clinical Densitometry) and IOF (International Osteoporosis Foundation) recommend diagnosing low BMD or osteoporosis based on Z-scores or T-scores, respectively (6, 7). Some have advised avoiding making an osteoporosis diagnosis if there are no fragility fractures (8). The latter, however, presents unique difficulties since it places more emphasis on treating fractures after they occur than on preventing them in the first place. To further complicate matters, there are few studies that report the amount of fracture risk in isolated low BMD as indicated by a Z-score  $\leq -2$ . It is well established that postmenopausal women of different ethnic backgrounds have different absolute fracture risks at any given BMD; it is less certain, though, if young adults are also affected by this difference (9). The combined effects of glucocorticoids on bone are not only to reduce bone mineral density (BMD) (10), but to alter bone microarchitecture, with a predilection for the trabecular-rich spine (4, 11).

Current management of osteoporosis in young adults relies heavily on studies that include postmenopausal women and older men. In an effort to find a treatment that works for GIO, numerous interventional studies have been conducted; however, very few of these studies have focused solely on the effects of these drugs on a cohort of younger adults. A systematic review and network meta-analysis of 27 randomized controlled trials (RCTs) illustrated that teriparatide, risedronate, and etidronate were effective in preventing vertebral fracture in patients with GIO, compared with calcium and vitamin D. Teriparatide, zoledronic acid, risedronate, alendronate, and etidronate improved spinal BMD in GIO compared with calcium and vitamin D, whereas calcitonin did not; alendronate and raloxifene improved femoral neck BMD (12).

It is evident that further research into the incidence, risk stratification, and management of osteoporosis in the young adult population is needed. The significance of isolated low BMD in this cohort is as yet unclear. Undeniably, there is abnormal bone microarchitecture in these individuals based on available data, but their long-term fracture risk and thus, an intervention threshold is yet to be established. Targeted tools for fracture risk calculation and guidance on the optimal methods of diagnosing and monitoring osteoporosis in young

adults are needed. Fracture risk assessment tools should ideally take into consideration the presence of different chronic diseases, sex, and ethnicity.

There is dearth of research on the safety and efficacy of therapeutic agents in this cohort. Additionally, it is necessary to clarify the advantages and disadvantages of the widely accepted practice of preferring anti-resorptives over anabolic therapy. The creation of guidelines that will help young adult patients and their healthcare providers will be aided by thorough study into the aforementioned areas of clinical need.

## CONCLUSION

Osteoporosis in young adults is uncommon. Nonetheless, a growing body of research shows that a subgroup of young men and women has abnormal bone microarchitecture and/or low BMD with or without fracture. The diagnosis, monitoring, and management of osteoporosis in this population deserve stronger research efforts.

## REFERENCES

1. Wang MT, Yao SH, Wong P, Trinh A, Ebeling PR, Tran T, Milat F, Mutalima N. Hip fractures in young adults: a retrospective cross-sectional study of characteristics, injury mechanism, risk factors, complications and follow-up. *Archives of osteoporosis*. 2017 Dec;12:1-6.
2. Cohen A, Dempster DW, Recker RR, Stein EM, Lappe JM, Zhou H, Wirth AJ, Van Lenthe GH, Kohler T, Zwahlen A, Müller R. Abnormal bone microarchitecture and evidence of osteoblast dysfunction in premenopausal women with idiopathic osteoporosis. *The Journal of Clinical Endocrinology & Metabolism*. 2011 Oct 1;96(10):3095-105.
3. Herath M, Cohen A, Ebeling PR, Milat F. Dilemmas in the management of osteoporosis in younger adults. *JBMR plus*. 2022 Jan;6(1):e10594.
4. Jacobsson M, Raalte DH, Heijboer AC, Heijer M, Jongh RT. Short term glucocorticoid treatment reduces circulating Sclerostin concentrations in healthy young men: a randomized, placebo controlled, double blind study. *Journal of Bone and Mineral Research Plus*. 2020 Aug 1;4(8):e10341.
5. Henneicke H, Gasparini SJ, Brennan-Speranza TC, Zhou H, Seibel MJ. Glucocorticoids and bone: local effects and systemic implications. *Trends in Endocrinology & Metabolism*. 2014 Apr 1;25(4):197-211.
6. Shuhart CR, Yeap SS, Anderson PA, Jankowski LG, Lewiecki EM, Morse LR, Rosen HN, Weber DR, Zemel BS, Shepherd JA. Executive summary of the 2019 ISCD position development conference on monitoring treatment, DXA cross-calibration and least significant change, spinal cord injury, peri-prosthetic and orthopedic bone health, transgender medicine, and pediatrics. *Journal of Clinical Densitometry*. 2019 Oct 1;22(4):453-71.

7. Ferrari S, Bianchi ML, Eisman JA, Foldes AJ, Adami S, Wahl DA, Stepan JJ, De Vernejoul MC, Kaufman JM, IOF Committee of Scientific Advisors Working Group on Osteoporosis Pathophysiology. Osteoporosis in young adults: pathophysiology, diagnosis, and management. *Osteoporosis International*. 2012 Dec;23:2735-48.
8. Aris RM, Merkel PA, Bachrach LK, Borowitz DS, Boyle MP, Elkin SL, Guise TA, Hardin DS, Haworth CS, Holick MF, Joseph PM. Guide to bone health and disease in cystic fibrosis. *The Journal of Clinical Endocrinology & Metabolism*. 2005 Mar 1;90(3):1888-96.
9. Barrett-Connor E, Siris ES, Wehren LE, Miller PD, Abbott TA, Berger ML, Santora AC, Sherwood LM. Osteoporosis and fracture risk in women of different ethnic groups. *Journal of bone and mineral research*. 2005 Feb;20(2):185-94.
10. Santiago RA, Silva CA, Caparbo VF, Sallum AM, Pereira RM. Bone mineral apparent density in juvenile dermatomyositis: the role of lean body mass and glucocorticoid use. *Scandinavian journal of rheumatology*. 2008 Jan 1;37(1):40-7.
11. Belaya ZE, Hans D, Rozhinskaya LY, Dragunova NV, Sasonova NI, Solodovnikov AG, Tsoriev TT, Dzeranova LK, Melnichenko GA, Dedov II. The risk factors for fractures and trabecular bone-score value in patients with endogenous Cushing's syndrome. *Archives of osteoporosis*. 2015 Dec;10:1-9.
12. Amiche MA, Albaum JM, Tadrous M, Pechlivanoglou P, Lévesque LE, Adachi JD, Cadarette SM. Efficacy of osteoporosis pharmacotherapies in preventing fracture among oral glucocorticoid users: a network meta-analysis. *Osteoporosis International*. 2016 Jun;27:1989-98.