

Pattern of ^{99m}Tc -DTPA Renogram Findings in Pediatric patients attending INMAS, Rajshahi

¹Shibli Nishad Alam, ²Mostofa Shamim Ahsan, ³Nasrin Begum, ³Parvez Ahmed, ⁴Tasnim Ahmed, ⁵Md. Shariful Islam Chowdhury

¹ Medical Officer, ²Director & Chief Medical Officer, ³Principal Medical Officer, ⁴Senior Medical Officer, ⁵Principal Scientific Officer, Institute of Nuclear Medicine & Allied Sciences (INMAS), Rajshahi

Correspondence Address : Dr. Shibli Nishad Alam, Medical Officer, INMAS, Rajshahi, E-mail: shiblinishad@gmail.com

ABSTRACT

Introduction: Nuclear medicine imaging techniques, specifically the DTPA (diethylenetriamine pentaacetate) renogram, play a vital role in diagnosis and management in pediatric nephrology. Due to the availability of prenatal ultrasonography, prenatal diagnosis of fetal renal disorders is increasing in frequency. Consequently, the number of patients undergoing DTPA renograms is increasing gradually.

Objectives: This study was done to evaluate the role of DTPA renograms in the assessment of renal function in the pediatric age group and investigate the pattern of renogram findings in the under-5-year-old pediatric age group.

Patients and Methods: This retrospective study was done on 138 patients below 5 years age consisting of 102 boys and 36 girls. They were referred to Institute of Nuclear Medicine & Allied Sciences (INMAS), Rajshahi for DTPA renogram from January 2023 to June 2023. To ensure proper image acquisition all the patients were administered ketamine with prior preparations. Average administered dose of ^{99m}Tc -pertechnetate-labeled DTPA in boys was 2.51 mCi, and in girls it was 2.36 mCi. Images were acquired with a Siemens (Symbia Intevo Bold) dual-headed gamma camera. The total time required for image acquisition was about 30 minutes for each patient. After image acquisition, ROI was drawn, and the calculation of GFR, split functions, and other parameters were calculated.

Result: The study showed unilateral hydronephrosis in 59.42% of patients, bilateral hydronephrosis in 33.33% of patients, and no hydronephrosis in 7.24% of patients. 22.46% of patients were diagnosed prenatally by ultrasound. Total GFR was found to be reduced in 13.04% of patients, and split function was found to be reduced in 40.58% of patients. However, the majority (68.12%) of the patients showed no feature of nephropathy, 27.54% were diagnosed with unilateral nephropathy, and 4.35% had bilateral nephropathy. A minority (4.35%) of the patients had unilateral renal agenesis. Renogram findings were partially incompatible with ultrasound findings in 28 (20.29%) patients.

Conclusion: DTPA renogram can play a very important role in assessing renal function in patients with renal pathologies for diagnosis and management. Despite several drawbacks, including radiation and a longer time for image acquisition, its use is increasing every day because of its affordability and feasibility.

Keywords: ^{99m}Tc -DTPA renogram, Hydronephrosis, Split renal function, Glomerular Filtration Rate (GFR), Nephropathy.

Bangladesh J. Nucl. Med. Vol. 26 No. 2 July 2023

DOI: <https://doi.org/10.3329/bjnm.v26i2.71491>

INTRODUCTION

The use of Nuclear Medicine (NM) imaging techniques, also known as functional imaging, radioisotope imaging, or molecular imaging, has been well-established in pediatric clinical practice and has been applied to children for a long time (1). Pediatric nephro-urology, especially in the context of urinary tract infections (UTI) and antenatally diagnosed hydronephrosis, heavily relies on functional studies for patients' management. Nuclear medicine imaging, especially DTPA (Diethylenetriamine pentaacetate) renogram can provide a functional evaluation of pediatric renal pathology. It is essential in the diagnostic work up of many conditions, and, in some instances, in the evaluation of response to treatment. It can very accurately provide information regarding renal parenchymal function, estimate the contribution of each kidney to the total glomerular filtration rate (GFR), drainage and urinary stasis, obstruction and where it is (in the renal pelvis or ureter, or at both sites). The calculation of the split renal parenchymal function has been validated (2) and comprehensive guidelines on the acquisition, processing and interpretation of these studies have been published (3-6). Since the time that antenatal sonography became widespread, fetal urinary tract abnormalities have been detected in approximately 1 in 100 pregnancies (7,8). Therefore, the number of pediatric patients undergoing DTPA renogram is increasing gradually. This study was conducted to summarize the findings of pediatric patients under 5 years old undergoing DTPA renogram at INMAS, Rajshahi.

OBJECTIVES

The objective of this study was to evaluate the role of DTPA renogram in assessment of renal function in pediatric age group and explored the pattern of renogram findings in under 5 years pediatric age group.

PATIENTS AND METHODS

In this retrospective study the evaluation of renogram findings was assessed in 138 patients. All were within the age of 5 years old who were referred to INMAS Rajshahi from January 2023 to June 2023 for DTPA renogram. Among them 102 were boys and 36 were girls (Boys : Girls ratio was 2.8:1). Informed written consent was taken from guardians of all the patients. Intravenous ketamine was administered by a skilled anesthesiologist before the procedure for proper acquisition. All the patients were kept fasting for at least 12 hours before the procedure with

intravenous fluid supplementation for proper hydration according to their age and body weight. DTPA was labeled with ^{99m}Tc pertechnetate and was administered intravenously according to body weight. Average administered dose in boys was 2.51 mCi and in girls was 2.36 mCi. After administration of radiotracer image was acquired by SPECT-CT procedure with Siemens (Symbia Intevo Bold) Dual-head gamma camera. Images were acquired in two phases. In first phase 60 images were acquired with 3 second duration for each image. In the second phase 25-27 images were obtained with 1 minute for each image. Intravenous diuretic was administered according to body weight in cases where obstructive features were noted. After acquisition of image region of interest (ROI) was drawn manually. Following the completion of acquisition procedure, reversal of anesthesia was done.

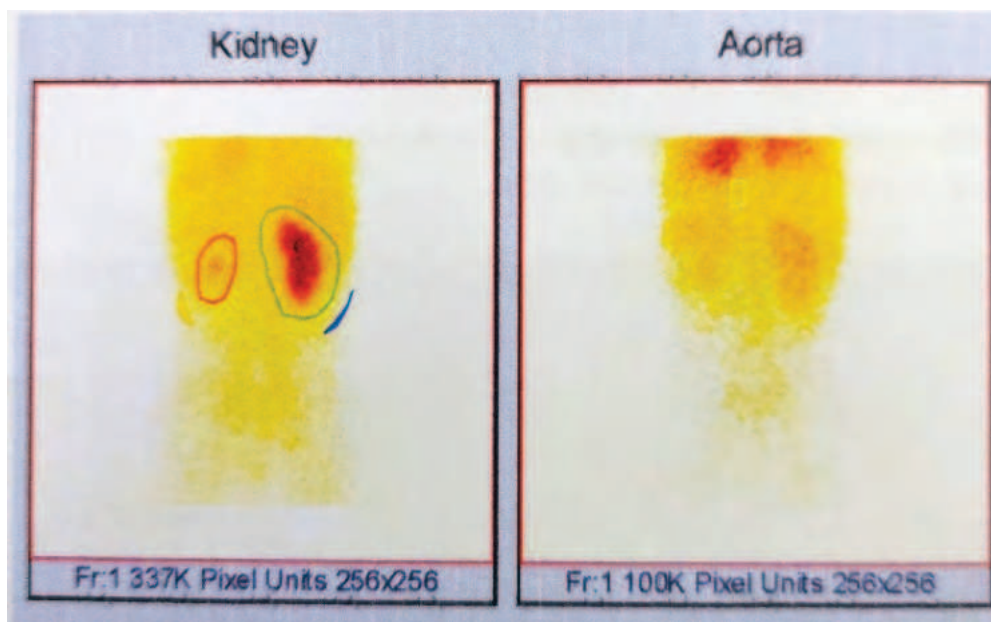


Figure 1: ^{99m}Tc-DTPA renogram image of a 5 years old boy with suspected left sided obstructive nephropathy. Region of interest (ROI) drawn in normally functioning right kidney and affected left kidney area.

RESULT

This retrospective study included a total of 138 patients and among them 102 (73.91%) were boys and 36 (26.09%) girls. Features of unilateral hydronephrosis was found in 44 (59.42%) and bilateral hydronephrosis in 50 (49.02%) boys. Total 30 (83.33%) of the girls had unilateral hydronephrosis and 4 (11.11%) of the had bilateral hydronephrosis. However, no features of hydronephrosis was seen in 8 (7.84%) of the boys and 2 (5.56%) of the girls (Table-1).

Table-1: Frequency of boys and girls in chosen population along with frequencies of each type of nephropathy.

Parameters	Boys	Girls
Frequency (%)	102 (73.91%)	36 (26.09%)
Unilateral Hydronephrosis	44 (43.14%)	30 (83.33%)
Bilateral Hydronephrosis	50 (49.02%)	4 (11.11%)
No Hydronephrosis	8 (7.84%)	2 (5.56%)

Interestingly, 31 (22.46%) patients were diagnosed prenatally. Among the patients with hydronephrosis 14 (10.15%) of them showed no excretory delay and 15 (10.86%) were found with only functional obstruction. 37 (20.29%) patients had previous history of renal surgery.

Total GFR in pediatric patients was considered normal if found ≥ 90 ml/min. It was found reduced in 18 (13.04%)

patients. Split function was considered normal if it was between 45-55%. 56 (40.58%) patients showed reduced unilateral renal split function with hydronephrosis in the corresponding kidney. No feature of nephropathy was seen in 94 (68.12%) patients. However, features of nephropathy in both kidneys were observed in 6 (4.35%) patients and in unilateral kidney of 38 (27.54%) patients as shown in Table-2.

Table-2: Frequencies of unilateral and bilateral nephropathy in total population

Nephropathy	Frequency (%)
Unilateral	38 (27.54%)
Bilateral	6 (4.35%)
None	94 (68.12%)

Only 6 (4.35%) patients had ectopic kidney and two patients were found to have right renal agenesis. Renogram findings were partially incompatible with ultrasound findings in 28 (20.29%) patients.

DISCUSSION

The split renal function expressed as a percent of total renal function (9), is important in the initial assessment and treatment of patients having renal diseases. For a very long time, DRF has been determined by radionuclide renal scintigraphies with various tracers (10). Different radiopharmaceuticals such as technetium-99m-diethylenetriaminepentaacetic acid (^{99m}Tc-DTPA), technetium-99m-mercaptoacetyl triglycine (^{99m}Tc-MAG3), Iodine-¹³¹I-orthoiodihippurate (¹³¹I-OIH), and more recently technetium-99m-ethylenedicysteine (^{99m}Tc-EC) are used to measure the relative renal functions (11).

The dynamic agent ^{99m}Tc-DTPA is readily filtered by the glomerular tubules but the renal tubules do not secrete or reabsorb it. This method is used to measure total and split/individual renal functions as well as GFR (12). It can also differentiate between true obstruction and functional obstruction (13).

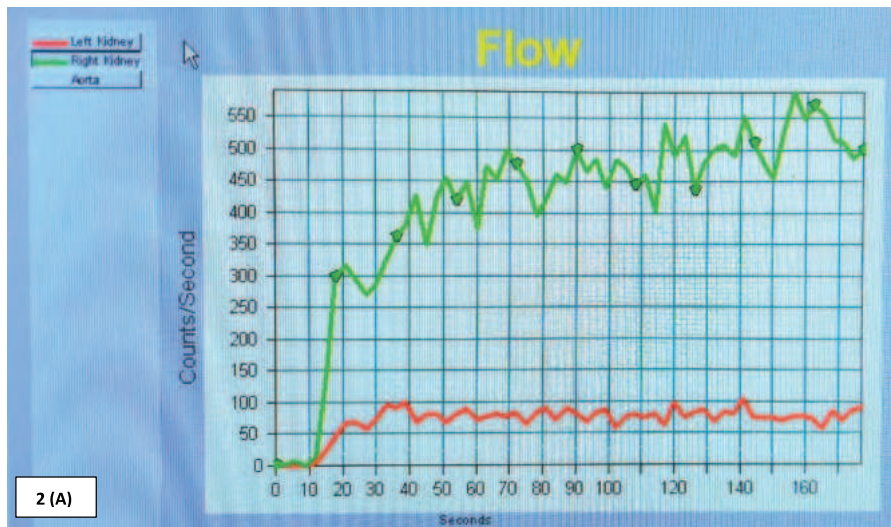


Figure 2: (A) Image of the time activity curve generated in ^{99m}Tc-DTPA renogram of a 5 years old boy showing low height distorted curve of left kidney, implying reduced tracer uptake with negligible excretion even after diuretic administration at 12 minutes of study. Curve of the right kidney is normal.

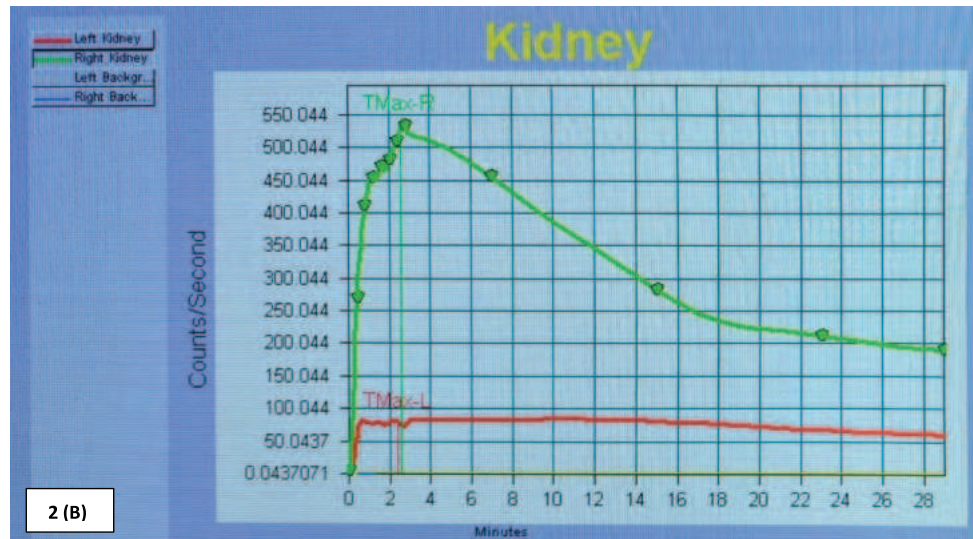


Figure 2: (B) Zoomed curve of arterial phase of the same patient showing normal renal perfusion in right but significantly reduced renal perfusion in left kidney.

While making urological decision, kidney function is an essential parameter. It has a variety of benefits. This method is easy, feasible and safe and can provide valuable information regarding individual function with high accuracy. (14) The study shows a large spectrum of parameters assessed by ^{99m}Tc -DTPA renogram. Thus, it plays a vital role in assessing the prognosis of disease and also the outcome following renal surgery.

CONCLUSION

^{99m}Tc -DTPA renogram is becoming progressively popular in present time for the evaluation of split renal function as well as nature of obstruction using diuretic challenge. It is an easily affordable and almost hazardless investigation for the assessment of renal function. Regardless of some disadvantages like radiation, necessity for anesthesia in pediatric patients prolonged time for image acquisition and few limitations implementation of renogram is increasing day by day with exciting new prospects.

CONFLICT OF INTEREST

The authors have no potential conflicts of interest.

REFERENCES

1. Biassoni, L. and Easty, M., 2017. Paediatric nuclear medicine imaging. *British Medical Bulletin*, 123(1), pp.127-148.
2. Conway, J.J. and Maizels, M., 1992. The "well tempered" diuretic renogram: a standard method to examine the asymptomatic neonate with hydronephrosis or hydroureteronephrosis. A report from combined meetings of The Society for Fetal Urology and members of The Pediatric Nuclear Medicine Council--The Society of Nuclear Medicine. *Journal of nuclear medicine: official publication, Society of Nuclear Medicine*, 33(11), pp.2047-2051.
3. Gordon, I., Colarinha, P., Fettich, J., Fischer, S., Frökier, J., Hahn, K., Kabasakal, L., Mitjavila, M., Olivier, P., Piepsz, A. and Porn, U., 2001. Guidelines for indirect radionuclide cystography. *European journal of nuclear medicine*, 28(3), pp.BP16-BP20.
4. Gordon, I., Piepsz, A. and Sixt, R., 2011. Guidelines for standard and diuretic renogram in children. *European journal of nuclear medicine and molecular imaging*, 38, pp.1175-1188.
5. Mandell, G.A., Egli, D.F., Gilday, D.L., Heyman, S., Leonard, J.C., Miller, J.H., Nadel, H.R. and Treves, S.T., 1997. Procedure guideline for renal cortical scintigraphy in children. *Journal of Nuclear Medicine*, 38(10), pp.1644-1646.
6. Piepsz, A., Colarinha, P., Gordon, I., Hahn, K., Olivier, P., Roca, I., Sixt, R. and van Velzen, J., 2001. Guidelines for ^{99m}Tc -DMSA scintigraphy in children. *European journal of nuclear medicine*, 28(3), pp.BP37-41.
7. DiSandro, M.J. and Kogan, B.A., 1998. Neonatal management: role for early intervention. *Urologic Clinics of North America*, 25(2), pp.187-197.
8. Elder, J.S., 1997. Antenatal hydronephrosis: fetal and neonatal management. *Pediatric Clinics of North America*, 44(5), pp.1299-1321.
9. Dostbil, Z., Pembegül, N., Küçüköner, M., Bozkurt, Y., Sancaktutar, A.A., Yildiz, İ. and Tekba, G., 2011. Comparison of split renal function measured by ^{99m}Tc -DTPA, ^{99m}Tc -MAG3 and ^{99m}Tc -DMSA renal scintigraphies in paediatric age groups. *Clin Rev Opin*, 3(2), pp.20-25.
10. Hackstein, N., Buch, T., Rau, W.S., Weimer, R. and Klett, R., 2007. Split renal function measured by triphasic helical CT. *European journal of radiology*, 61(2), pp.303-309.
11. Moran, J.K., 1999, April. Technetium- ^{99m}EC and other potential new agents in renal nuclear medicine. In *Seminars in nuclear medicine* (Vol. 29, No. 2, pp. 91-101). WB Saunders.
12. Itoh, K., 2001. ^{99m}Tc -MAG3: review of pharmacokinetics, clinical application to renal diseases and quantification of renal function. *Annals of nuclear medicine*, 15, pp.179-190.
13. Momin, M.A., Abdullah, M.N.A. and Reza, M.S., 2018. Comparison of relative renal functions calculated with ^{99m}Tc -DTPA and ^{99m}Tc -DMSA for kidney patients of wide age ranges. *Physica Medica*, 45, pp.99-105.
14. Anjum, S., Ahmad, A., Anwar, F., Jabeen, Z., Bacha, R. and Ayaz, M., 2018. Effectiveness of nuclear scan ^{99m}Tc -DTPA in the evaluation of renal function. *Asian Journal of Allied Health Sciences (AJAHS)*, pp.50-54.