

# Assessment of Perfusion Abnormalities in a Case of Autism Spectrum Disorders Using $^{99m}\text{Tc}$ ECD Brain SPECT: A Landmark case in Bangladesh

<sup>1</sup>Sheikh Mohammad Adnan, <sup>2</sup>Jannat Ara Shefa, <sup>3</sup>Mohammed Badrul Alam, <sup>4</sup>Nasreen Sultana

<sup>1</sup>MD Resident (Phase B), National Institute of Nuclear Medicine & Allied sciences (NINMAS)

<sup>2</sup>Institute of Pediatric Neurodisorder & Autism (IPNA)

<sup>3</sup>Department of Anaesthesia, Analgesia and Intensive Care Medicine, Bangabandhu Sheikh Mujib Medical University (BSMMU)

<sup>4</sup>Professor & Head, Scintigraphy Division, NINMAS

**Correspondence Address:** Sheikh Mohammad Adnan, MD Resident, NINMAS, Block-D, BSMMU campus, Dhaka-1000,  
E-mail: sheikhmdadnan8@gmail.com

## ABSTRACT

The prevalence of Autism Spectrum Disorders (ASD) has witnessed a rapid increase globally, necessitating effective diagnostic tools for comprehensive assessment. This case report presents a three-year-old male child clinically identified with ASD, undergoing a brain perfusion scan using single-photon emission computed tomography (SPECT). Hypoperfusion, characterized by multiple focal areas of decreased radiotracer concentration, was observed in frontal lobes, left temporal lobe, right parietal, right precuneus, and both hypothalami. The application of the e-ZIS system indicated a severity of rCBF decrease in specific voxels. This case underscores the utility of radionuclide brain SPECT imaging in unveiling abnormal rCBF patterns in ASD patients. Establishing a correlation between these abnormalities and symptom profiles could enhance treatment strategies, incorporating innovative interventions and specific medications tailored to the observed abnormalities.

**Keywords:** Autism, cerebral hypoperfusion, regional cerebral blood flow, SPECT imaging

Bangladesh J. Nucl. Med. Vol. 27 No. 1 January 2024

**DOI:** <https://doi.org/10.3329/bjnm.v27i1.71509>

## INTRODUCTION

In 1987, the American Psychiatric Association classified autism as an early-onset and severe developmental condition characterized by impairments in reciprocal social interaction, deficiencies in verbal and nonverbal language, and a restricted repertoire of activities and interests (1). The specific neurological pathways underlying this condition remain elusive. Current evidence suggests that autism is a neurodevelopmental disorder with a genetic influence. Numerous studies propose that autism arises from a spectrum of neurological abnormalities

affecting the brainstem, frontal, temporal, and parietal cortices, as well as the limbic system, and potentially other brain regions (2-4). Global epidemiological studies reveal a significant rise in ASD prevalence, estimated at 1 in 150 children worldwide (5). A systematic review of research found disparities in the prevalence of autism across South Asia, ranging from 0.09% to 1.07% (6). Single Photon Emission Computed Tomography (SPECT) of brain using  $^{99m}\text{Tc}$ -ECD emerges as a valuable tool, capable of identifying impaired compensatory blood flow increase during tasks in ASD patients (7, 8). The National Institute of Nuclear Medicine and Allied Sciences (NINMAS), equipped with specialized technology and expertise, stands to enhance government initiatives for advancing autism diagnosis. The integration of advanced neuroimaging techniques can contribute significantly to understanding and addressing the complexities of ASD. The primary objective of our case presentation is to identify the exact hypo perfused brain areas related to autism behavior. If we discover a strong link, this knowledge can assist physicians give better therapies. These could include advanced treatments like hyperbaric oxygen therapy, drugs like pregnenolone and cilostazol, brain stimulation therapies, and personalized rehabilitation.

## CASE REPORT

A 3-year-old boy diagnosed with ASD according to Diagnostic and Statistical Manual of Mental Disorders

fifth edition (DSM-V) criteria, was referred from Institute of Pediatric Neurodisorder & Autism (IPNA) to NINMAS for a brain SPECT study. A proper briefing was conducted with the guardian, and the consent form was signed. Prior to the brain perfusion scan, the patient underwent a comprehensive pre-anesthesia checkup,

including a chest X-ray, blood pressure, hematological profile, serum creatinine, and oxygen saturation. After the anesthesiologist declared him fit for anesthesia, a brain perfusion scan with <sup>99m</sup>Tc-ECD was performed in accordance with established protocol (figure 1, 2).

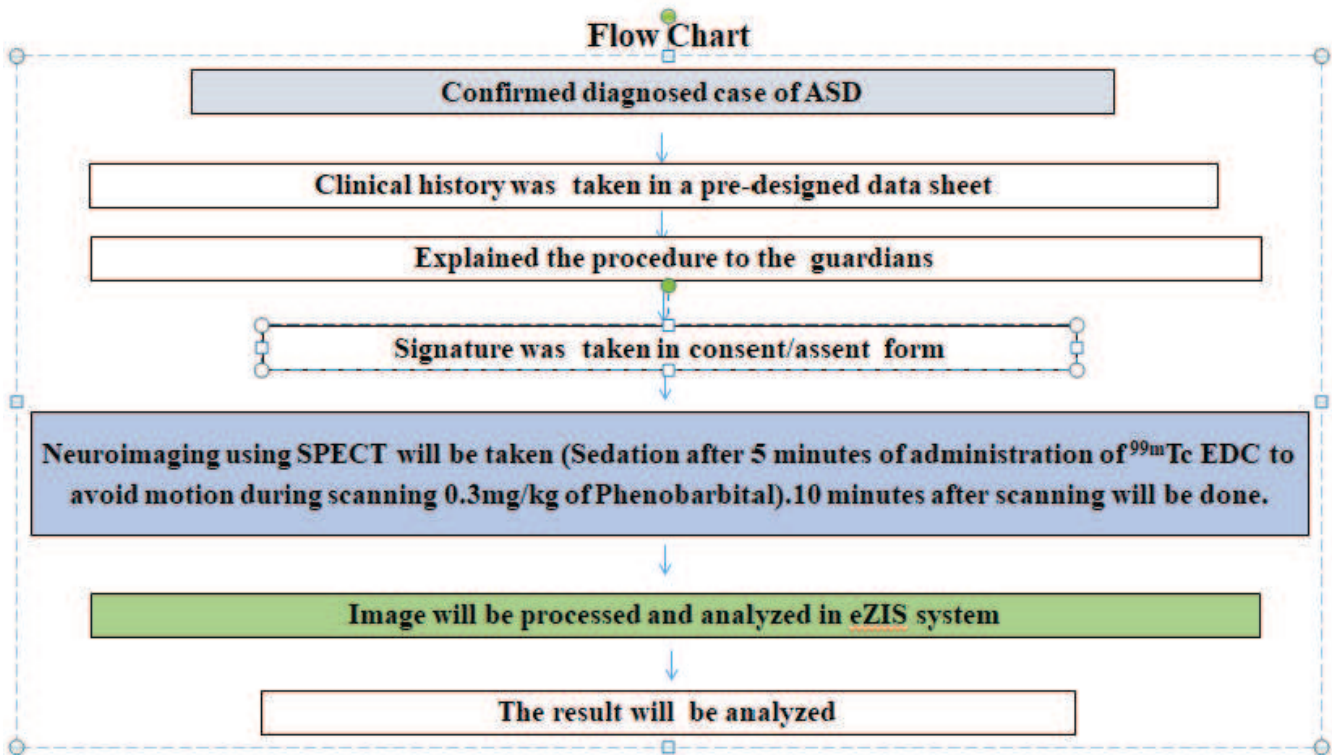


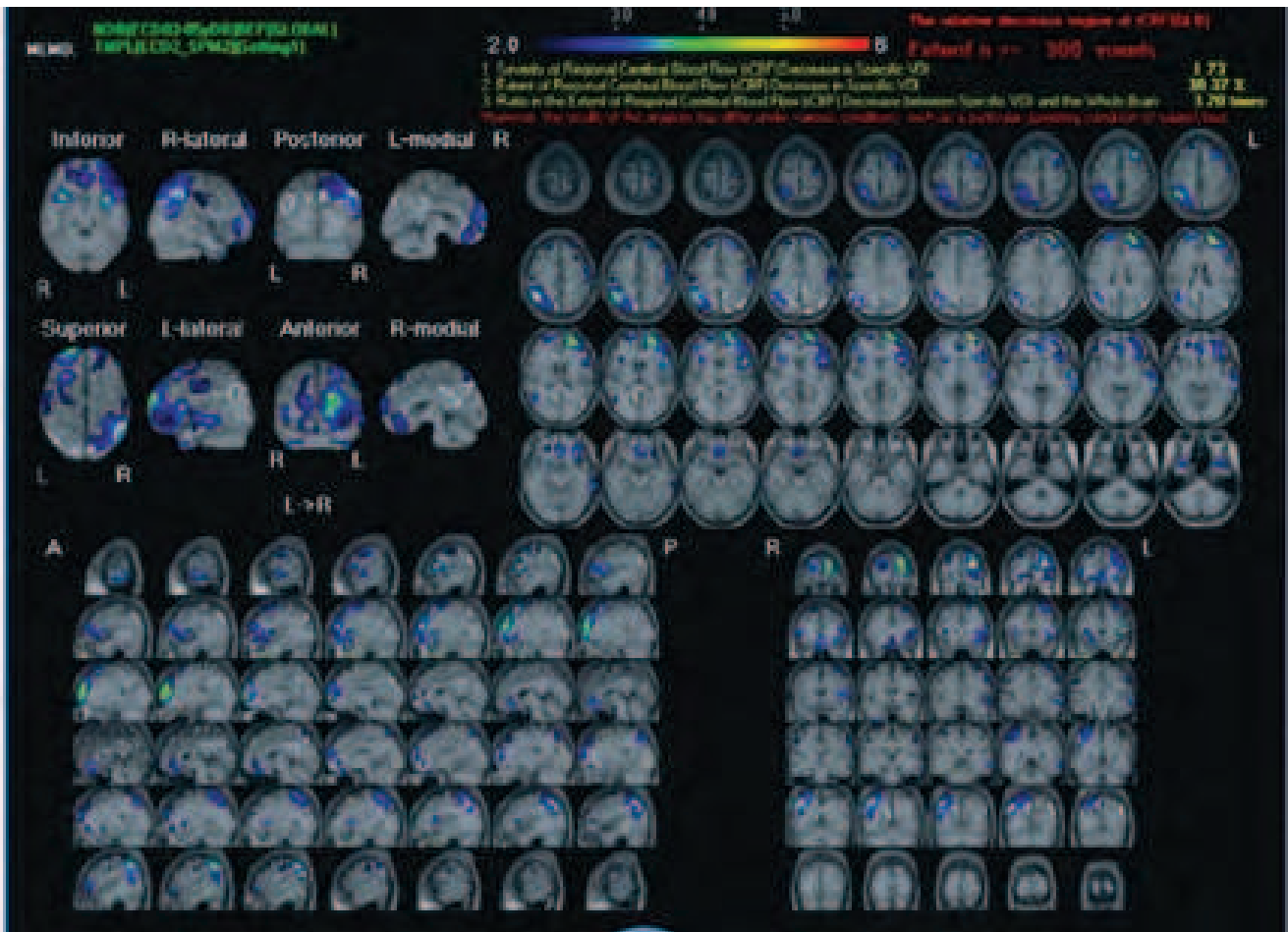
Figure 1: <sup>99m</sup>Tc-ECD Brain SPECT protocol flow chart for the diagnosis of autism spectrum disorder

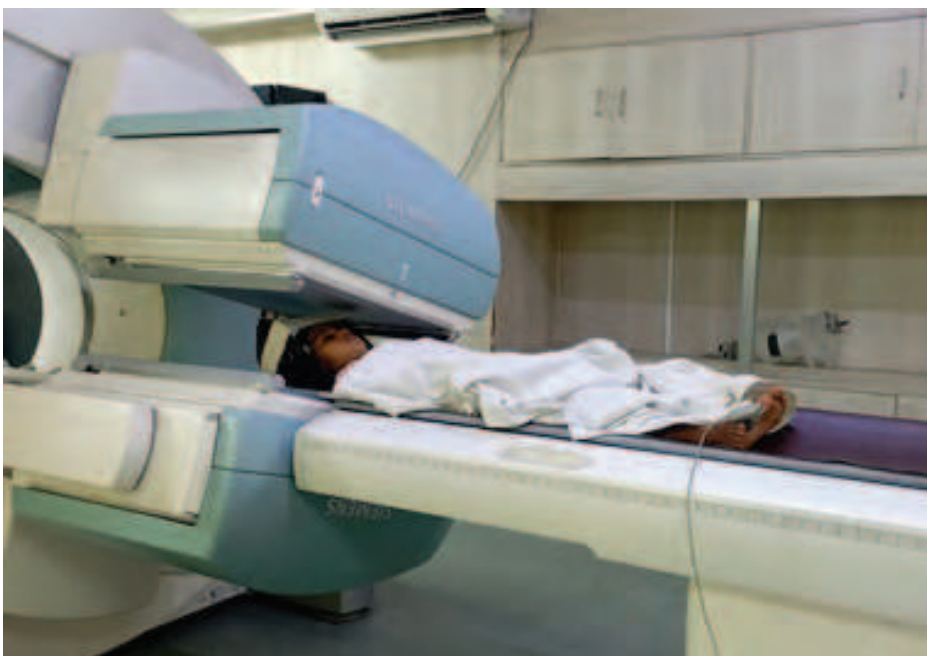

Figure 2: A 3-year-old boy undergoing <sup>99m</sup>Tc-ECD Brain SPECT with dual head gamma camera.

The collected DICOM data were subsequently examined using the easy Z score imaging system (eZIS) program. The analysis revealed multiple focal areas of reduced

radiotracer concentration in regions including both frontal lobes, the left temporal lobe, the right parietal region and, the right precuneus (Figure 3).



**Figure 3:** <sup>99m</sup>Tc-ECD Brain SPECT image analyzed with eZIS program showing reduced radiotracer concentration in regions including both frontal lobes, the left temporal lobe, the right parietal region and the right precuneus.

### DISCUSSION

Cerebral hypoperfusion, or inadequate blood flow in the brain, affects several parts of the brain in patients with ASD. This is an early and severe developmental disease marked by deficiencies in verbal and nonverbal languages, social skills, cognitive functioning, and abnormal behavior repetition (DSM-V).

Individuals with ASD have hypoperfusion in their brains when compared to normal healthy control brains using Positron Emission Tomography (PET) or SPECT (3, 4). Prefrontal, frontal, temporal, occipital, parietal cortices, thalami, basal ganglia, cingulate cortex, caudate nucleus, limbic system, including the hippocampus, putamen,

substantia nigra, cerebellum, and associative cortices are usually affected. Furthermore, links between symptom scores and hypoperfusion in the brains of patients with ASD have been observed, implying that the more severe the autism symptom pathology, the greater the cerebral hypoperfusion or vascular illness in the brain (2, 4). In this case report of a 3-year-old boy diagnosed with ASD, eZIS analysis of brain SPECT revealed reduced radiotracer concentration in frontal, temporal, parietal, and precuneus regions.

Berna et al. (3) observed significant hypoperfusion in the right posterior parietal cortex in three autistic children, bilateral frontal cortex in two, bilateral parietal cortex in

one, left parietal and temporal cortex in one, and right parietal and temporal cortex in one among ten ASD children. They also found regional cerebral perfusion alterations in the frontal, temporal, and parietal cortices, as well as the caudate nucleus, in autistic children and their first-degree relatives. Furthermore, associations between symptom scores and hypoperfusion in the brains of individuals diagnosed with an ASD were discovered, showing that the stronger the autism symptom pathology, the more severe the cerebral hypoperfusion (5, 6, 7).

The results of this case study indicate that  $^{99m}\text{Tc}$ -ECD brain SPECT is a useful tool to locate perfusion abnormalities, and that a decrease in rCBF in ASD is a global event that corresponds to complex clinical symptoms. Application of SPECT with eZIS in ASD cases is relatively novel, providing valuable insights into specific brain areas associated with autism behavior. Though this is a single case experience, our findings of brain SPECT with eZIS are quite similar with other literature findings (8-11). The findings contribute to understanding of ASD complexities and support the use of personalized therapies, making it valuable for clinicians and researchers in the field.

## CONCLUSION

The incorporation of sophisticated neuroimaging at NINMAS strengthens government programs and contributes to the global effort to advance autism diagnosis. This case report study found that  $^{99m}\text{Tc}$ -ECD brain SPECT can detect perfusion abnormality and decreased rCBF in ASD is a global event associated with complex clinical symptoms. It is a first-of-its-kind study in our country, allowing us to evaluate patients' long-term responses to treatment. Furthermore, this work has the potential to spur future research by encouraging collaboration among experts in neurodevelopment, nuclear imaging, clinical neurology, internal medicine, and neuropsychiatry.

## ACKNOWLEDGEMENT

We acknowledge the Ministry of Science and Technology, Bangladesh, for financing the project

“Radionuclide Neuroimaging of Autism Spectral Disorders (ASD) - a Grand Opportunity to Improve Diagnosis and Management in Bangladesh utilizing Affordable Advanced Technology”.

## CONFLICT OF INTEREST

The authors have no conflict of interest.

## REFERENCES

- Hodges H, Fealko C, Soares N. Autism spectrum disorder: definition, epidemiology, causes, and clinical evaluation. *Translational pediatrics*. 2020 Feb;9(Suppl 1):S55.
- Gupta SK, Ratnam BV. Cerebral perfusion abnormalities in children with autism and mental retardation: a segmental quantitative SPECT study. *Indian pediatrics*. 2009 Feb 1;46(2).
- Degirmenci B, Miral S, Kaya GC, İyilikçi L, Arslan G, Baykara A, Evren İ, Durak H. Technetium-99m HMPAO brain SPECT in autistic children and their families. *Psychiatry Research: Neuroimaging*. 2008 Apr 15;162(3):236-43.
- Turner M, Barnby G, Bailey A. Genetic clues to the biological basis of autism. *Molecular Medicine Today*. 2000 Jun 1;6(6):238-44.
- Akhter S, Hussain AE, Shefa J, Kundu GK, Rahman F, Biswas A. Prevalence of Autism Spectrum Disorder (ASD) among the children aged 18-36 months in a rural community of Bangladesh: A cross sectional study. *F1000Research*. 2018;7.
- Hossain MD, Ahmed HU, Jalal Uddin MM, Chowdhury WA, Iqbal MS, Kabir RI, Chowdhury IA, Aftab A, Datta PG, Rabbani G, Hossain SW. Autism Spectrum disorders (ASD) in South Asia: a systematic review. *BMC psychiatry*. 2017 Dec;17:1-7.
- Wilcox J, Tsuang MT, Ledger E, Algeo J, Schnurr T. Brain perfusion in autism varies with age. *Neuropsychobiology*. 2002 Aug 23;46(1):13-6.
- Björklund G, Kern J, Urbina M, Saad K, El-Houfey A, Geier D, Chirumbolo S, Geier M, Mehta J, Aaseth J. Cerebral hypoperfusion in autism spectrum disorder. *Acta neurobiologicae experimentalis*. 2018;78(1):21-9.
- Öner P, Öner Ö, Aysev A, Küçük Ö, Ibiş E. Comparison of Cerebral Blood Flow in Children with Obsessive Compulsive Disorder and Attention Deficit Hyperactivity Disorder. *Turkish Journal of Psychiatry*. 2008 Mar 1;19(1).
- Ito H, Mori K, Hashimoto T, Miyazaki M, Hori A, Kagami S, Kuroda Y. Findings of brain  $^{99m}\text{Tc}$ -ECD SPECT in high-functioning autism-3-dimensional stereotactic ROI template analysis of brain SPECT. *The Journal of Medical Investigation*. 2005;52(1, 2):49-56.
- Kaya M, Karasalihoğlu S, Üstün F, Gültekin A, Çermik TF, Fazlıoğlu Y, Türe M, Yiğitbaşı ÖN, Berkarda Ş. The relationship between  $^{99m}\text{Tc}$ -HMPAO brain SPECT and the scores of real life rating scale in autistic children. *Brain and Development*. 2002 Mar 1;24(2):77-81.