

Bone Scintigraphic Pattern and Correlation with Serum Prostate Specific Antigen Levels in Prostate Cancer Patients at NINMAS

¹ Farzana Rahman Ananna, ² Urnas Islam, ² Rahima Perveen, ³ Sharmin Reza, ⁴ Sheikh Md. Adnan
² Shamsun Nahar Bailey, ⁵ Nasreen Sultana

¹ Medical officer, Resident (MD phase B), National institute of Nuclear Medicine & Allied Sciences (NINMAS)

² Assistant professor & SMO, NINMAS

³ Associate professor & PMO, NINMAS

⁴ Resident (MD, phase-B), NINMAS

⁵ Professor & Head, Scintigraphy division, NINMAS

Correspondence Address: Farzana Rahman Ananna, Medical officer, Resident (MD phase B), NINMAS, Block-D, BSMMU Campus. Dhaka.
E-mail: ananna2401323@gmail.com

ABSTRACT

Background: Prostate carcinoma is the most common cancer in aging males and the second leading cause of cancer mortality, with African American men having higher incidence and mortality rates. Diagnosis involves digital rectal examination, serum prostate-specific antigen (PSA) testing, PSA testing, and transrectal ultrasound-guided biopsy (TRUS). Bone scintigraphy emerges as a sensitive modality for detecting skeletal metastases, which is crucial for the staging and management of prostate carcinoma.

Objective: To find the correlation between serum PSA level and bone scan findings and to see the variation of bone scan findings in confirmed carcinoma prostate patients of different age groups.

Patients and Methods: This was a retrospective analytical study conducted in the department of scintigraphy at the National Institute of Nuclear Medicine and Allied Sciences (NINMAS), during the period of February 2023 to August 2023 (6 months). A total of 64 male patients with prostatic adenocarcinoma confirmed by TRUS biopsy and histopathology were enrolled in this study as the study population. A bone scan was done according to the standard protocol with a Siemens dual-head gamma camera after an intravenous injection of an average of 20 mCi of ^{99m}Tc-MDP. Both anterior and posterior static planar images of the entire axial and appendicular skeleton with multiple spot views were taken. A SPECT image is also taken when needed. The images were interpreted and analyzed by nuclear medicine (NM) physicians at this institute. All data were processed, analyzed, and disseminated using MS Excel and SPSS version 23.0.

Results: The study encompassed a cohort of 64 participants, with a mean age of 69.60±8.64 years. The predominant complaint was low back pain, constituting 84% of the study population (n=54). Regarding serum prostate-specific antigen (S. PSA) levels, 14 patients showed more than 4 ng/ml, and the mean S. PSA was 105.97 ng/ml. Notably, 34% of patients presented with S.PSA levels exceeding 100 ng/ml. Approximately 44% of patients had undergone transurethral resection of the prostate (TURP). In bone scan findings among the study population, 27% (n = 17) presented

with extensive skeletal metastasis, 23% (n = 15) had a negative outcome for osteoblastic skeletal lesions, 17% (n = 11) had suspicious solitary osteoblastic lesions, 19% (n = 12) exhibited axial osteoblastic lesions, and 14% (n = 9) showed both axial and appendicular osteoblastic lesions. Notably, no patients displayed appendicular bone lesions in the scan.

Conclusion: Prostate carcinoma becomes more aggressive with age and a high serum PSA level, and it metastasizes rapidly and extensively. Although serum PSA levels may be undetectable or low-normal, a bone scan is recommended to rule out recurrence and metastases.

Keywords: prostate carcinoma, bone scan, carcinoma, S. PSA

Bangladesh J. Nucl. Med. Vol. 27 No. 1 January 2024

DOI: <https://doi.org/10.3329/bjnm.v27i1.71533>

INTRODUCTION

Prostate carcinoma begins when cells in the prostate gland start to grow out of control. It is the most common cancer in males of increasing age and the second leading cause of cancer mortality among men throughout the world. The American Cancer Society's estimates for prostate cancer in the United States for 2023 are: About 288,300 new cases of prostate carcinoma occur, and there are 34,700 deaths from prostate carcinoma (1). The average age of men when they are first diagnosed is about 67 years (2). Prostate carcinoma risk is also higher in African American men and in Caribbean men of African ancestry than in men of other races (3). Asian men have the lowest incidence rate. There is evidence that genetic, environmental, and social factors, often in combination, contribute to the observed differences in various populations. However, due to the increasing awareness of

the disease entity, the advent of prostate-specific antigen (PSA) testing for screening, and the increase in life expectancy of the male population (4), the initial diagnosis of prostate carcinoma is usually based on the digital rectal examination, serum prostate-specific antigen (PSA; ng/ml), and transrectal biopsy using ultrasound (Gleason score), and these patients may undergo bone scintigraphy, computed tomography (CT), or magnetic resonance imaging (MRI).. The role of bone scanning in prostate carcinoma diagnosis, particularly for evaluating osseous metastatic disease, is well-established. Recent guidelines by the European Association of Urology (EAU) affirm this, especially in intermediate- and high-risk cases. The prevalence of vertebral metastasis, often presenting as low back pain, highlights the clinical importance of bone scans. Their global availability and cost-effectiveness, combined with the ability to perform whole-body examinations, make them a valuable diagnostic tool.

OBJECTIVE

To find the correlation between S.PSA level and bone scan findings and to see the variation of bone scan findings in confirmed carcinoma prostate patients of different age groups.

PATIENTS AND METHODS

This was a retrospective analytical study conducted in the scintigraphy division of the National Institute of Nuclear Medicine and Allied Sciences (NINMAS) between February 2023 to August 2023 (6 months). A total of 64 male patients with adenocarcinoma of prostate confirmed by TRUS biopsy and histopathology were enrolled in this study as the study population. A bone scan was done according to the standard protocol with a Siemens dual-head gamma camera after an intravenous injection of an average of 20 mci of 99mTc-MDP. Both anterior and posterior static planner images of the entire axial and appendicular skeleton with multiple spot views were taken. A SPECT image is also taken when needed. The images were interpreted and analyzed by Nuclear Medicine (NM) physicians at this institute. All data were processed, analyzed, and disseminated using MS Excel and SPSS version 23.0.

RESULT

The study included a cohort of 64 participants, with a mean age of 69.60±8.64 years. Among them, 9% fell within the

50–60-year age range, 48% within 61–70 years, 28% within 71–80 years, and 15% were above 80 years. The predominant complaint was low back pain, constituting 84% of the study population (n = 54). Table 1 represents the age distribution data among the study population.

Regarding S. PSA levels 14 patients exhibited S. PSA <4 ng/ml, and the mean S. PSA was 105.97 ng/ml. Notably, 34% of patients presented with S.PSA levels exceeding 100 ng/ml. Figure 1 depicts a ring chart with the distribution of patients based on S.PSA levels.

Approximately 44% of patients had undergone transurethral resection of the prostate (TURP). In bone scan findings among the study population, 27% (n = 17) presented with extensive skeletal metastasis. 23% (n = 15) had a negative outcome for osteoblastic skeletal lesions, 17% (n = 11) had suspicious solitary osteoblastic lesions, 19% (n = 12) exhibited axial osteoblastic lesions, and 14% (n = 9) showed both axial and appendicular osteoblastic lesions. Notably, no patients displayed appendicular bone lesions in the scan. In Figure 2, a pie chart illustrates the pattern of bone scan findings.

The correlation between mean S.PSA levels, mean age groups, and bone scan findings in prostate carcinoma patients is shown in the column chart. Here, patients with extensive skeletal metastasis had both a high mean age of 74 years and a mean S.PSA level of 230.1 ng/mL compared to the patients with a negative or other pattern of osteoblastic lesion denoted as an upward or positive trending line.

Table 1: Total number (n = 64) of prostate carcinoma patients according to different age groups

Age (years)	Number	Percentage
50-60yrs	6	9%
61-70 yrs	31	48%
71-80 yrs	18	28%
>80 yrs	9	15%

Table 2: Different levels of serum PSA in total number of prostate carcinoma patients

Serum PSA (ng/ml)	Number of patients
<4	14
5-20	12
21-40	6
41-60	3
61-80	2
80-100	4
>100	23

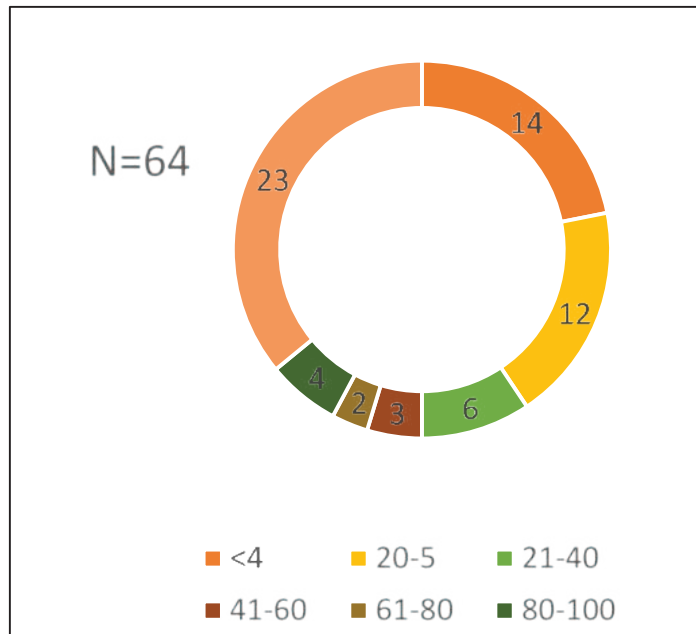


Figure 1: Serum PSA levels in study patients

Table 3: Pattern of osteoblastic lesions among the study population (N=64) along with mean age, mean PSA level and TURP status

Pattern of lesion (Extensivity based)	Number of patients	Percentage	Mean age (years)	Mean PSA level (ng/ml)	S. TURP surgery (no. of patients)
Negative for osteoblastic lesion	15	23%	65.73	42.80	8
Solitary osteoblastic lesion	11	17%	73.72	32.56	6
Axial osteoblastic lesion	12	19%	73.08	33.95	2
Appendicular osteoblastic lesion	0	0	0	0	0
Both axial and appendicular osteoblastic lesion	9	14%	66.80	160.51	6
Extensive skeletal metastasis	17	27%	74	230.1	6

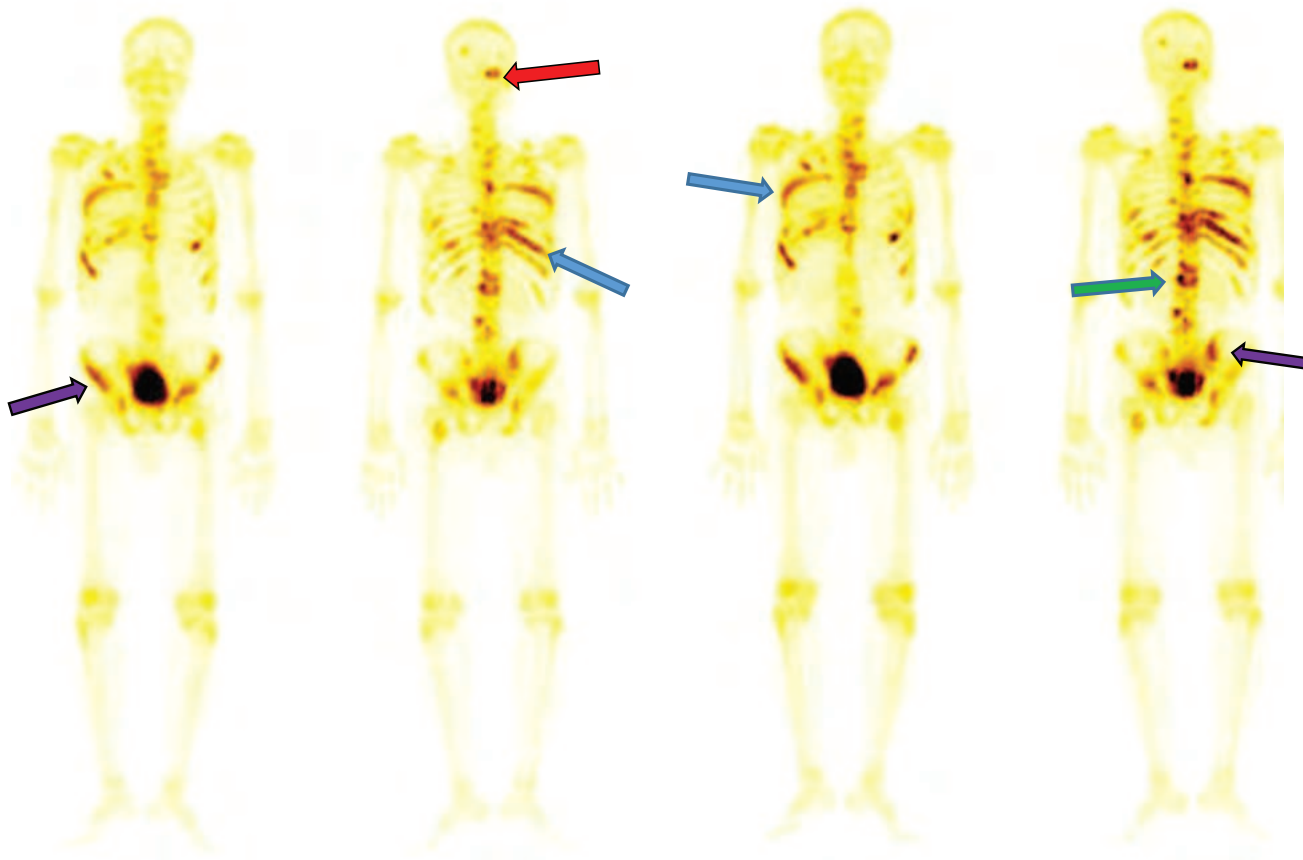


Figure 2: ^{99m}Tc-MDP whole body static bone scan image of a 70 years old man with history of carcinoma prostate and PSA level 126.7ngm/ml, showing extensive skeletal metastases involving skull (red arrow), multiple ribs (blue arrow),vertebrae (green arrow) pelvic bones (purple arrow) in Anterior view and posterior view.

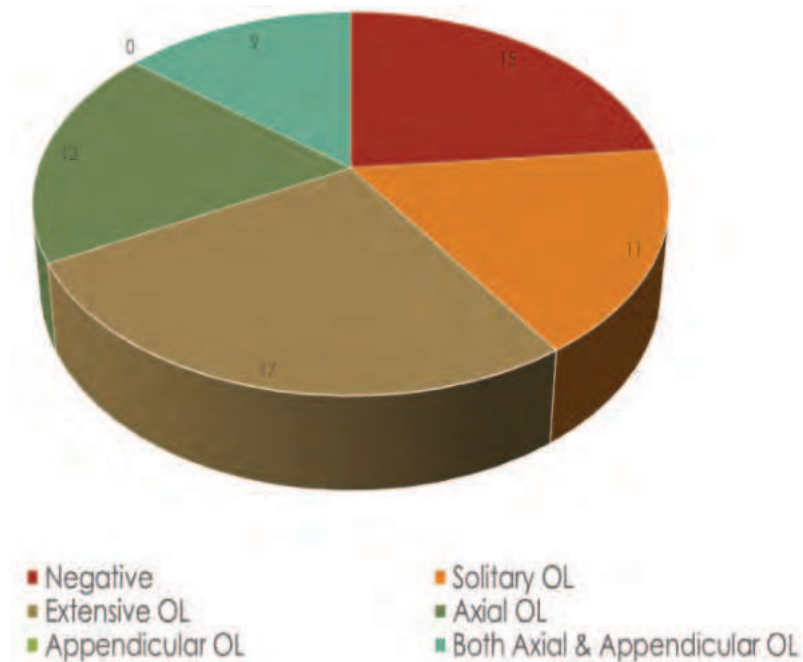


Figure 3: Pattern of bone scan findings of the patients (N=64)

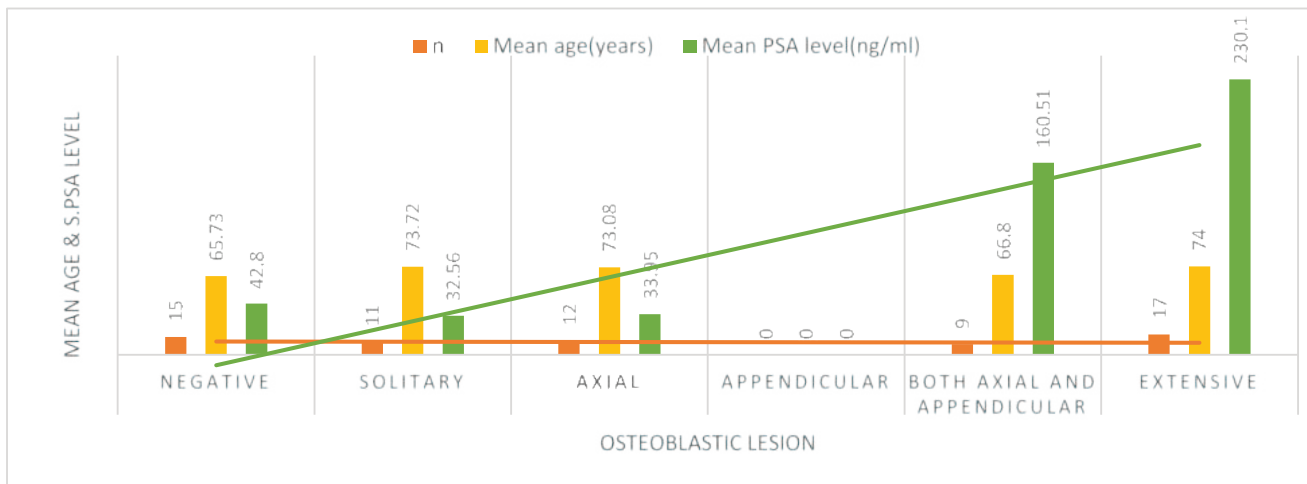


Figure 4: Correlation of mean Serum PSA level, mean age group with bone scan findings of prostate carcinoma patients

DISCUSSION

The mean age of the total participants was 69.60±8.64 years. A comparative reference from a urology journal reports a mean age of 62.4 years (7). Within the study cohort, 9% were aged between 50 and 60 years, while 15% were above 80 years. The predominant age group comprised individuals within the 61–70 age range. Notably, 84% of participants presented with low back pain as the most prevalent complaint. The mean serum prostate-specific antigen (S. PSA) level was identified as 105.97 ng/ml, contrasting with a study reporting a mean S. PSA of 41.78 ng/ml within the range of 8.8 to 100 ng/ml (8). Among the participants, 14 had S.PSA <4 ng/ml, and 34% exhibited S.PSA levels surpassing 100 ng/ml. Approximately 44% of the total cohort underwent transurethral resection of the prostate (TURP) surgery.

Bone scintigraphy revealed that 23% of participants, with a mean age of 65.73 years and a mean PSA level of 42.80 ng/ml, displayed no evidence of osteoblastic skeletal lesions. Additionally, 17% presented with suspicious solitary osteoblastic lesions, 19% with axial osteoblastic lesions, and 14% with both axial and appendicular osteoblastic lesions. Furthermore, 27% exhibited extensive skeletal metastasis, with a mean age of 74 years and a mean PSA level of 230.1 ng/mL.

The study underscores the intricate relationship between serum PSA levels, age, and bone scan outcomes in prostate carcinoma. The observed elevation in mean serum PSA

levels, indicative of extensive skeletal metastasis, aligns with recent research emphasizing the prognostic significance of PSA, as highlighted by Wolff JM et al (6). Nevertheless, these findings notably surpass regional studies, suggesting potential geographic or demographic variations in disease progression (8).

Importantly, the study identifies a substantial incidence of skeletal metastasis in patients with higher PSA levels, underscoring the potential role of bone scans in early diagnosis, particularly in high-risk cohorts. However, it is crucial to acknowledge that progression of prostate carcinoma may occur despite undetectable or low PSA levels, as reported by Leibovici et al (9). This consideration is pivotal in light of evolving prostate carcinoma screening guidelines and the shift towards personalized care, as discussed by Sheng et al (2).

The prevalence of low back pain as a symptom in 84% of patients reaffirms the clinical relevance of skeletal involvement in prostate carcinoma, as highlighted by Thompson et al (7). The mean age of participants aligns with global age-related prostate carcinoma risks, emphasizing the necessity for age-specific screening approaches, as indicated by Siegel et al (1). While cancer-specific survival post-surgery for prostate carcinoma metastatic to bone is reported to be poor (10), the high incidence of osteoblastic lesions in patients with elevated PSA levels underscores the sensitivity of bone scintigraphy in detecting metastatic spread, thereby

influencing treatment decisions, as discussed by Love et al (5). However, this also raises concerns regarding overdiagnosis, necessitating careful patient selection for bone scanning, as articulated by Lai et al (4).

The limitations of this study include its retrospective nature and the confined sample size, which may affect the generalize ability of the results. Future research with larger, more diverse cohorts and longitudinal designs would be beneficial to validate and expand upon our findings. Additionally, exploring the molecular mechanisms underlying these correlations could provide deeper insights into prostate carcinoma metastasis, potentially guiding more targeted therapeutic approaches.

CONCLUSION

The study emphasizes the intricate link between S.PSA level, age, and bone scan profiles in prostate carcinoma, recommending a nuanced patient monitoring and management approach.

REFERENCES

1. Siegel RL, Miller KD, Wagle NS, Jemal A. Cancer statistics, 2023. *Ca Cancer J Clin.* 2023 Jan 1;73(1):17-48.
2. Sheng IY, Wei W, Chen YW, Gilligan TD, Barata PC, Ornstein MC, Rini BI, Garcia JA. Implications of the United States Preventive Services Task Force recommendations on prostate cancer stage migration. *Clin Genitourin Cancer.* 2021 Feb 1;19(1):e12-6.
3. Devasia TP, Mariotto AB, Nyame YA, Etzioni R. Estimating the number of men living with metastatic prostate cancer in the United States. *Cancer Epidemiol Biomarkers Prev.* 2023 May 1;32(5):659-65.
4. Lai MH, Luk WH, Chan JC. Predicting bone scan findings using sPSA in patients newly diagnosed with prostate cancer: feasibility in the Asian population. *Urol Oncol.* 2011 May 1;29(3):275-9.
5. Love C, Din AS, Tomas MB, Kalapparambath TP, Palestro CJ. Radionuclide bone imaging: an illustrative review. *Radiographics.* 2003 Mar;23(2):341-58.
6. Wolff JM, Bares R, Jung PK, Buell U, Jakse G. Prostate-specific antigen as a marker of bone metastasis in patients with prostate cancer. *Urol Int.* 1996;56(3):169-73.
7. Thompson JE, Moses D, Shnier R, Brenner P, Delprado W, Ponsky L, Pulbrook M, Böhm M, Haynes AM, Hayen A, Stricker PD. Multiparametric magnetic resonance imaging-guided diagnostic biopsy detects significant prostate cancer and could reduce unnecessary biopsies and over detection: a prospective study. *J Urol.* 2014 Jul;192(1):67-74.
8. Biplab DD, Gupta SD, Uddin SM, Kundu B, Hasan MM, Bose A, Azad AK, Manzer TA. Features and presentations of suspected harboring prostate cancer patients: a study in a tertiary care hospital in Bangladesh. *Sch J App Med Sci.* 2023 Jul;7:1366-72.
9. Leibovici D, Spiess PE, Agarwal PK, Tu SM, Pettaway CA, Hitzhusen K, Millikan RE, Pisters LL. Prostate cancer progression in the presence of undetectable or low serum prostate-specific antigen level. *Cancer.* 2007 Jan 15;109(2):198-204.
10. Cheville JC, Tindall D, Boelter C, Jenkins R, Lohse CM, Pankratz VS, Sebo TJ, Davis B, Blute ML. Metastatic prostate carcinoma to bone: clinical and pathologic features associated with cancer-specific survival. *Cancer.* 2002 Sep 1;95(5):1028-36.