

## Case Report

# Endoscopic Removal of Third Ventricular Colloid Cyst: A Case Report

Nath HD<sup>1</sup>, Barua KK<sup>2</sup>, Islam MM<sup>3</sup>, Barua S<sup>4</sup>, Mukherjee S<sup>5</sup>, Bhattacharjee R<sup>6</sup>

**Conflict of interest:** There is no conflict of interest relevant to this paper to disclose.

**Funding Agency:** was not funded by any institute or any group.

**Contribution of Authors:** Principal Investigator and Manuscript preparation- Data collection- Scalp block with anaesthesia- Editorial formatting-

**Copyright:** ©2020bang.BJNS published by BSNS. This article is published under the creative commons CC-BY-NC license. This license permits use distribution (<https://creativecommons.org/licenses/by-nc/4-0/>) reproduction in any medium, provided the original work is properly cited and is not used for commercial purposes.

**Received:** 02.01.20

**Accepted:** 04.03.20

### Abstract:

*Third ventricular colloid cyst is slow-growing benign tumor comprising <1% of intracranial tumors. Previously it was removed by interhemispheric transcallosal or transcortical approach. Now a days, endoscopic removal of colloid cyst is a popular option because it is less invasive, panoramic view helps in total removal of tumor. Here we are reporting a 8 years old boy presented with occasional headache, vomiting, seizure and loss of consciousness for 3 months. Neuro-imaging revealed anterior third ventricular colloid cyst. We removed the tumor completely with rigid neuroendoscope which was confirmed by histopathology. After three months follow up patient was quiet healthy.*

**Key words:** Third ventricular Colloid cyst, rigid endoscope, Transcortical, Transcallosal

*Bang. J Neurosurgery 2020; 10(1): 119-122*

### Introduction

Colloid cyst of the third ventricle is an uncommon lesion and the reported incidence is 3.2 per 100,000 population.<sup>1</sup> The natural history is varied and most of the patients have an insidious course. However, some of the patients present with sudden neurological deterioration: drop attacks; life-threatening acute hydrocephalus; and sudden death.<sup>1,2,3</sup> Even though the treatment approach for asymptomatic incidentally detected colloid cysts is debatable, most neurosurgeons advise intervention to avoid catastrophic neurological deterioration. However, long-term follow-up study of 68 subjects with asymptomatic colloid cysts suggests that only a few (8%) subjects go on to develop symptoms at 10 years.<sup>1,4</sup>

The surgical approach for symptomatic colloid cysts is varied. The operative procedures usually consist of open microsurgical excision techniques.<sup>5</sup> Less often stereotactic aspiration or stereotactic-guided surgery have been described.<sup>6</sup> Endoscopic approach for excision of colloid cysts is relatively recent and offers the advantage of excellent visualization and minimally invasive corridor through the naturally dilated ventricular system. A more controlled resection of the cyst is possible through this approach avoiding damage to critical structures in the anterior third ventricle. We have presented this case because of minimal invasiveness of the procedure.

1. Dr. Haradhan Deb Nath, Associate Professor, Department of Neurosurgery, Bangabandhu Sheikh Mujib Medical University, Dhaka
2. Prof. Kanak Kanti Barua, Professor & Chairman, Department of Neurosurgery, Bangabandhu Sheikh Mujib Medical University, Dhaka
3. Dr. Md. Monirul Islam, Resident, Department of Neurosurgery, Bangabandhu Sheikh Mujib Medical University, Dhaka
4. Dr. Sudip Barua, Resident, Department of Neurosurgery, National Institute of Neuroscience, Dhaka.
5. Dr. Sudipta Mukherjee, Assistant Professor, Department of Neurosurgery, National Institute of Neuroscience, Dhaka
6. Dr. Rajib Bhattacharjee, Resident, Department of Neurosurgery, Bangabandhu Sheikh Mujib Medical University, Dhaka

**Address to Correspondence:** Dr. Haradhan Deb Nath, Associate Professor, Department of Neurosurgery, Bangabandhu Sheikh Mujib Medical University, Dhaka, Mobile-01711354120, E-mail: dr.haradhan@yahoo.com

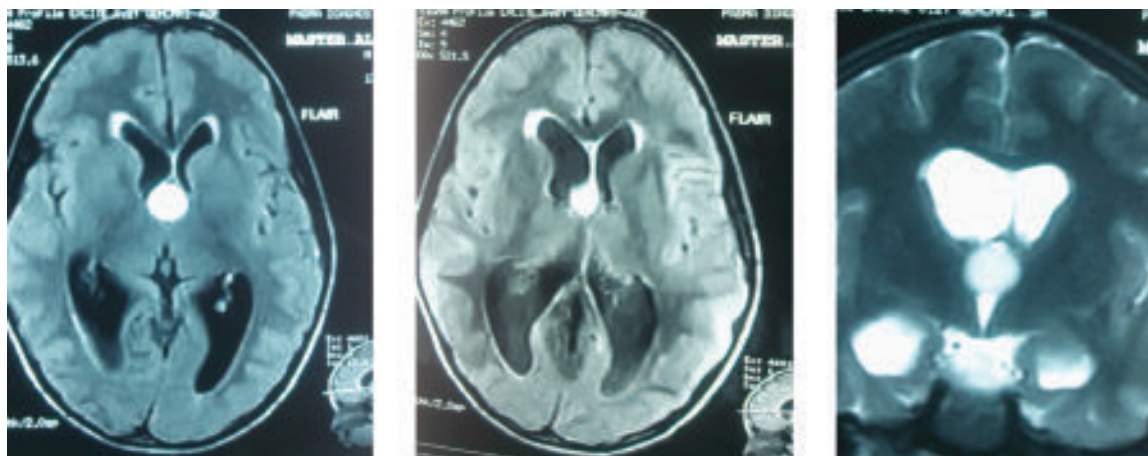
**Case report**

A 8 years old boy has presented with occasional headache, vomiting for three months. Intensity of headache increased at very early in the morning and was global in nature. His father also complaints of occasional seizure for several times which was generalized, clonic, tonic in nature. Seizure has persisted for few minutes. There was history of tongue bite, frothing with seizure. His father also complaints of occasional loss of consciousness for a brief period

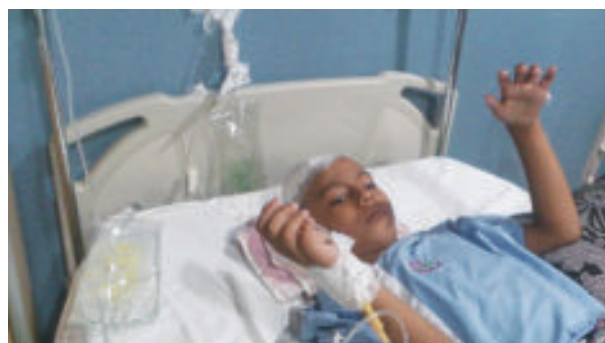for several times. Computerized tomography scan (CT scan), Magnetic Resonance Imaging scan (MRI) with contrast showed colloid cyst at the anterior part of the third ventricle. We operated the case with rigid neuroendoscope and with the help of flexible neuroendoscope.

**Surgical technique**

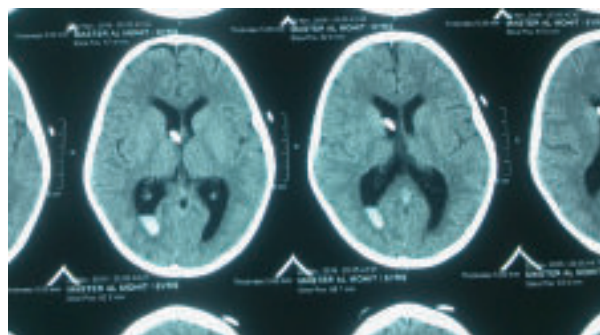
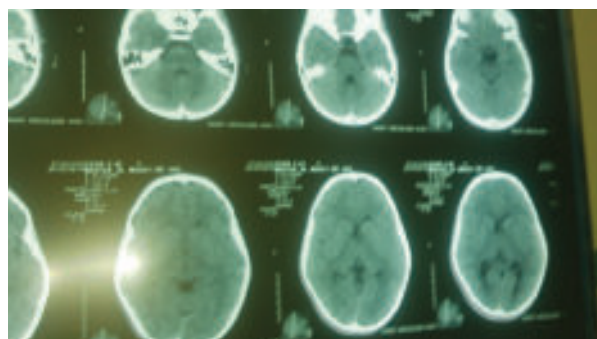
The patient underwent the procedure under general anesthesia. Patient was positioned supine with the




**Fig.-1:** (1a, 1b, 1c): Preoperative MRI of brain shows colloid cyst at third ventricle



**Fig.-2:** Postoperative patient with external ventricular drainage



**Fig.-3:** Postoperative CT scan of brain with shunt tube and ventricular haemorrhage



**Fig.-4:** Postoperative CT scan after 3 months

head resting on a pillow in the neutral position. The burr hole position, though roughly described as precoronal frontal burr-hole, was adjusted to the location of the colloid cyst with respect to the structures around the foramen of Munro. Generally, the burr hole corresponded to a point 4 to 5 cm away from midline and 4 cm anterior to the coronal suture. We used a freehand cannulation of the ventricles with the endoscope sheath and the obturator. In most of the patients, an obturator telescope was used which enabled visualization of the path of entry. We only used rigid endoscopes because of their superior optics and safer maneuverability inside the ventricular system. Flexible scopes were used whenever inspection within the lateral ventricles was required, e.g. to look at the end of the surgical procedure.

After ventricular puncture, the obturator was withdrawn and the endoscope introduced to visualize the foramen of Monro, the septum pellucidum, thalamostriate vein and the choroid plexus. In this case the colloid cyst was seen bulging through the foramen of Monro into the ipsilateral lateral ventricle. The endoscopic coagulator was then introduced. The cyst wall was then coagulated carefully allowing the vascular fibrous outer layer to shrink towards the probe, avoiding contact of the probe with normal ventricular structures at all times. The cyst wall was cut open by endoscopic scissors. Once this was done, a Fogarty balloon was inserted through the cyst wall and inflated to enlarge the opening. Thereafter, the cyst contents were aspirated.

We have introduced an external ventricular drainage for five days. Postoperatively patients developed small lateral ventricular haemorrhage. Ventricular haemorrhage become clear after five days. Postoperatively patient was uneventful. After 3 months follow up with CT scan there was no residual tumour and there was no clinical signs & symptoms. Patients used to take the anticonvulsant drug.

### Discussion

Colloid cysts occur most commonly in the fourth through seventh decade.<sup>7</sup> The symptom profile in our patient was similar to the other reports.<sup>8,10,11</sup> Mishra et al. reported about 22% of patients in their series had triad of memory loss, gait abnormality and incontinence, symptom complex of normal pressure hydrocephalus. The mean age of these patients at presentation was 44 years. In our patient had gait disturbance, headache, vomiting and seizure.

The optimal surgical management of colloid cysts continues to be a matter of debate. Colloid cysts are benign lesions with low risk of recurrence after radical resection. Open microsurgical excision was traditionally considered the “gold standard” treatment. However, operative approaches are not without risks. Of the 38 patients who underwent transcortical-transventricular resection of the colloid cyst, 30% of patients had postoperative complications. In Transcallosal approach avoids the potential risks of a cortical incision, but still is associated with occasionally serious morbidity. The reported complications of this approach include cortical venous infarct, forniceal damage, injury to the deep venous system, subdural hematoma, disconnection syndromes, ventriculitis and meningitis.<sup>6</sup> In this case there was ventricular haemorrhage and was managed by external ventricular drainage.

The quest for less invasive approaches for deal these lesions, led to the introduction of aspiration techniques for decompression of the cyst. Free-hand aspiration of colloid cysts was attempted in 1975 by Gutierrez-Lara, *et al.*<sup>12</sup> To increase the accuracy of the procedure, stereotactic guidance was employed first by Bosch and co-workers<sup>13</sup> and it gradually gained popularity, because the procedure is associated with negligible morbidity. However, it was soon realized that not all colloid cysts could be suitable for aspiration and high viscosity of the cyst contents seriously limited the evacuation of cyst material.<sup>7,8,9</sup> Kondziolka and colleagues<sup>6</sup> had found that only cysts which are hypodense or isodense on plain CT may be amenable to successful aspiration.

It is to be acknowledged that there is a definitive learning curve associated with the endoscopic treatment of colloid cysts. Presently we have attempted to perform a gross total excision of tumour.

### Conclusion

We would prefer to approach such lesion through endoscope. Endoscopically resecting such lesions would prevent involve excessive manipulation of the fornix which can potentially cause short-term memory loss.

### Reference

1. Shashwat Mishra, P Sarat Chandra, Ashish Suri, K Rajender, Bhawani S Sharma, AK Mahapatra. Endoscopic management of third ventricular colloid cysts: Eight years' institutional experience and description of a new technique. *Neurol India* 2010;58:412-7.

2. Camacho A, Abernathy CD, Kelly PJ, Laws ER Jr. Colloid cysts: Experience with the management of 84 cases since the introduction of computed tomography. *Neurosurgery* 1989;24:693-700.
3. B?ttner A, Winkler PA, Eisenmenger W, Weis S. Colloid cysts of the third ventricle with fatal outcome: A report of two cases and review of literature. *Int J Legal Med* 1997;110:260-6.
4. Pollock BE, Huston J 3rd. Natural history of asymptomatic colloid cysts of the third ventricle. *J Neurosurg* 1999;91:364-9.
5. Lewis AI, Crone KR, Taha J, van Loveren HR, Yeh HS, Tew JM Jr. Surgical resection of third ventricle colloid cysts: Preliminary results comparing transcallosal microsurgery with endoscopy. *J Neurosurg* 1994;81: 174-8.
6. Apuzzo ML, Chikovani OK, Gott PS, Teng EL, Zee CS, Giannotta SL, *et al.* Transcallosal, interforncial approaches for lesions affecting the third ventricle: Surgical considerations and consequences. *Neurosurgery* 1982;10:547-54.
7. King WA, Ullman JS, Frazee JG, Post KD, Bergsneider M. Endoscopic resection of colloid cysts: Surgical considerations using the rigid endoscope. *Neurosurgery* 1999;44:1103-11.
8. Hellwig D, Bauer BL, Schulte M, Gatscher S, Riegel T, Bertalanffy H. Neuroendoscopic treatment for colloid cysts of the third ventricle: the experience of a decade. *Neurosurgery* 2003;52:525-33.
9. Gutierrez-Lara F, Pati?o R, Hakim S. Treatment of tumors of the third ventricle: A new and simple technique. *Surg Neurol* 1975;3:323-5.
10. Bosch DA, Rdhn T, Backlund EO. Treatment of colloid cysts of the third ventricle by stereotactic aspiration. *Surg Neurol* 1978;9:15-8.
11. Auer LM, Holzer P, Ascher PW, Heppner F. Endoscopic neurosurgery. *ActaNeurochir (Wien)* 1988;90:1-14.
12. Decq P, Le Guerinel C, Brugieres P, Djindjian M, Silva D, Keravel Y, *et al.* Endoscopic management of colloid cysts. *Neurosurgery* 1998;42:1288-94.
13. Rodziewicz GS, Smith MV, Hodge CJ Jr. Endoscopic colloid cyst surgery. *Neurosurgery* 2000;46:655-62.