

## Case Report

# Congenital Dorsal Dermal Sinus, A Rare Entity: diagnosis and Management

Das S<sup>1</sup>, Shah SK<sup>2</sup>, Ahmed MM<sup>3</sup>, Khan AH<sup>4</sup>

**Conflict of Interest:** There is no conflict of interest relevant to this paper to disclose.

**Funding Agency:** Was not funded by any institute or any group.

**Contribution of Author:** Principal Investigator- Dr. Sukriti Das

Manuscript Preparation- Dr. Satish Kumar Shah

Data Collection- Dr. Mohammad Mamun Ahmed

Editorial Formatting: Dr. Akhlaque Hossain Khan

**Copyright:** ©2021 bang.BJNS published by BSNS. This published by BJNS. This article is published under the creative commons CC-BY-NC license. This license permits use distribution (<http://creativecommons.org/licenses/by-nc/4-0/>) reproduction in any medium, provided the original work is properly cited and is not used for commercial purposes.

**Received:** 15 October, 2021

**Accepted:** 20 October, 2021

### Abstract:

*Congenital dorsal dermal sinus is a rare occult spinal dysraphism. It may be associated with other cutaneous manifestations and spinal pathologies. Patients either presents with infection or neurological problems. We present a case presented with dorsal dermal sinus with discharging sinus with split cord with block vertebra with hypertrichosis and hairy melanocytic naevus.*

**Keywords:** Congenital dermal sinus, hypertrichosis, excision of sinus tract.

### Abbreviations:

CDS- congenital dermal sinus D-dorsal vertebra

MRI- Magnetic resonance imaging

*Bang. J Neurosurgery 2021; 11(1): 45-49*

### Introduction:

A congenital dermal sinus is a rare form of spinal dysraphism that occurs when a focal zone of the ectoderm fails to detach from the original neuroectoderm, a phenomenon termed as nondisjunction. It stops the insertion and future growth of mesodermal tissue, which generally split up the spinal cord from the skin. The fusion of neural folds first occur in thoracic and cervical regions. Thoracic and cervical regions are the rare sites for dorsal dermal sinus, whereas lumbosacral and occipital dermal sinuses are relatively frequent. Dermal sinus tracts are frequently accompanied by other cutaneous and intradural pathologies. The presence of dorsal dermal sinus in the upper thoracic region is rare.

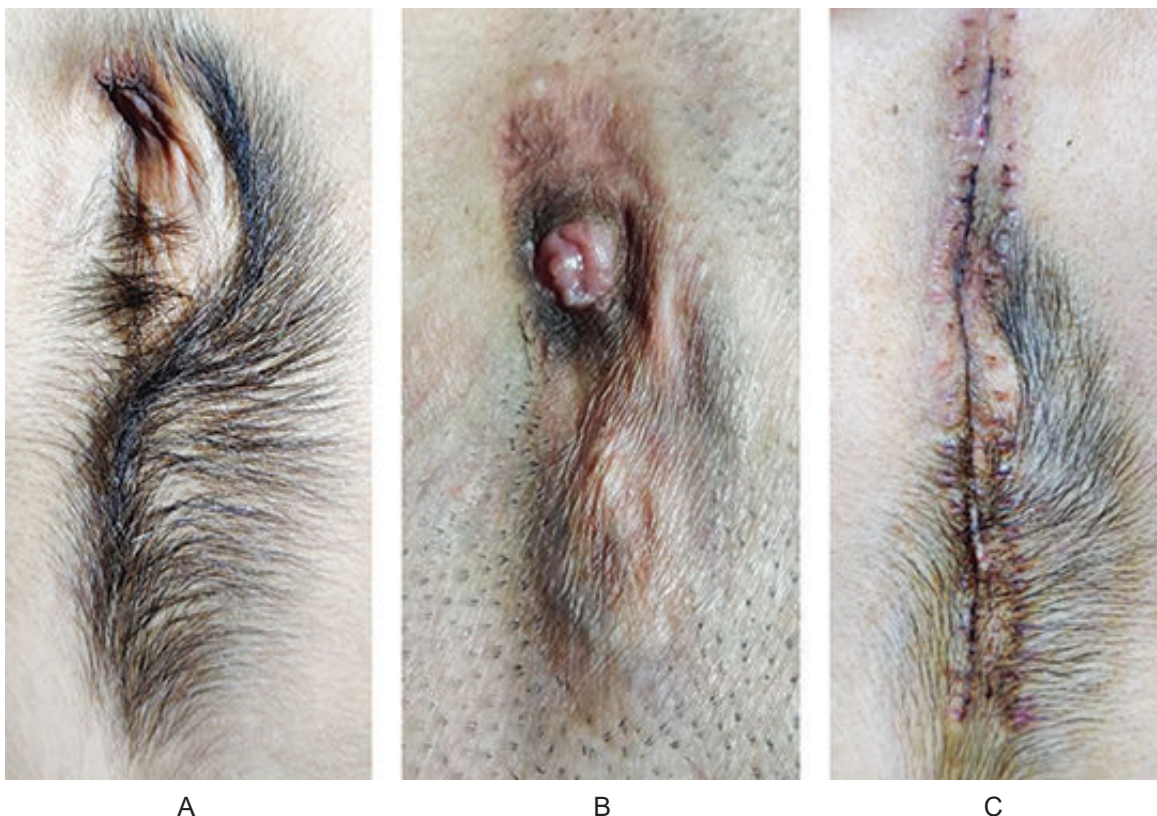### Case Report:

An 18 year-old female child presented with a cutaneous lesion in mid dorsal region since her childhood. She had a skin dimple with hair follicle surrounding it since her birth. There was an intermittent sebaceous discharge through the sinus. On physical examination, the patient's skin over the upper thoracic region showed a midline sinus with hypertrichosis (Figure 1: a & b). She also has hairy melanocytic naevus on her right arm (Figure 2). She was neurologically intact with no motor or sensory deficit.

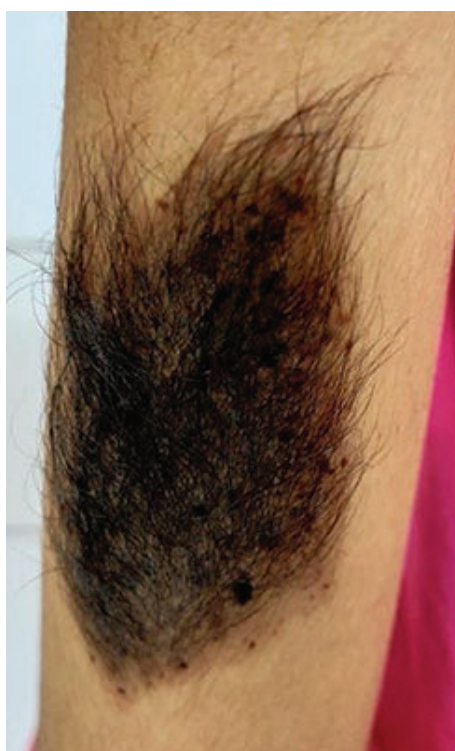Magnetic resonance imaging (MRI) of dorsal spine revealed congenital block vertebrae with contrast

1. Dr. Sukriti Das, Associate Professor, Department of Neurosurgery, Bangabandhu Sheikh Mujib Medical University, Dhaka, Bangladesh.
2. Dr. Satish Kumar Shah Resident, Department of Neurosurgery, Bangabandhu Sheikh Mujib Medical University, Dhaka, Bangladesh.
3. Dr. Mohammad Mamun Ahmed, Resident, Department of Neurosurgery, Bangabandhu Sheikh Mujib Medical University, Dhaka, Bangladesh.
4. Dr. Akhlaque Hossain Khan, Professor, Department of Neurosurgery, Bangabandhu Sheikh Mujib Medical University, Dhaka, Bangladesh.

**Address of Correspondence:** Dr. Sukriti Das, Associate Professor, Department of Neurosurgery, Bangabandhu Sheikh Mujib Medical University, Dhaka, Bangladesh. Email: [sukriti66@yahoo.com](mailto:sukriti66@yahoo.com), Mbl.: +880-1971676847



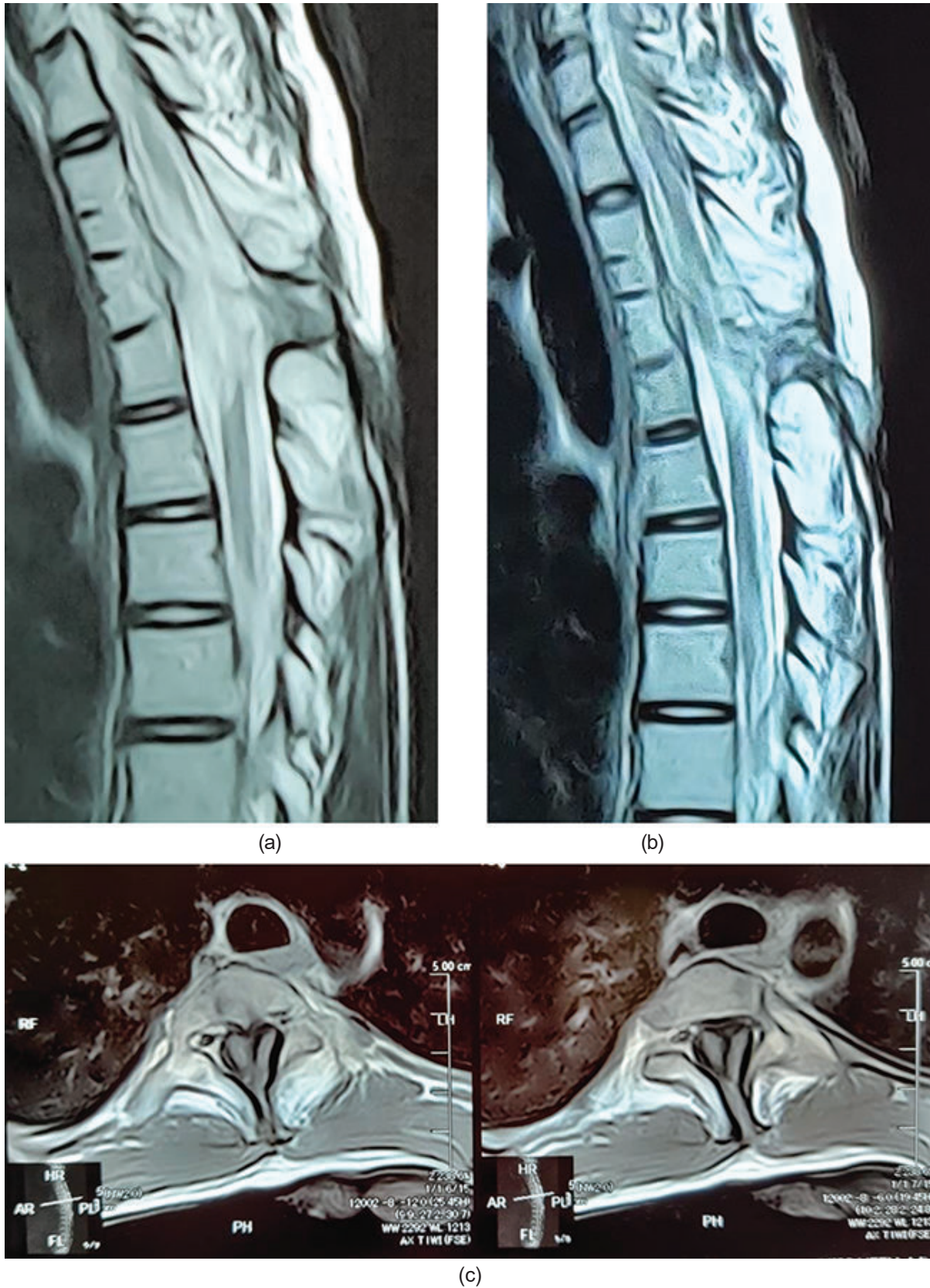
**Fig.-1:** Dermal sinus with hypertrichosis (A. & B. Pre-operative C. Post-operative)



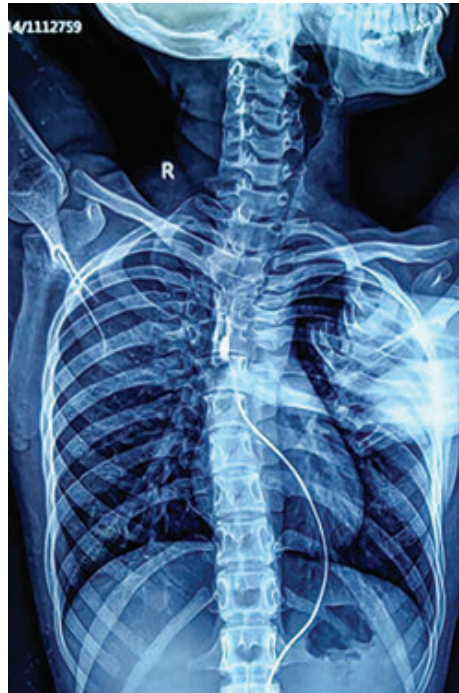**Fig.-2:** Hairy melanocytic Naevus

enhanced sinus tract at the level of 5<sup>th</sup> & 6<sup>th</sup> dorsal vertebra (D5 & D6) with spinal cord bifurcation against the same level (Figure 3). Sinugram with fluoroscopy and spot radiography revealed small sinus tract in the back of upper dorsal region 4<sup>th</sup> & 5<sup>th</sup> dorsal vertebra (D4 & D6) which was opacified and there was no fistulous communication (Figure 4).

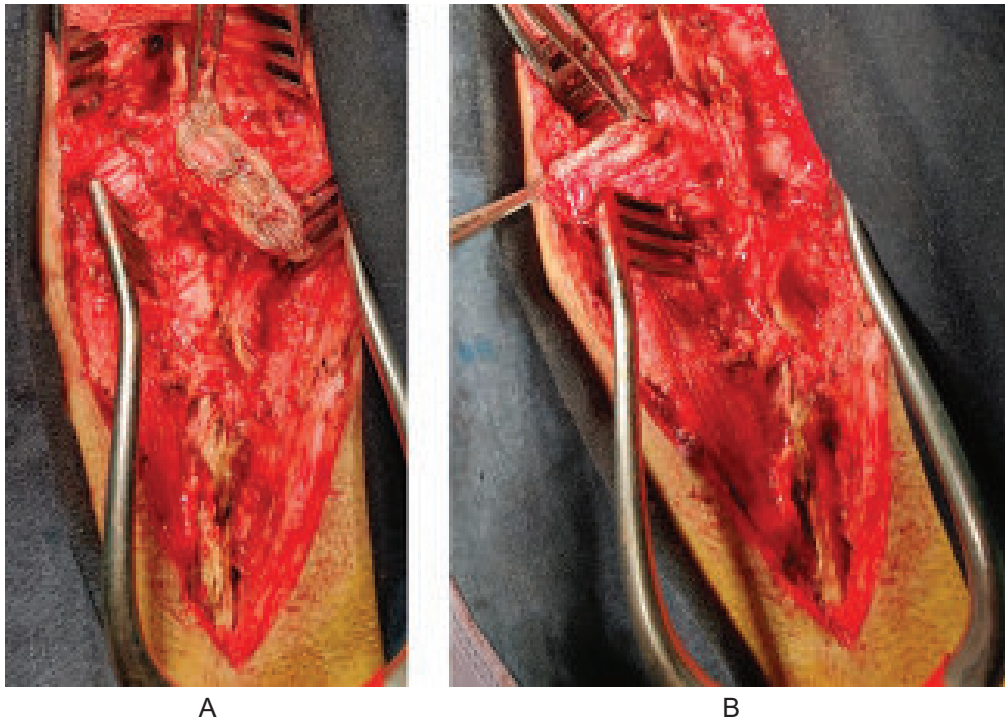
During operation, in prone position, vertical midline with an elliptical skin incision encircling the skin dimple was made. Complete laminectomy of D5 and partial laminectomy of D4 & D6 was performed. The sinus tract was followed with the dissection of the dermal sinus stalk. The sinus tract was found encroached above the duramater. So, the dura was not opened. Sebaceous materials and tuft of hair was seen within the sinus tract. Complete excision of sinus tract was done without damaging the neural tissue (Figure 5). The intraoperative and postoperative period was uneventful. There was no deterioration in neurological function on her follow-up.



**Fig.-3:** MRI of spine T1WI (a) & T2WI (b) showing dorsal dermal sinus with block vertebra, (c): MRI of spine axial view showing extension of sinus tract with bifurcation of spinal cord.



**Fig.-4:** Sinogram showing small sinus tract in the back of upper dorsal region D4-D5 which was opacified with no fistulous communication.



**Fig.-5: (A.&B.):** Intraoperative excision of sinus tract.

**Discussion:**

Verebely first described dermal sinus in 1913. Walker and Bucy first used the term “congenital dermal sinus”

in 1934<sup>1</sup>. Congenital dorsal dermal sinus (CDS) is a disorder of abnormal neurulation in which there is focal nondisjunction of surface and neural ectoderm

resulting in an epithelium lined tract extending inward to the spinal canal from the skin surface with an open skin defect<sup>2</sup>. CDS occurs during neurulation when the neural groove closes to form the neural tube on day 26 of gestation and results from a failure of neuroectoderm to separate from the cutaneous ectoderm<sup>3</sup>. The neural folds fuse earlier at thoracic and cervical regions, hence these are rare sites for dermal sinus, although, they can arise at any level straight through the spinal axis, generally they occur at one end of the neural tube. In order of occurrence, it is confined most frequently to the lumbosacral area (41%), followed by the thoracic (10%) and cervical (1%) areas. It has been estimated that the dermal sinus tract reaches the thecal sac in 60% of the cases, and it terminates in the epidural space in less than 20% of the patients, and rarely terminate blindly in subcutaneous tissue<sup>4,5</sup>. The accompanying cutaneous stigmata comprise abnormal pigmentation, hemangioma, hypertrichosis, and subcutaneous lipoma. Tethered cord, bifid lamina, split cord malformation, inclusion tumors such as epidermoid and dermoid lesions and posterior arch defects of the vertebral column can be found in conjunction with CDS<sup>6,7</sup>.

The patients become symptomatic either by infection due to bacterial ascent through the sinus tract or because of compression of neural structures by an associated dermoid or epidermoid tumor. In uncomplicated, asymptomatic patients with dermal sinus tracts, there is no universal author agreement about the timing of surgery, however, it looks reasonable to go on with surgery whenever the patient is physiologically ready for surgery. Prophylactic surgery is believed to minimize the hazard of complications instead of waiting until infection becomes established with subsequent local anatomical changes<sup>8</sup>. Infection can arise any place through the dermal sinus tract, from dermal mouth opening to the spinal cord, besides extraspinal places, for example, the mediastinum. Although there is some debate about surgery during an active infection, it is generally considered wise to delay the surgery for weeks till it becomes controlled<sup>9</sup>.

### Conclusion:

Dermal sinus in mid dorsal spine associated with cutaneous stigmata with spinal cord abnormality and vertebral arch deformity is a rare entity. Patient with dermal sinus should be evaluated early with spinal imaging preferably by MRI of spine to rule out any

underlying spinal cord lesion which will facilitate better treatment at the early stage of disease, thus preventing development of neurological deficit. Early diagnosis and prompt surgical intervention offer the best chance of functional neurological recovery and prevent serious morbidity.

### Declarations:

Acknowledgements: None

**Funding support and sponsorship:** This research did not receive any specific grant from funding agencies in the public, commercial, or not-for-profit sectors.

**Conflicts of interest:** There are no conflicts of interest.

**Patient consent:** An informed written consent was obtained from the patient.

**Ethics approval:** There is no ethics issue in this paper.

### References:

1. Amador L, Hankinson J, Bigler J. Congenital spinal dermal sinuses. *The Journal of Pediatrics*.1955;47(3):300-310.
2. Patwari S, Reddy B, Kapanigowda M, Ramesha S, Chadaga H. Thoracic dorsal dermal sinus with secondarily infected intramedullary dermoid cyst. *Asian Journal of Neurosurgery*.2019;14(3):975-977.
3. Wang K, Yang H, Oh C, Kim H, Cho B. Spinal congenital dermal sinus—experience of 5 cases over a period of 10 years. *Journal of Korean Medical Science*.1993;8(5):341-347.
4. Abderrahmen K, Kallel J, Jemel H. Unusual Case of Multiple Lateral Spinal Dermal Sinuses in a Child. *Pediatrics & Neonatology*.2017;58(2):189-190.
5. Petrov M, Gerganov V, Gabrovsky N, Kamenova M. Congenital dermal sinus tract localized in the cervical region in an adult patient—Clinical case. *Review of the literature. Interdisciplinary Neurosurgery*.2020;21.
6. Karatas Y, Ustun M. Congenital cervical dermal sinus tract caused tethered cord syndrome in an adult: a case report. *Spinal Cord Series and Cases*.2015;1(1).
7. Mishra S, Panigrahi S. Thoracic congenital dermal sinus associated with intramedullary spinal dermoid cyst. *Journal of Pediatric Neurosciences*.2014;9(1):30.
8. Tono V, Bertolotti S, Maltese F, Canonico F, Sganzerla E, Giussani C et al. A Girl with Life Threatening Meningitis Caused by an Infected Dermoid Cyst Derived from an Occult Dermal Sinus. *Case Reports in Clinical Medicine*.2014;03(08):450-456.
9. Cox E, Knudson K, Manjila S, Cohen A. Unusual presentation of congenital dermal sinus: tethered spinal cord with intradural epidermoid and dual paramedian cutaneous ostia. *Neurosurgical Focus*.2012;33(4):E5.