

Case Report

360-degree Cervico-Dorsal Fixation through a Single Posterior Approach in a 19 years Old Male with Expansile Bone Mass: A Case Report

Chowdhury D¹, Rahman A², Khan RA³, Sikder MSR⁴, Amin FAA⁵, Ahmmed T⁶, Husna AU⁷, Islam MA⁸

Conflict of Interest: There is no conflict of interest relevant to this paper to disclose.

Funding Agency: Was not funded by any institute or any group.

Contribution of Author: Principal Investigator- Prof. Dr. Dhiman Chowdhury

Manuscript Preparation- Dr. Atikur Rahman, Dr Robert Ahmed Khan, Dr. Md. Shahidur Rahman Sikder

Data Collection- Dr. Firoj Ahmed Al-Amin, Dr. Tayeb Ahmmed, Dr. Asma Ul Husna, Dr Md. Ariful Islam

Editorial Formatting: Prof. Dr. Dhiman Chowdhury

Copyright: ©2021 bang.BJNS published by BSNS. This published by BJNS. This article is published under the creative commons CC-BY-NC license. This license permits use distribution (<http://creativecommons.org/licenses/by-nc/4-0/>) reproduction in any medium, provided the original work is properly cited and is not used for commercial purposes.

Received: 14 June, 2021
Accepted: 27 August, 2021

Abstract:

Cervico-Dorsal junction is a transitional zone of spinal column. 360-degree fixation of cervico-dorsal region in a single posterior approach is a difficult and challenging procedure accounting the spinal cord decompression, posterior vertebral body replacement and then posterior instrumentation. Here we have described a patient who presented with features of spastic paraparesis and lower motor palsy of right upper limb due to an expansile bone mass on Rt side of cervico-dorsal region. He underwent neuronal decompression and 360-stabilisation in a single posterior approach. We review clinical and radiographic features of the patient; the procedure underwent as well as current other treatment options with reference to the relevant literatures.

Keyword: 360-degree fixation, cervico-dorsal junction, single posterior approach

Bang. J Neurosurgery 2022; 11(2): 122-127

Introduction

The cervicothoracic junction is a transitional zone between the lordotic cervical spine and the kyphotic thoracic spine. Because the cervicothoracic vertebrae are weight-bearing structures, destruction of these

vertebrae results in spinal instability, severe kyphotic deformity and progressive neurological deficit, which cause severe suffering for the patients¹. Due to complicated anatomical relationships of the region, with the sternum, clavicles and mediastinum in the

1. Prof. Dr. Dhiman Chowdhury, Professor and Unit Chief, Skull Base Unit, Department of Neurosurgery, Bangabandhu Sheikh Mujib Medical University
2. Dr. Atikur Rahman, Associate Professor, Department of Neurosurgery, Bangabandhu Sheikh Mujib Medical University
3. Dr Robert Ahmed Khan, Consultant Neurosurgeon, Department of Neurosurgery, Bangabandhu Sheikh Mujib Medical University
4. Dr. Md. Shahidur Rahman Sikder, Resident, Department of Neurosurgery, Bangabandhu Sheikh Mujib Medical University
5. Dr. Firoj Ahmed Al-Amin, Resident, Department of Neurosurgery, Bangabandhu Sheikh Mujib Medical University
6. Dr. Tayeb Ahmmed, Resident, Department of Neurosurgery, Bangabandhu Sheikh Mujib Medical University
7. Dr. Asma Ul Husna, Resident, Department of Neurosurgery, Bangabandhu Sheikh Mujib Medical University
8. Dr Md. Ariful Islam, Resident, Department of Neurosurgery, Bangabandhu Sheikh Mujib Medical University

Address of Correspondence: Prof. Dr. Dhiman Chowdhury, Professor and Unit Chief, Skull Base Unit, Department of Neurosurgery, Bangabandhu Sheikh Mujib Medical University, Dhaka. Mobile: +8801714090951, E-mail: dhiman_ns@yahoo.com

front and the scapulae in the back, surgical exposure is usually less than satisfactory and making surgical procedures even more challenging².

Currently, approaches to the cervicothoracic spine include conventional anterior cervical approach, anterior approach combined with sternotomy or manubriotomy, standard transclavicular approach, approach by resection of the manubrio-clavicular complex, anterolateral transthoracic approach, and combined approaches. To choose a correct suitable particular surgical approach depends on the localization of the tumor, bone quality, previous intervention, type of required reconstruction, patient's medical conditions and not least on surgeon's familiarity with the technique.

A vertebra may be enlarged by numerous benign and malignant disease processes. The entire vertebra or a portion of the bone may be affected. An expansile vertebral lesion may be osteolytic, osteoblastic, or mixed. The margin of a benign lytic lesion is well defined and sclerotic, whereas an aggressive, malignant lesion shows ill-defined borders. Paravertebral extension usually occurs with aggressive, malignant lesions, but it may also be encountered in benign lesions in the presence of a pathologic fracture³. Bone expansion may occur in all directions, or it may be confined to one or two planes, necessitating multiplanar images to determine the full extent of the lesion.

Here we describe a case of 360-degree cervico-dorsal fixation in a single posterior approach following D1, D2 spondylectomy.

Case Report

History and Examination

A 19 years old male with no significant past history presented with neck pain for 9 months, tingling & numbness of right upper limb along with progressive muscle wasting and weakness for 3 months, lower limb weakness for 1 month. He has no history of bowel & bladder dysfunction, trauma, fever, night pain, cough, shortness of breath, hemoptysis, weight loss.

On neurological examination, cranial nerves were intact and normal cerebellar function with spastic gait. Examination of Right upper limb revealed reduced bulk & tone with muscle power MRC grade 4 in all groups with diminished deep tendon reflexes. But, Left upper limb examination revealed normal findings.

Examination of both lower limbs revealed, bilateral increased muscle tone, power was 4 in all group of muscles, knee & ankle jerk exaggerated, planter extensor but, both ankle and patellar clonus were absent. Sensory examination findings were bizarre. Local examination of spine revealed no abnormality.

General other systemic examination findings were unremarkable.

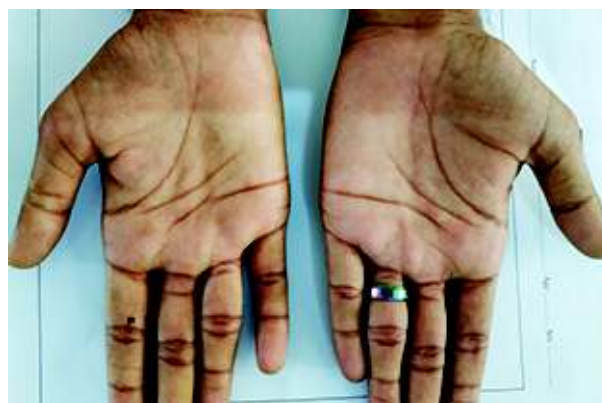

Fig.-1: Gross wasting of right thenar and hypothenar muscles

Investigation

MRI of cervical (Figure-2) spine shows enhancing expansile mass involving D1, D2 and part of C7 vertebrae with marked spinal canal stenosis with right sided corresponding exiting roots compression with cervico-dorsal subluxation (D/D: Giant cell tumor, Aneurysmal Bone Cyst).

CT scan of cervico-dorsal junction (Figure-3) revealed an osteolytic lesion involving right side of D1, D2 vertebral bodies with their posterior elements and adjacent part of right 1st and 2nd ribs with part of right C7 lateral mass. Cervico-Dorsal subluxation can also be appreciated here.

Surgery

He underwent D1-D2 spondylectomy followed by D1-D2 reconstruction by expandable titanium cage, fixation & stabilization of C5, C6 (both side), C7 (left) lateral mass screw & D3, D4 pedicle screw & rod connected by domino connector (Figure-4).

A midline incision was made from C3 to D6 vertebra. Dissection was carried out laterally to expose lateral masses of C5, C6, and C7. In dorsal spine, we dissected laterally to expose costo-transverse joints of D1 and D2 vertebrae on right side and transverse processes on left side. Initially we removed posterior

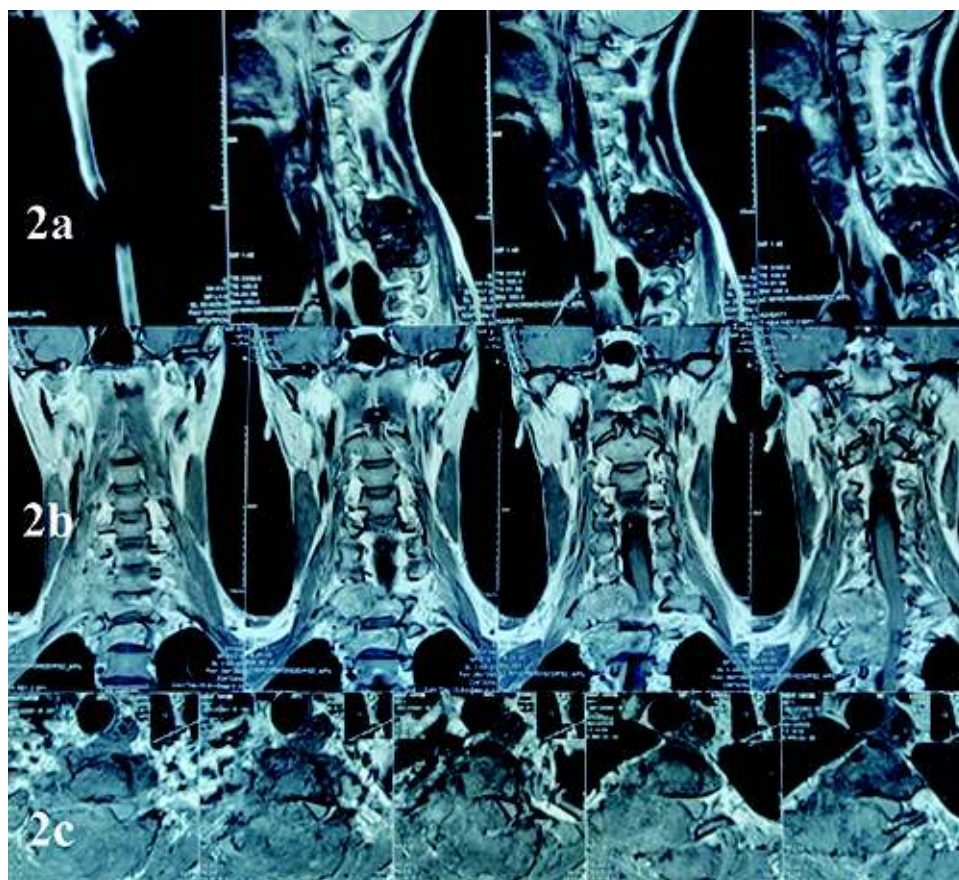

Fig.-2: Pre-operative MRI 2a. Multiple sagittal sections with MR myelogram showing extent of vertebral involvement and dural tube compression, 2b. Post-contrast Coronal sections showing heterogeneous contrast uptake and involvement of vertebra is more on the right side and cord is pushed towards left, 2c. Post-contrast axial sections showing spinal canal stenosis and cord is compressed and pushed anteriorly and to the left.

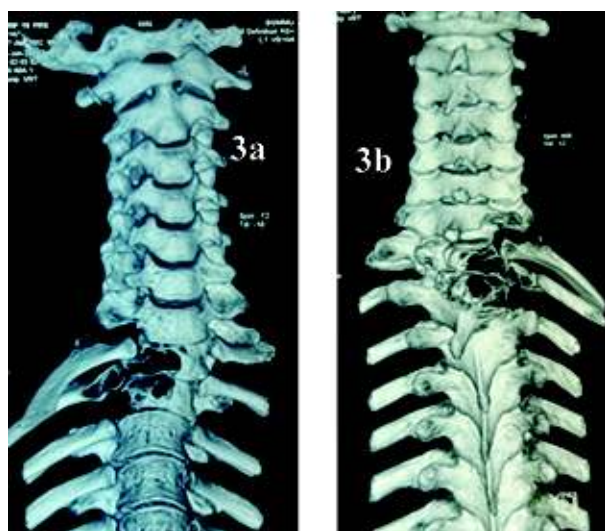


Fig.-3: 3D reconstruction of CT scan of cervico-dorsal junction 3a. Anterior view, 3b. Posterior view.

portion of expansile bone mass with rongeurs. Then dural tube along with right C7, D1, D2 nerve roots were dissected from the lesion. Involved portion of right 1st and 2nd ribs were also removed. Then we dissected dural tube anteriorly. Involved portion of D1, D2 bodies along with their right pedicles were removed. But, healthy portion on the left side of their bodies was left alone. Then we prepared the field for reconstruction by removing end plates of D3 and C7 vertebrae. We inserted lateral mass screws at left C5, C6, C7 vertebrae and pedicle screws at left D3, D4 vertebrae. On the right side C5, C6 lateral mass screws and D3, D4 pedicle screws were inserted. Cervico-dorsal fixation and stabilization was done on left side with rods connected by domino connector. Then self-expandable titanium mesh cage was implanted in between C7 and D1 nerve roots from right side. After adequate expansion of the cage we checked the

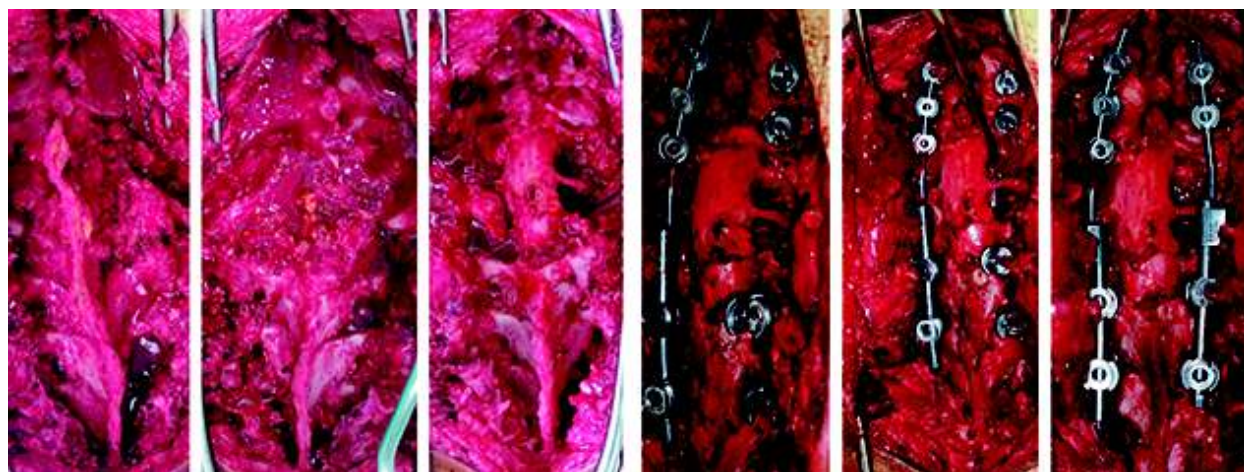

Fig.-4: pictures at various stages of the operation, 4a. Just after exposure of the lesion, 4b. After partial debulking yellowish blood degradation products can be appreciated, 4c. After decompression of neuronal structures 4d. Screws and left rods with domino connector can be seen here 4e. Self-expandable titanium mesh cage has been inserted in-between right C7 and D1 nerve roots 4f. Also right rods with domino connector has been implanted.

correction of cervico-dorsal subluxation and implant position with C-arm. Then cervico-dorsal fixation on the right side was done with rods connected by domino connector. After ensuring proper hemostasis wound was closed in layers with a drain tube in situ.

Postoperative Course

Patient's post-operative recovery was uneventful. Stitches were removed on 12th post-operative day.

Neck pain subsided, spasticity resolved & muscle power improved with no residual neurological deficit. Post-operative radiological images (Figure-5) shows correction of cervico-dorsal dislocation and confirms well position of all implants. But unfortunately histopathology from multiple centers could not give any definitive diagnosis.

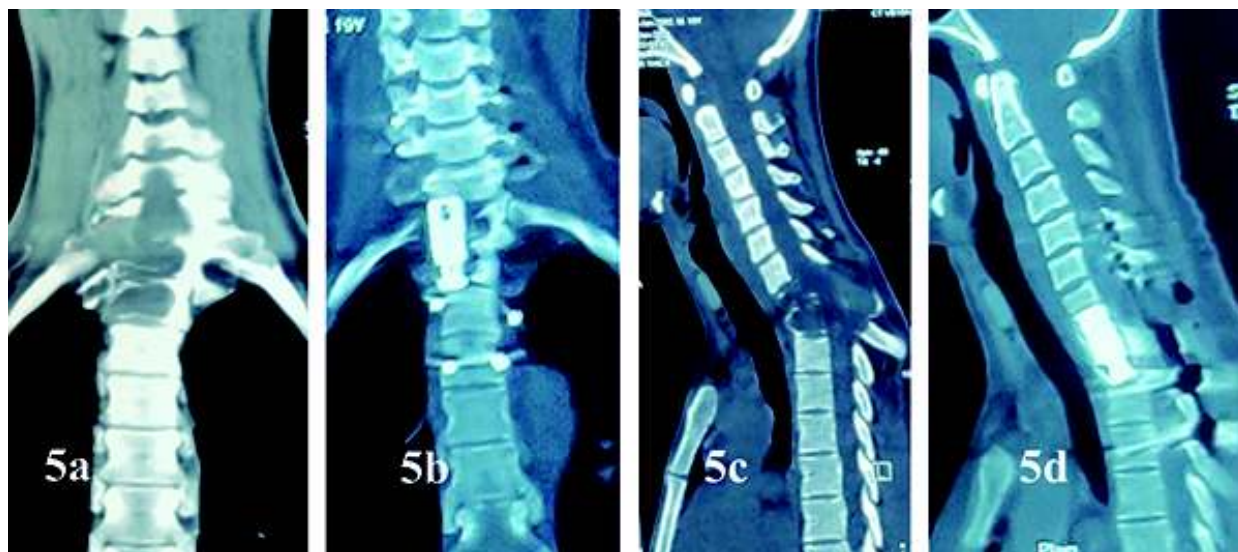

Fig.-5: 5a-preoperative and 5b-postoperative coronal reconstruction of CT scan; 5c-preoperative and 5d-postoperative sagittal reconstructions of CT scan. In sagittal reconstruction, correction of cervico-dorsal subluxation can be appreciated.

Discussion:

Exposure of the cervicothoracic junction continues to be a challenge in spinal surgeries. With bony structures including the sternum, clavicles and ribs in the front and large vessels, the thoracic duct and important nerves nearby, it is difficult to expose the cervicothoracic junction anteriorly, and the procedure is accompanied with high risks. Meanwhile, patient suffering from cervicothoracic mass lesions is usually complicated with regional kyphosis caused by bony structure destruction, which presents a further challenge to the surgeons⁴⁻⁸. As a result, for patients with cervicothoracic SOL, it is essential to individualize specific surgical approaches based on the location of lesions to obtain optimal exposure and maximize safety for the patients.

The conventional anterior cervical approach is the simplest one, inflicting minimal damage to adjacent structures, and thus yields early patient recovery. The procedure is capable of exposing down to the T1-T2 segments. However, in regard to the T3 segment diseases or surgeries that involve stabilization down to the T3 segment, the approach may not provide sufficient exposure. Other approaches may obtain optimal T3 segment exposure, but the procedures themselves are complicated and patients suffer from high morbidity and high risk of mediastinal infections, bone defects and nonunion, which to a great extent impair the therapeutic effect of the surgery^{9,10}.

Sharan et al¹¹ revealed that the T1-T2 disc could be visualized in its entirety above the suprasternal notch in 45.28% of patients but that the T2-T3 disc could be exposed only in 14.15% from a radiographic analysis. To expose the T3 vertebra, anterior approach with manubriotomy would be necessary in 80% to 85% cases¹¹⁻¹⁴.

For lesions involving the T3 vertebral body, it is possible to achieve debridement through conventional anterior cervical approach with or without partial manubriotomy, but internal fixation is impractical due to the blockade of nearby bony structures. In such cases, anterior approach for internal fixation requires full sternotomy, which demands high technical proficiency, leading to increased morbidity and extending the recovery time of the patient after surgery. However, approaching by resection of the manubrio-clavicular complex might induce shoulder girdle dysfunction⁴.

Combined, single-stage anterior-posterior approaches are associated with an increase of perioperative

morbidity, especially in patients with poor medical conditions due to cardiopulmonary diseases¹⁵. The efficacy and feasibility of a single-stage, circumferential spinal cord decompression via a solely posterior approach, as a less-invasive alternative procedure to standard combined anterior-posterior approaches¹⁶.

However, decompression and stabilization is indicated in patients with spinal metastases or nonpathological fractures who have high-grade epidural compression with or without neurological deficit and three-column instability. Metastatic spine tumors involve the vertebral body in 70%¹⁷ and a resection of more than 50% of the vertebral body diameter usually requires reconstruction of the body, as the main axial load is transmitted through the anterior column²⁰. Here, an anterior, transcostal approach is often favored because of excellent exposition and resection of the affected vertebral body¹⁹. Frequently the anterior approach has to be combined with posterolateral decompression in case of circumferential or dorsal epidural mass. Then a 360-degree decompression and fixation via a second dorsal approach might be required. Among many, the major disadvantage of a two-staged surgery is the higher morbidity due to longer operation time and increased blood loss¹⁸.

In most series similar to ours the decision for a single-stage posterolateral transpedicular approach with or without reconstruction of the ventral column based on the coexistence of poor medical conditions^{17,20}. Titanium mesh cages or expandable cages filled with bone or synthetic bone graft provide better ossification in terms of long-term survivor²¹. The most common complications resulting from posterior approaches are wound infections, with a range from 10 to 62%²⁰. Post-operative outcome of the patient is measured on VAS (Visual Analogue Scale) & ASIA (American Spinal Cord Injury Association) impairment scale.

Our technique holds some limitation: first, during a transpedicular approach the ventral dura may not be visualized. However, since the posterior longitudinal ligament (PLL) is often well palpable and separates the tumor from the anterior dura, epidural tumor rests after resection of the PLL are unlikely. Second, metastatic tumor does not often involve the dorsal elements of the spine¹⁷. The transpedicular approach creates a new route through tumor-free and viable spine elements. For this reason, the transpedicular procedure was only performed in case of pedicle involvement and therefore existing tumor manifestation in the dorsal column.

Conclusion:

It is technically difficult to properly place the cage strut into the intervertebral space. There is no convenient device for twisting, rotating, and properly placing a cage strut inside the intervertebral space. When needed, sacrificing T2 or T3 spinal nerves and widening the internervous space for insertion of a wider cage is allowable in selected cases. Single-stage technique represents a procedure, which allows a fast and save reconstitution/preservation of neurological function and biomechanical stable gross total resection. In conclusion, one-stage posterior 360° stabilization and vertebral body replacement is a useful technique for upper thoracic spine surgery.

References:

- Hsu LC, Leong JC. Tuberculosis of the lower cervical spine (C2 to C7). A report on 40 cases. *J Bone Joint Surg Br.* 1984;66(1):1–5. PMID:6693464
- Zhang HQ, Hu X, Yin X, Chen Y. One-stage combined anterior-posterior approach treatment of multiple cervicothoracic spinal tuberculosis with kyphosis. *IntOrthop.* 2015;39(8):1605–10. PMID:25913265
- Rajendra Kumar, Ruppert David, t Faustino C. Guinto, Jr.' Au Shirkhoda, 1 John E. Madewell, Expansile bone lesions of the vertebra. THE 73RD SCIENTIFIC ASSEMBLY AND ANNUAL MEETING OF THE RADIOLOGICAL SOCIETY OF NORTH AMERICA, NOVEMBER 29-DECEMBER 4. 1987. CHICAGO, ILLINOIS. IT WAS RECOMMENDED BY THE MUSCULOSKELETAL IMAGING PANEL AND WAS ACCEPTED FOR PUBLICATION AFTER PEER REVIEW ON MARCH 2, 1988.
- Darling GE, McBroom R, Perrin R. Modified anterior approach to the cervicothoracic junction. *Spine (Phila Pa 1976).* 1995;20(13):1519–21. PMID:8623074.
- Sar C, Hamzaoglu A, Talu U, Domanic U. An anterior approach to the cervicothoracic junction of the spine (modified osteotomy of manubrium sterni and clavicle). *J Spinal Disord.* 1999;12(2):102–6. PMID:10229522.
- Birch R, Bonney G, Marshall RW. A surgical approach to the cervicothoracic spine. *J Bone Joint Surg Br.* 1990;72(5):904–7. PMID:2211781.
- Tamura M, Saito M, Machida M, Shibasaki K. A transsternoclavicular approach for the anterior decompression and fusion of the upper thoracic spine. Technical note. *J Neurosurg Spine.* 2005;2(2):226–9. PMID:15739540.
- Pointillart V, Aurouer N, Gangnet N, Vital JM. Anterior approach to the cervicothoracic junction without sternotomy: a report of 37 cases. *Spine (Phila Pa 1976).* 2007;32(25):2875–9. PMID:18246011.
- Hu H, Winters HA, Paul RM, Wuisman PI. Internal thoracic vessels used as pedicle graft for anastomosis with vascularized bone graft to reconstruct C7-T3 spinal defects: a new technique. *Spine (Phila Pa 1976).* 2007;32(5):601–5. PMID:17334297.
- Prabhakar MM, Thakker T. Anterior decompression for cervicothoracic pathology: A study of 14 patients. *J Spinal Cord Med.* 2006;29(2):163–6. PMID:16739561;
- Sharan AD, Przybylski GJ, Tartaglino L. Approaching the upper thoracic vertebrae without sternotomy or thoracotomy: a radiographic analysis with clinical application. *Spine (Phila Pa 1976).* 2000;25(8):910–6. PMID:10767801.
- Kurz LT, Pursel SE, Herkowitz HN. Modified anterior approach to the cervicothoracic junction. *Spine (Phila Pa 1976).* 1991;16(10 Suppl):S542–7. PMID:1801269.
- An HS, Gordin R, Renner K. Anatomic considerations for plate-screw fixation of the cervical spine. *Spine (Phila Pa 1976).* 1991;16(10 Suppl):S548–51. PMID:1801270.
- Mihir B, Vinod L, Umesh M, Chaudhary K. Anterior instrumentation of the cervicothoracic vertebrae: approach based on clinical and radiologic criteria. *Spine (Phila Pa 1976).* 2006;31(9):E244–9. PMID:16641764.
- Sundaresan N, Steinberger AA, Moore F, Sachdev VP, Krol G, Hough L, Kelliher K. Indications and results of combined anterior-posterior approaches for spine tumor surgery. *J Neurosurg.* 1996;85:438–446. doi: 10.3171/jns.1996.85.3.0438. [PubMed] [CrossRef] [Google Scholar]
- Sven O. Eicker, Jan Frederik Cornelius, Hans-Jakob Steiger, and Daniel Hänggi *Eur Spine J.* 2012 Jun; 21(6): 1207–1213. Published online 2012 Jan 11. doi: 10.1007/s00586-012-2150-1 PMID: 22234723
- Bilsky MH, Boland P, Lis E, Raizer JJ, Healey JH. Single-stage posterolateral transpedicle approach for spondylectomy, epidural decompression, and circumferential fusion of spinal metastases. *Spine.* 2000;25:2240–2249. doi: 10.1097/00007632-200009010-00016.
- Esses SI, Botsford DJ, Kostuik JP. Evaluation of surgical treatment for burst fractures. *Spine.* 1990;15:667–673. doi: 10.1097/00007632-199007000-00010.
- Harrington KD. Anterior cord decompression and spinal stabilization for patients with metastatic lesions of the spine. *J Neurosurg.* 1984;61:107–117. doi: 10.3171/jns.1984.61.1.0107.
- Wang JC, Boland P, Mitra N, Yamada Y, Lis E, Stubblefield M, Bilsky MH. Single-stage posterolateral transpedicular approach for resection of epidural metastatic spine tumors involving the vertebral body with circumferential reconstruction: results in 140 patients. *J Neurosurg (Spine 1)* 2004;3:287–298. doi: 10.3171/spi.2004.1.3.0287
- Hofstetter CP, Chou D, Newman CB, Aryan HE, Girardi FP, Härtl R. Posterior approach for thoracolumbar corpectomies with expandable cage placement and circumferential arthrodesis: a multicentre case series of 67 patients. *J Neurosurg Spine.* 2011;14:388–397. doi: 10.3171/2010.11.SPINE09956.