

## Case Report

# Management of Proptosis in a Case of Sphenoid-Orbital Meningioma

Rahman MM<sup>1</sup>, Khan RA<sup>2</sup>, Arifin MS<sup>3</sup>, Khan SIMKN<sup>4</sup>, Chowdhury M<sup>5</sup>

**Conflict of Interest:** There is no conflict of interest relevant to this paper to disclose.

**Funding Agency:** Was not funded by any institute or any group.

**Contribution of Author:** Principal Investigator- Dr. Md. Moshir Rahman,

**Manuscript Preparation:** Dr. Robert Ahmed Khan, Dr. Mohammad Samsul Arifin,

**Data Collection-** Dr. Muhtamim Chowdhury

**Editorial Formatting:** Dr. SIM Khairun Nabi Khan

**Copyright:** ©2021 bang.BJNS published by BSNS. This published by BJNS. This article is published under the creative commons CC-BY-NC license. This license permits use distribution (<http://creativecommons.org/licenses/by-nc/4.0/>) reproduction in any medium, provided the original work is properly cited and is not used for commercial purposes.

**Received:** 13 June, 2022

**Accepted:** 17 August, 2022

### Abstract:

*Sphenoid-orbital meningiomas (SOMs) are difficult to completely resect because they involve the sphenoid wing, orbit, and cavernous sinus. As the tumor invades the optic canal, SOMs frequently appear with visual deficits. The authors of this case report dealt with the case of a 65-year-old male patient who had right-sided proptosis. We diagnosed the patient, and his MRI revealed of having SOMs. The surgical approach was determined by the tumor's placement in the orbit and cranial cavity and its connections to the optic canal and optic nerve axis. Surgical excision was used to successfully remove the SOM. The patient maintained a proptosis of less than 4 mm during the follow-up period. The visual acuity, visual field, and ocular fundus were examined during the optical follow-up. SOMs are notoriously difficult to treat surgically. The primary goal of surgery in symptomatic individuals with SOMs is to slow down the tumor's progression. Longer periods of post-operative observation and follow-up are recommended to observe long-term advantages.*

**Key words:** Proptosis, Sphenoid-Orbital Meningioma, Visual deterioration.

*Bang. J Neurosurgery 2022; 11(2): 145-149*

### Introduction:

Meningiomas of the sphenoid ridge with considerable tumor extension into the orbit are known as sphenoid-orbital meningiomas. SOMs are slow-growing, complicated tumors that account for up to 9% of intracranial meningiomas<sup>1</sup>. The optic canal, superior orbital fissure, or lateral orbital wall may all be involved<sup>2</sup>. SOMs have distinct clinical and anatomical characteristics. The soft-tissue component can affect extracranial compartments, such as the orbit and its contents. The usual clinical symptoms seen in individuals with SOMs, such as proptosis, cranial

nerve palsy, and visual impairment, are caused by these intraosseous, intraorbital, and intradural alterations<sup>3,4</sup>. Visual impairment, proptosis, and aesthetic deformity are the most common signs and symptoms of SOMs. Even though proptosis is the most common clinical sign, visual acuity is reduced in 40–60% of cases<sup>3,5</sup>. It is mostly caused by tumor invasion of the optic canal, with the intraorbital tumor appearing to be less prominent. As a result, surgical management of optic canal invasion is critical for visual success. SOM resection generally necessitates considerable extradural and intradural surgery, as well

1. Dr. Md. Moshir Rahman, Assistant Professor, Department of Neurosurgery, Holy Family Red Crescent Medical College

2. Dr. Robert Ahmed Khan, Medical Officer, Department of Neurosurgery, BSMMU

3. Dr. SIM Khairun Nabi Khan, Associate Professor, Department of Neurosurgery, BSMMU

4. Dr. Mohammad Samsul Arifin, Medical Officer, Department of Neurosurgery, National Institute of Neurosciences and Hospital

5. Dr. Muhtamim Chowdhury, Department of Neurosurgery, Bangladesh Medical College

**Address of Correspondence:** Md. Moshir Rahman, Assistant Professor, Department of Neurosurgery, Holy Family Red Crescent Medical College, Dhaka. Mobile: 01713365274, E-mail: [dr.tutul@yahoo.com](mailto:dr.tutul@yahoo.com)

as substantial sphenoidal and orbital bone resections. The surgical removal of these tumors is linked with a high rate of morbidity and death of up to 6%<sup>5</sup>. The reported case involves a remarkable SOM in a 65-year-old male patient with right-sided proptosis.

#### Case presentation:

This case report presents a 65-year-old male patient who presented with right-sided proptosis and was later diagnosed with sphenoid-orbital Meningioma. We used computed tomography (CT) and magnetic resonance

imaging (MRI) to examine the patient's images (MRI). According to a routine diagnosis, the right eyeball was unilaterally proptosed (Figure 1). The tumor's depression in the temporal lobe was measured to be 4.5 cm in diameter from front to back. The meningioma occupied the left orbit, causing the right eyeball to be displaced anteriorly and the right optic nerve stretched. When comparing the damaged right optic nerve to the normal left optic nerve, histological cross-sections revealed decreased cellularity, axon loss, and greater connective tissue deposits in the affected right optic

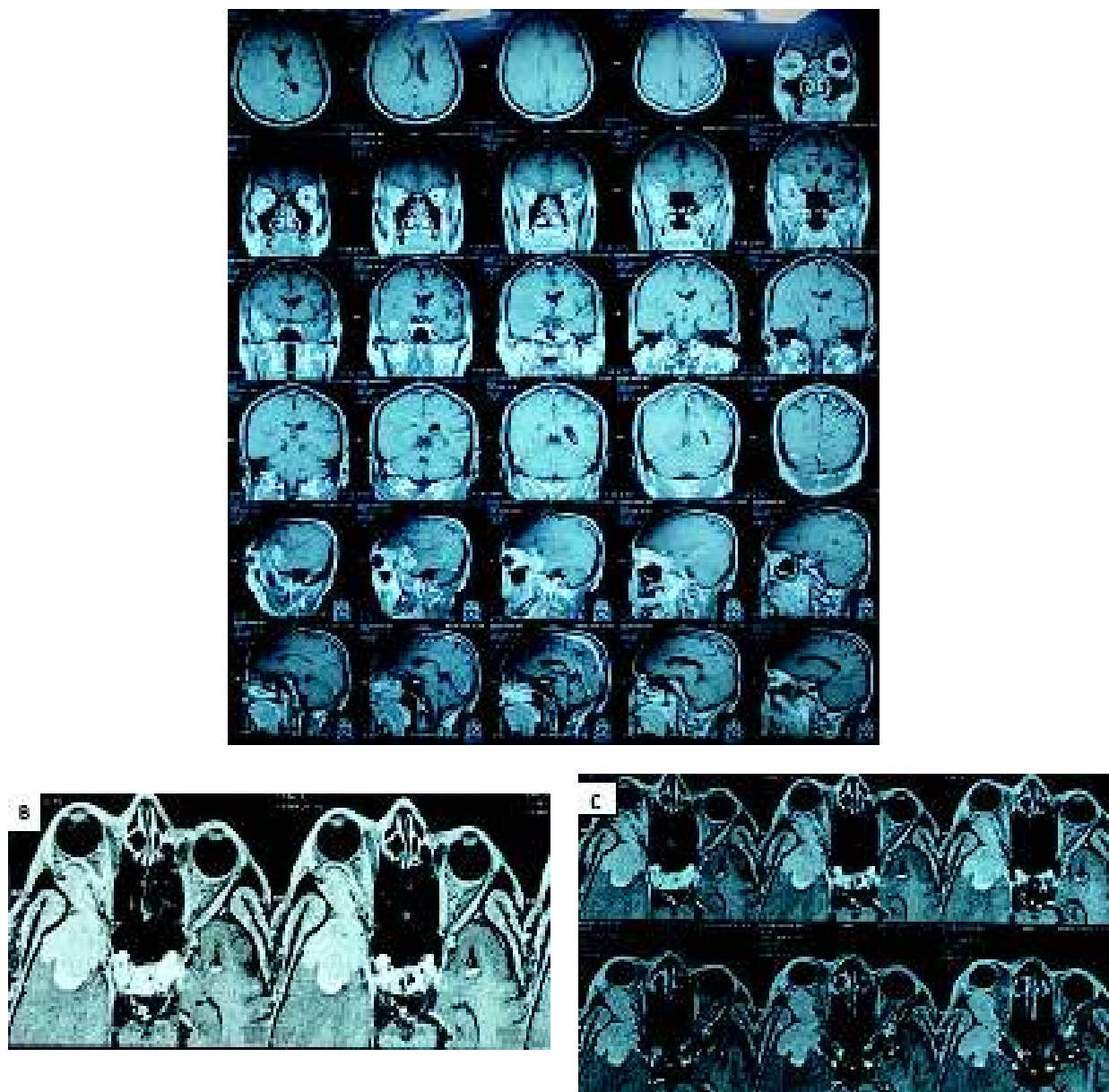
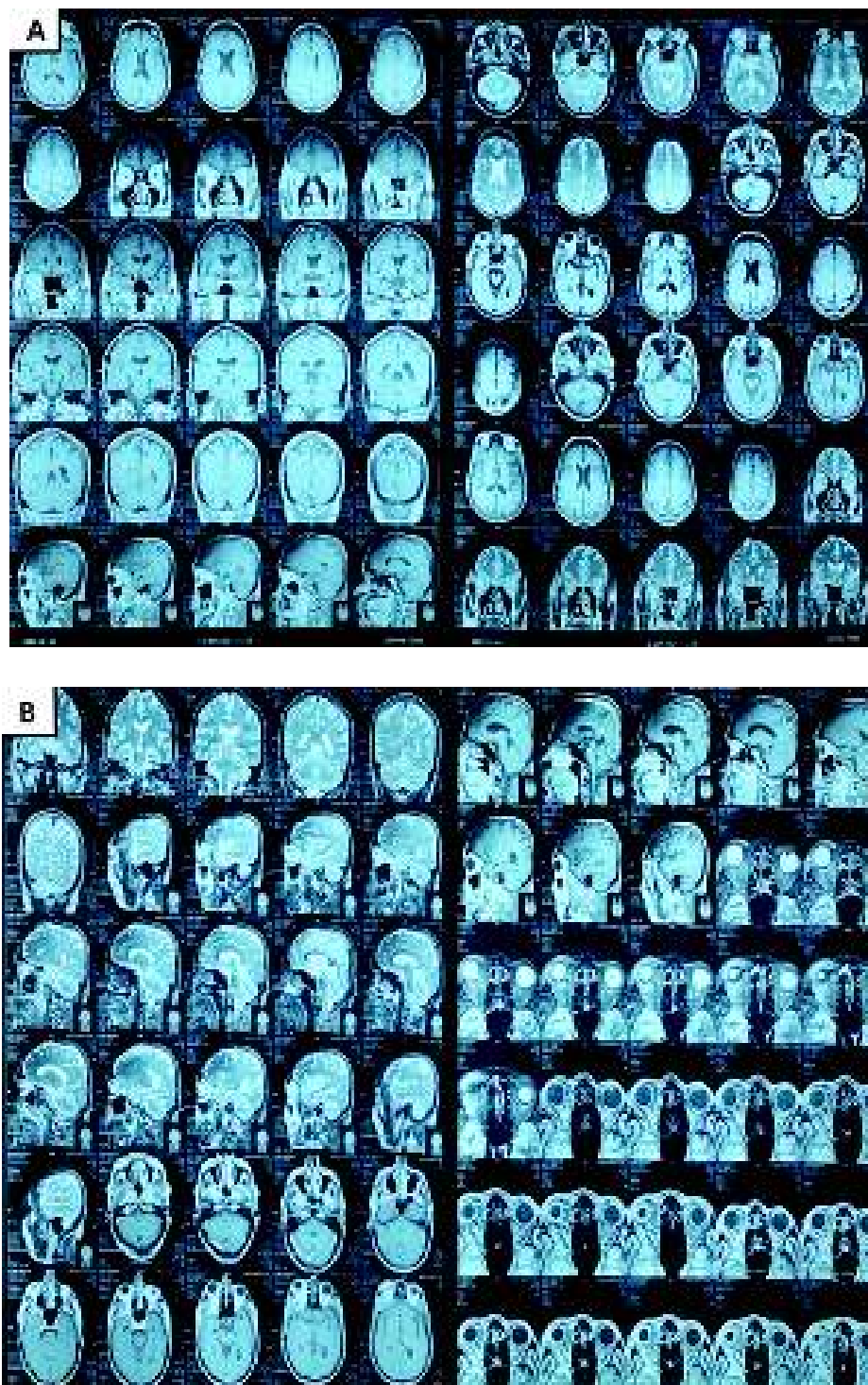


Fig.-1 (A-C): Preoperative MRI of Brain of the patient.

nerve. In addition, the central retinal artery walls in the right optic nerve seemed acellular compared to those on the left. The surgical approach was determined by the tumor's placement in the orbit and cranial cavity and its connections to the optic canal

and optic nerve axis. We conduct additional evaluation on the patient and prepared him for surgery. Surgical excision was used to successfully remove the SOM. The following were the postoperative controls: the patient maintained a proptosis of less than 4 mm (Figure 2). The visual follow-up included tests of visual



**Fig.-2 (A, B): Postoperative MRI of Brain of the patient.**

acuity, visual field, and ocular fundus at 3 months, one year, and subsequently every year.

### Discussion:

The SOM in this case study took up residence in both the right skull and orbit, squeezing the temporal and frontal lobes, thickening the optic nerve sheath, and reducing the number of axons in the optic nerve. Most meningiomas are believed to begin intracranially in the central nervous system, with the parasagittal and falx areas (25%), convexities of the brain parenchyma (20%), and the sphenoid ridge (20%) being the most prevalent places<sup>6</sup>.

This case report's histological study and the neoplasm's dural confinement support its classification as a spheno-orbital meningioma. These tumors can penetrate the skull via the dura in 25% to 50% of instances, causing overproduction, erosion, or penetration of the bone<sup>7</sup>.

Meningiomas can cause headaches and seizures in any location, with epileptic seizures being reported as the first symptom in 20% to 50% of patients<sup>6</sup>. Disfiguring proptosis, poor visual acuity, orbital discomfort, weeping, diplopia, and eyelid edema are common in patients with SOMs<sup>8</sup>. Patients with a lateral sphenoid wing meningioma have experienced painless unilateral exophthalmos, unilateral loss of vision, and unilateral hearing loss<sup>8</sup>. The patient in this case report had proptosis (Figure 1) and had visual abnormalities in the right eye as a result of stretching and compression of the optic nerve, as evidenced by the loss of axons (Figure 1).

Because of its location and size, this tumor is of considerable interest. At the last follow-up in our study, the patient's degree of proptosis had decreased by 4 mm as a result of the operation. At a mean follow-up of 5 years, research found a 96% improvement in proptosis following surgery for SOMs, although no exophthalmometry data were given<sup>4</sup>. Magill et al. looked at the correlations between the location, size, and WHO grade of meningiomas in 1,113 individuals<sup>9</sup>. The median tumor size was 3.6 cm, and the mean tumor size was 3.8 cm among the 1,113 meningiomas<sup>9</sup>.

Surgery is the most common treatment for SOMs. Complete excision is the desired surgical goal;

however it might be difficult to achieve. According to a study, the majority of patients are cured with excision alone<sup>7</sup>. Excision usually entails the removal of the tumor, dural attachment, and any infiltrated bone, as well as a histological diagnosis that will guide future treatment. Radiotherapy and hormone therapy are further treatment options, but they are usually reserved for atypical, malignant, or recurring meningiomas<sup>10</sup>. Cannon et al. looked at 12 individuals who had SOMs removed using a multimodal surgical approach<sup>11</sup>. 75% of patients had their proptosis reduced or stabilized after surgery, although visual acuity results were varied<sup>11</sup>. SOMs can increase the risks of surgical intervention, so each case should be thoroughly investigated.

### Conclusion:

Meningiomas are treated primarily with surgical excision, resulting in complete resection and symptom relief. The procedure is challenging to conduct, and the goal of surgery in symptomatic SOM patients is to slow down the tumor's growth. Post-operative observation and follow-up should be done for longer lengths of time. New findings should be reported to add to the current knowledge base and better understand the SOM behavior.

### References:

1. De Jesus O, Toledo MM. Surgical management of meningioma en plaque of the sphenoid ridge. *Surg Neurol*. 2001;55(5):265–269. doi:10.1016/s0090-3019(01)00440-2.
2. Mariniello G, Bonavolontà G, Tranfa F, Maiuri F. Management of the optic canal invasion and visual outcome in sphenoid-orbital meningiomas. *Clin Neurol Neurosurg*. 2013;115(9):1615–1620. doi:10.1016/j.clineuro.2013.02.012.
3. Ringel F, Cedzich C, Schramm J. Microsurgical technique and results of a series of 63 sphenoid-orbital meningiomas. *Neurosurgery*. 2007;60(4 Suppl 2):214–221. discussion 221–212. doi:10.1227/01.NEU.0000255415.47937.1A.
4. Shrivastava RK, Sen C, Costantino PD, Della Rocca R. Sphenoid-orbital meningiomas: surgical limitations and lessons learned in their long-term management. *J Neurosurg*. 2005;103(3):491–497. doi:10.3171/jns.2005.103.3.0491.
5. Mariniello G, Maiuri F, Strianese D, Donzelli R, Iuliano A, Tranfa F, et al. Sphenoid-orbital meningiomas: surgical approaches and outcome according to the intraorbital tumor extent. *Zentralblatt für Neurochirurgie* 2008;69:175–81.
6. Kaiser AE, Reddy SV, Von Zimmerman MA, Gordon A, Liuzzi FJ. Gross and Histological Examination of a Large Sphenoid-Orbital Meningioma. *Cureus*. 2020;12(9):e10256. Published 2020 Sep 5. doi:10.7759/cureus.10256

7. Di Cristofori A, Del Bene M, Locatelli M, Boggio F, Ercoli G, Ferrero S, Del Gobbo A: Meningioma and bone hyperostosis: expression of bone stimulating factors and review of the literature. *World Neurosurg.* 2018, 115:e774-e781. 10.1016/j.wneu.2018.04.176
8. Mourits MP, van der Sprenkel JWB: Orbital meningioma, the Utrecht experience . *Orbit.* 2001, 20:25-33. 10.1076/orbi.20.1.25.2640
9. Magill ST, Young JS, Chae R, Aghi MK, Theodosopoulos PV, McDermott MW: Relationship between tumor location, size, and WHO grade in meningioma. *Neurosurg Focus.* 2018, 44:E4. 10.3171/2018.1.FOCUS17752
10. Marosi C, Hassler M, Roessler K, Reni M, Sant M, Mazza E, Vecht C: Meningioma. *Crit Rev Oncol Hematol.* 2008, 67:153-171. 10.1016/j.critrevonc.2008.01.010
11. Cannon PS, Rutherford SA, Richardson PL, King A, Leatherbarrow B: The surgical management and outcomes for spheno-orbital meningiomas: A 7-year review of multidisciplinary practice. *Orbit.* 2009, 28:371-376. 10.3109/01676830903104645