

Original Article

Correlation between Perfusion-Weighted Magnetic Resonance Imaging (MRI) Features with Histopathological Grading of Glioma

Hojaifa¹, Rahman MA², Raihan MF³, Bari S⁴, Alam F⁵, Hossain ATMH⁶, Hasan MM⁷, Hossain ABMM⁸, Asaduzzaman SM⁹, Hossain M¹⁰

Conflict of interest: There is no Conflict of interest relevant to this paper to disclose.

Funding Agency: Was not funded by any institute or any group.

Contribution of Authors: Principal Investigator- Dr. Hojaifa,

Manuscript preparation- Dr. Md Atikur Rahman, Dr. Md Farid Raihan, Dr. Md Shahnawaz Bari

Data collection- Dr. Farzana Alam, Dr. KH. Olinur Razib, Dr. A.B.M. Manwar Hossain, Dr. S.M. Asaduzzaman

Editorial formatting- Prof. ATM Mosharef Hossain, Dr. Md. Motasimul Hasan

Copyright: @2022bang. BJNS published by BSNS. This article is published under the creative commons CC-BY-NC license. This license permits use distribution (<https://creativecommons.org/licenses/by-nc/4-0/>) reproduction in any medium, provided the original work is properly cited and is not used for commercial purposes.

Received: 30 July, 2022

Accepted: 27 September, 2022

Abstract:

Background: Gliomas are the most common primary neoplasm of the brain. It histopathologically grades I to IV. I and II are low grade while III, IV are high grade. Low-grade gliomas are usually subject to either strict follow-up or surgery. The treatment for high grade gliomas is typically surgery, followed by concomitant radiation therapy and chemotherapy. Conventional MRI has limitations for the grading of gliomas. In addition to conventional MRI techniques, a variety of new techniques such as perfusion-weighted MRI which noninvasively measures cerebral perfusion that can be used for better assessment of glioma. This will be helpful for therapeutic approach and counseling about prognosis of the patient.

Methods: This cross sectional observational study was conducted in the Department of Neurosurgery, Bangabandhu Sheikh Mujib Medical University from IRB clearance to 18 months. The patients who fulfill the selection criteria were enrolled in this study. Written informed consent was taken from the patients and/or the legal guardian/responsible family members after completely explaining to them the procedure and the purpose of the study. Patient's data was collected in questionnaire/data collection sheet. The privacy of the patient was strictly maintained and the patient's information will not be disclosed to any source. The study data will only be used for the purpose of this scientific study. This study was not causing any additional harm to the patients. All the patients were evaluated by a standard conventional contrast-enhanced study with perfusion-weighted image on Siemens 3 Tesla MRI. The histopathological grading of the tumor was done as per the WHO classification of 2007. Then correlation was done between PWI finding and WHO histopathological grading.

Results: Measurement of relative cerebral blood volume in glioma patients was done in PW-MRI preoperatively. Out of the 35 tumors evaluated, 17 were found as low rCBV and 18 as high. Histopathological examination of glioma was done postoperatively. Among 35 tumors, 19 are low grade gliomas and 16 are high grade gliomas. For the correlation between relative cerebral blood volume in preoperative PW MRI and histopathological grading of glioma, Spearman's Rank Correlation Coefficient Test was done. We found a significant positive coefficient value of $r = 0.572$ with a significant p -value of $p = <0.001$. A single cutoff relative cerebral blood volume value of 1.7 for low versus high grade glioma was found to be 77.8% sensitive and 88.2% specific.

Conclusion: The present study ascertains that histopathological grading of glioma is positively correlated with relative cerebral blood volume in PW MRI.

Bang. J Neurosurgery 2022; 12(1): 12-19

Introduction

Gliomas are the most common primary neoplasm of the brain. The term glioma was first used by Virchow

as he described the neuroglia as the interstitial matrix of the brain in which the individual cells are suspended. Glioma is the general name for the

1. Dr. Hojaifa, Medical Officer, Neurosurgery Department, Dhaka Medical College, Dhaka
2. Dr. Md. Atikur Rahman, Associate Professor, Neurosurgery Department, Bangabandhu Sheikh Mujib Medical University, Shahbag Dhaka
3. Dr. Md. Farid Raihan, Medical Officer, Neurosurgery Department, Bangabandhu Sheikh Mujib Medical University, Shahbag Dhaka
4. Dr. Md. Shahnawaz Bari, Assistant Professor, Neurosurgery Department, Bangabandhu Sheikh Mujib Medical University, Shahbag Dhaka
5. Dr. Farzana Alam, Radiology and Imaging Department, Bangabandhu Sheikh Mujib Medical University, Shahbag Dhaka
6. Prof. ATM Mosharef Hossain, Ex Professor and Chairman, Neurosurgery Department, Bangabandhu Sheikh Mujib Medical University, Shahbag Dhaka
7. Dr. Md. Motasimul Hasan, Assistant Professor, Dept. of Neurosurgery, Dhaka Medical College, Dhaka.
8. Dr. ABM Manwar Hossain, Medical Officer, Dept. of Neurosurgery, BSMMU, Dhaka.
9. Dr. SM Asaduzzaman, Assistant Professor, Dept. of Neurosurgery, SOMC, Sylhet.
10. Prof. Mohammad Hossain, Professor, Dept. of Neurosurgery, BSMMU, Dhaka.

Address of Correspondent: Dr. Hojaifa, Medical Officer, Neurosurgery Department, Dhaka Medical College, Dhaka, Mob-01714476633, Email: hojaifadjmc

tumors that arise from the glial cells of the brain. Gliomas account for nearly 30% of all brain and central nervous system tumors and 80% of all malignant brain tumors¹.

In the CNS neurons are supported by several varieties of non-excitabile cells, which together are called neuroglia. Neuroglial cells are generally smaller than neurons and outnumber them by 5-10 times². The neuroglial cells have an enormous potential for abnormal growth and are the chief source of CNS neoplasm. Tumors believed to be originating from neuroglial cells are known as Glioma³.

The annual incidence of gliomas is 5-10 cases per 100,000 in Western populations. They are the leading cause of death among children and adults diagnosed with brain neoplasm. Gliomas are valued at the WHO classification by histopathological grades I to IV. Grades I and II are considered low-grade, while III, IV grades are high grade. Although they are histologically benign tumors most of II grade will transform into malignant grades III and IV in the range of 5-10 years of diagnosis⁴.

These grades are important because, they define therapeutic approach and prognosis in patients with gliomas. Low-grade gliomas are usually subject to either strict follow-up or surgery. The treatment for high grade gliomas is typically surgery, followed by concomitant radiation therapy and chemotherapy¹.

Grade1 tumors are generally benign and frequently curable with complete surgical resection, occur primarily in children and are believed to represent an entity separate from grade II-IV (seen primarily in adults). Adult grade II tumors (Low Grade Gliomas (LGG) include: 1) astrocytomas, 2) oligo-astrocytomas or mixed gliomas, and 3) oligodendrogliomas. Astrocytomas and oligodendrogliomas consist of astrocytes or oligodendrocytes, respectively⁵.

Mixed gliomas contain a mixture of the two cell types. Essentially all Grade II lesions eventually progress to High Grade Glioma (grade III/IV or HGG). Grade IV tumors (aka glioblastoma (GBM)) that arise from LGG are termed "secondary GBM" to differentiate them from "primary" or "de-novo" GBM as the pathway leading to these two GBM types differs by a number of genetic abnormalities and clinical characteristics⁶.

High grade gliomas include anaplastic astrocytoma (Grade III astrocytoma), anaplastic oligodendroglioma (Grade III oligodendroglioma), and glioblastoma multiforme (GBM, Grade IV astrocytoma)⁷.

Greater infiltrative potential of high grade glioma cells have been supported by studies demonstrating that high grade glioma cells travel faster compared to low grade glioma cells along extracellular matrix and proteins⁸.

Glioblastomas are divided in the 2016 CNS WHO into glioblastoma, IDH-wild type (about 90 % of cases), which corresponds most frequently with the clinically defined primary or de novo glioblastoma and predominates in patients over 55 years of age⁹.

Glioblastoma, IDH-mutant (about 10 % of cases), which corresponds closely to so called secondary glioblastoma with a history of prior lower grade diffuse glioma and preferentially arises in younger Patients⁹.

Aggressiveness of glioma is mainly determined by its ability to infiltrate the brain parenchyma and to recruit, synthesize, and proliferate vascular networks for further growth¹⁰.

Inaccurate grading represents a risk for the patient, since it could lead to an inappropriate therapy. Conventional histopathologic diagnosis has significant limitations: It is an invasive procedure that has inherent sampling error, especially for difficult-to-access tumors amenable only to stereotactic biopsy, Inter-observer variability and inability to evaluate residual tumor tissue after surgery¹.

MRI is a useful noninvasive imaging method for tissue characterization and glioma grading. Conventional MRI offers information on mass effect, edema, enhancement, and necrosis that can be used to estimate tumor grade. However, it has limitations for the grading of gliomas¹.

The usual presentation of gliomas on MRI scans include hypo or iso intensity on T1W imaging and hyperintensity on T2W imaging. There may be surrounding vasogenic edema, necrotic areas, and distortion of adjacent structures¹¹.

Imaging characteristics such as degree of contrast area, tumor necrosis volume, and edema surrounding tumor have been well identified as prognostic markers in high grade lesion^{12,13}.

However, often a high-grade glioma may be mistaken for a low-grade glioma when it demonstrates minimal edema, no contrast material enhancement, no necrosis, and no mass effect. Conversely, low-grade gliomas can sometimes demonstrate peritumoral edema, contrast material enhancement, central necrosis, and mass effect and be mistaken for a high-grade glioma¹¹.

The use of gadolinium-based contrast agents shows further improvement in the demonstration and detection of cerebral gliomas. Patterns and extent of contrast enhancement have been suggestive of a malignant potential. However, this approach is limited because 14–45% of non-enhancing supratentorial gliomas are malignant (especially in older patients) and some enhancing gliomas (i.e. pilocytic astrocytoma) are benign¹⁴.

Upadhyay, N., and Waldman, A. D (2011) stated that up to one-third of non-enhancing gliomas are malignant. Certain subtypes of LGGs, notably gangliogliomas and pilocytic astrocytomas, some grade II oligodendrogliomas and more rarely, low-grade astrocytomas show enhancement. Contrast enhancement alone is therefore a limited differentiator between high-grade gliomas and LGGs in an individual patient.

In addition to conventional MRI techniques, a variety of new techniques have found their place in clinical practice. These new techniques offer more than the anatomic information provided by the conventional MRI sequences. Two of the new MRI techniques include perfusion weighted imaging (PWI) and diffusion weighted imaging (DWI)¹⁵. Diffusion-weighted imaging (DWI) is a physiologic imaging modality that exploits the diffusion of water molecules to create contrast between tissues¹⁶.

Diffusion is the random walk of water molecules in the extracellular extra-vascular space. First application of diffusion imaging was stroke but was soon adopted in oncologic patients as it provides information on cellularity, water content, tissue integrity or changes in its architecture¹⁵.

Currently, DWI is used primarily in the diagnosis of intracranial abscesses, infarcts, and epidermoid cysts¹⁵.

Perfusion-weighted imaging (PWI) is an MRI modality that gives insights into the delivery of blood to tissues by monitoring a bolus of contrast agent as it passes through the blood vasculature. A common biomarker derived from PWI is the relative cerebral blood volume (rCBV). Measurements of rCBV have been shown to be higher in high grade tumors than in low-grade tumors and may correlate with glioma vascularity¹⁶.

Perfusion MR imaging noninvasively measures cerebral perfusion via the assessment of various hemodynamic measurements, such as cerebral blood volume, cerebral blood flow, and mean transit time. MR imaging measurements of tumor hemodynamics are potentially useful in characterizing tumors because tumor aggressiveness and growth are associated with both endothelial hyperplasia and endothelial neovascularization¹¹.

In addition to increased vascularity in tumors, new vessels and damaged mature vessels are permeable to contrast agents, unlike vessels in normal brain. Various studies have shown that relative cerebral blood volume (rCBV) maps and measurements have been shown to correlate reliably with tumor grade and histologic findings of increased tumor vascularity¹¹.

Relative cerebral blood volume (rCBV) maps gives idea about the qualitative and quantitative assessment of tumour vascularity¹⁴.

PWI is mainly utilized in tumors to find the extent of neovascularization, capillary density and in infarcts to assess the ischemic zones¹⁵.

There are very few studies which attempt to correlate the histopathological grade of the tumor with the findings of perfusion weighted MRI. The aim of the current study is to assess the same and find if perfusion weighted MRI can be used for better assessment of glioma grade which is helpful for therapeutic approach and counselling about prognosis of the patient.

This study presents the best possibility of accurate grading of glioma in the preoperative time, allowing us to select the most appropriate therapeutic management for the patients.

The discrimination of tumor boundaries from normal tissue or vasogenic edema, as well as the evaluation of tissue heterogeneity and tumor grading are often a challenge in conventional MR imaging. Thus, it would be of interest to have a noninvasive, objective and reproducible method for improving the assessment of glioma, as well as the planning of surgery and radiation therapy.

Objective: objective of this study is to assess the correlation between PW (perfusion-weighted) MRI of brain with histopathological grade of glioma

Methods:

It was a a cross sectional experimental study which was studying in the department of Neurosurgery, Bangabandhu Sheikh Mujib Medical University (BSMMU), Shahbag, Dhaka within July 2019-December 2020. The study population was included all patients diagnosed as gliomas , with PWI in addition to conventional MRI of brain with contrast undergoing surgery, in the Department of Neurosurgery, Bangabandhu Sheikh Mujib Medical University, National institute of neurosciences and Dhaka medical college hospital. The total duration of data collection of the study was 18 months and the population size was roughly be estimated 36 (N). Patients with radiologically diagnosed as glioma, admitted in Neurosurgery Department, Bangabandhu Sheikh Mujib Medical University, National institute of neurosciences and Dhaka medical college hospital. Glial tumors with (WHO) grade I and II were classified as low grade and grade III, IV as high grade. PW MRI was labeled low volume or high volume. The perfusion study was performed using dynamicT1-weighted

contrast imaging technique. A single dose of gadolinium (0.1 mmol/kg) was administered at 2 ml/s, and repetitive acquisitions were made through the tumor at longer intervals, typically every 15–26 s. The tumour were analyzed by perfusion-weighted MRI, and the relative CBV (rCBV) was calculated. A cutoff value of 1.7 is used in grading high grade tumour. Then it was matched with pathological diagnosis. The correlation of relative cerebral blood volume with histopathological grading of glioma was done by spearman's correlation test. Box plotting was done for graphical depiction of relative cerebral volume in histopathological grading of glioma. The pathological analysis was performed by a consultant histopathologist who was impartial to study, using World Health Organization (WHO) classification 2007.

Data were processed and analyzed using computer software SPSS (Statistical Package for Social Sciences) version 22. Statistical correlation was done using Spearman's correlation test. P-value < 0.05 was considered statistically significant.

Operational Definitions

Gliomas

Gliomas are the most common primary neoplasms of the brain originating from glial tissue. These include astrocytomas, oligodendrogliomas, and oligoastrocytomas, based on the originating cell. They are classified into 4 grades (grade I-II, low-grade; grade III-IV, high-grade) according to the guidelines of the World Health Organization (WHO) with glioblastoma being grade IV tumors¹⁷.

MRI

The usual presentation of gliomas on MRI scans includes hypo or iso intensity on T1W imaging and hyperintensity on T2W imaging. There may be surrounding vasogenic edema, necrotic areas, and distortion of adjacent structures¹.

Imaging characteristics such as degree of contrast area, tumor necrosis volume, and edema surrounding tumor have been well identified as prognostic markers in high grade lesion^{12,13}.

PW MRI

Perfusion-weighted imaging (PWI) is an MRI modality that gives insights into the delivery of blood to tissues by monitoring a bolus of contrast agent as it passes through the blood vasculature. A common biomarker derived from PWI is the relative cerebral blood volume (rCBV). Measurements of rCBV have been shown to be higher in high grade tumors and low in low-grade tumors¹⁶.

Cerebral blood volume (CBV): CBV was defined as the total volume of blood traversing a given region of the brain, measured in milliliters of blood per 100g of brain tissue (ml/100g)¹⁸.

* It is 4-5ml/100gm of brain

* 2.5 + 0.4 ml/100gm of grey matter.

* 1.7 + 0.4 ml/100gm of white matter.

Cerebral blood flow (CBF): CBF was defined as the volume of blood traversing a given region of the brain per unit time, measured in milliliters of blood per 100g of brain tissue per minute (ml/100g/min)¹⁸.

• Cerebral blood flow is 80ml/100 g/min in grey matter.

• It is 20ml/100gm/min in white matter.

• Global cerebral blood flow is 50ml/100gm/min.

Relative cerebral blood volume (rCBV): It is the ratio of cerebral blood volume between the pathological areas of brain to the contralateral same area of brain matter. A value of rCBV is > 1.7 is considered as high volume and below this level is low volume¹⁷ (Louis et al. 2017).

Results:

The Study was carried out of 35(N) patient, age limit was 11 to 70 years. The Mean \pm SD were 37.70 ± 14.70 . Most of the patients (31.4%) were among 21-30 years of age and second peak were among >50 years (25.7%) of age. In this study out of 35 patients 25 (71.4.7%) patients were male and 10 (28.6%) patients were female. The male female ratio was 2.5:1.

Table-I
MRI findings of the tumors (N=35)

MRI findings	Frequency (n)	Percentage
T1W1		
Hypo intense	31	88.6
Iso intense	3	8.6
Hyper intense	1	2.9
T2W1		
Hypo intense	1	2.9
Iso intense	3	8.6
Hyper intense	31	88.6
Contrast uptake		
Homogeneous	1	2.9
Heterogeneous	21	60.0
Non-enhancing	13	37.1

The MRI findings of tumor is shown in Table 3. 31 tumors (88.6%) were hypointense, 3 (8.6%) were isointense and 1(2.9%) was hyperintense in T1W

image. In T2WI 31(88.6%) were hyperintense, 3 (8.6%) were isointense and 1(2.9%) was hypointense. Contrast images showing, mostly 21 (60%) were heterogeneously contrast enhancing lesion, 13(37.1%) were non-enhancing and 1 (2.9%) was homogeneously contrast enhancing.

Table-II
Grading of glioma (N=35)

Histopathological grading of glioma

	Frequency (n)	Percentage
Grade I	4	11.3
Grade II	15	42.9
Grade III	8	22.9
Grade IV	8	22.9
Grading of glioma according to preoperative PW MRI		
Low grade	17	48.6
High grade	18	51.4

Table II showing histopathological grading of tumor found in this study according to frequency and grading of tumor according to PW MRI. Among 35 tumor, 15 (42.9%) were grade II, 8 (22.9%) and 8 (22.9%) were respectively grade III and IV, 4 (11.3%) was grade I. In PW MRI, 17 (48.6%) were low grade and 18 (51.4%) were high grade.

Table-III

Relative cerebral blood volume (rCBV) in different grading of glioma (histopathological) (N=35)

Histopathological grading of glioma	Relative cerebral blood volume (rCBV)		p-value
	Mean±SD	Min-max	
Grade I	1.35 ± 0.21	1.10 – 1.60	0.007
Grade II	1.67 ± 1.00	0.30 – 4.70	
Grade III	2.74 ± 1.01	1.40 – 4.12	
Grade IV	3.02 ± 1.30	1.20 – 5.24	

Table III demonstrates that relative cerebral blood volume (rCBV) in different grading of glioma. Mean±SD in Grade I of 4 study subject was 1.35 ± 0.21 and minimum value was 1.10 to maximum 1.60. In Grade II 15 study subject had Mean±SD 1.67 ± 1.00 and minimum was 0.30 to maximum 4.70. In Grade III 8 study subject had Mean±SD 2.47 ± 1.01 and minimum was 1.40 to maximum 4.12. . In Grade IV 8 study subject had Mean±SD 3.02 ± 1.30 and minimum was 1.20 to maximum 5.24.

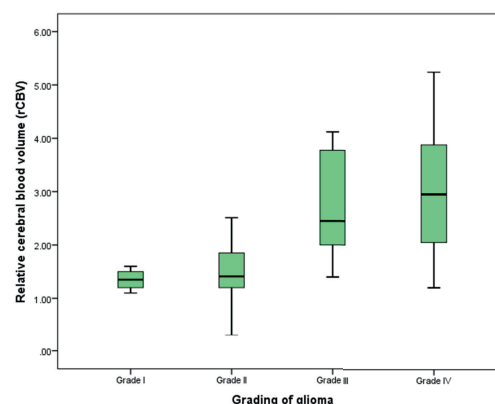


Fig-1: Box plot of relative cerebral blood volume (rCBV) in different grading of glioma (histopathological).

This box plot demonstrates rCBV of each grading of glioma. Highest amount of patient present in Grade II (15), then in Grade III (8) and in Grade IV (8) respectively. The lowest number in Grade I. Median value for Grade I is 1.35, for Grade II is 1.50, for Grade III is 2.42 and for Grade IV is 3.00 . In Grade I, these range of rCBV value from minimum 1.10 to maximum 1.60, in Grade II rCBV value from minimum 0.30 to maximum 2.70, in Grade III from minimum 1.40 to maximum 4.12 and in Grade IV minimum 1.20 to maximum 5.24.

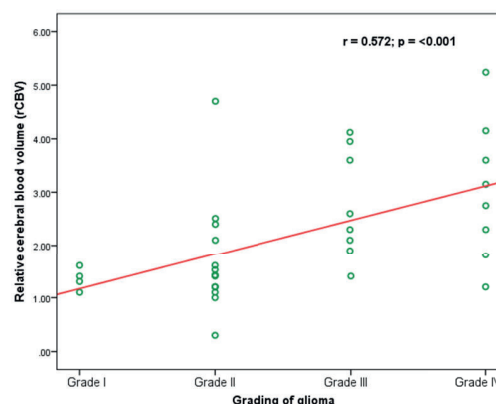


Fig-2: Scattered diagram showing correlation of relative cerebral blood volume (rCBV) with glioma grading (histopathological), Spearman Rank Correlation Coefficient Test (n = 35).

Spearman rank correlation coefficient was done between relative cerebral blood volume and histopathological grading of glioma. The test shows a positive correlation. With coefficient value of r = 0.572 with a significant p-value of p < 0.001.

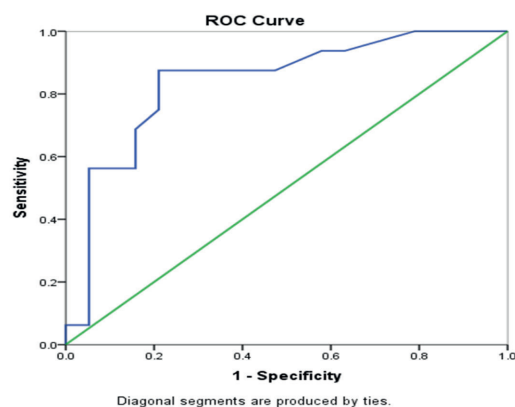


Fig.-3: Figure showing plotting of sensitivity and 1-specificity of relative cerebral blood volume (rCBV) in differentiating high grade glioma from low grade glioma.

Table IV

Sensitivity, specificity, PPV, NPV and accuracy at different cutoff value of relative cerebral blood volume (rCBV) in differentiating high grade glioma from low grade glioma (N=35)

Relative cerebral blood volume (rCBV)	Sensitivity	Specificity	PPV	NPV	Accuracy
1.4	70.0	86.7	87.5	68.4	77.1
1.5	66.7	85.7	87.5	63.2	74.3
1.7	77.8	88.2	87.5	78.9	82.9
1.8	76.5	83.3	81.3	78.9	80.0
1.9	75.0	78.9	75.0	78.9	77.1

Table-V

Association between preoperative PW MRI and histopathological grading of glioma (N=35)

Histopathological Grading	Relative cerebral blood volume (rCBV)		Total	p-value
	High (≥ 1.7)	Low (< 1.7)		
Grade III + Grade IV	14 (77.8)	2 (11.8)	16 (45.7)	<0.001
Grade I + Grade II	4 (22.2)	15 (88.2)	19 (54.3)	
Total	18 (100.0)	17 (100.0)	35 (100.0)	

Chi-square test was done to measure the level of significance. Here, P-value was <.001, which was statistically significant. It indicates that there is a significant association between the relative cerebral blood volume best cutoff value with histopathological grading of glioma.

Table VI

Sensitivity, specificity, PPV, NPV and accuracy of relative cerebral blood volume (rCBV) in differentiating high grade glioma from low grade glioma (N=35)

	%	95%CI	
		Min	Max
Sensitivity	77.8	59.7	86.7
Specificity	88.2	69.1	97.7
Positive predictive value (PPV)	87.5	67.2	97.6
Negative predictive value (NPV)	78.9	61.8	87.4
Accuracy	82.9	64.3	92.1

Table VI shows relative cerebral blood volume in differentiating high-grade glioma from low grade glioma with accuracy of 82.9%, sensitivity and specificity 77.8% and 88.2% respectively. Positive predictive value and negative predictive value of 87.5 and 78.9% respectively.

The ROC curve shows that area under the curve is 0.83 means 83% of the total subjects have been diagnosed correctly.

Discussion:

In this study, we found histopathological grading of glioma is positively correlated with relative cerebral blood volume in PW MRI.

The mean age of the patients was 37.7 years. Majority of the patients were found among younger age. The age incidence in intracranial glioma is an important variable. Gliomas are seen in all age groups from just born to the old age¹⁹.

Gender variation of glioma is also not uncommon. In this study, male predominance was found. The male female ratio was 2.5:1. In a study of glioma series epidemiology in USA and Canada, it was also found male predominance¹⁹.

The locations of gliomas are important for evaluating symptoms and anticipate management for the clinical status. In our study, the majority locations of glioma are in frontal region, which was similar to previous studies²⁰.

The MRI findings of most of the tumor were hypointense in T1W image and hyperintense in T2WI. Among 13 non-enhancing tumor, one was high grade glioma which relative cerebral blood volume was also high in PW MRI. Among 21 heterogeneous contrast enhancing tumor 4 were low grade glioma which relative cerebral blood volume was also low in PW MRI.

The most frequently found histopathological grading of glioma in this study was grade II. Among 35 tumors, the number of low grade gliomas was higher than high grade gliomas. In PW MRI, the number of low grade was lower than high grade.

We measured the relative cerebral blood volume (rCBV) in different grading of glioma. The mean value of relative cerebral blood volume was lowest in grade I and highest in grade IV glioma in this study. Cuccarini et al. (2015) also found relative cerebral blood volume value similar to our study.

For the correlation between relative cerebral blood volume in preoperative PW MRI and histopathological grading of glioma, Spearman's Rank Correlation

Coefficient Test was done. We found a significant positive coefficient value of $r = 0.572$ with a significant p-value of $p = <0.001$. From this observation, it can be opined that histopathological grading of glioma is positively correlated with relative cerebral blood volume in PW MRI. Shoaib et al. (2019) also noted that high grade glioma had higher relative cerebral blood volume than the low grade glioma.

A ROC curve was completed for relative cerebral blood volume value to differentiate high grade from low grade glioma. The optimal cut-off value was determined to be a rCBV of 1.4, with high grade glioma > 1.4 and low grade glioma < 1.4 . There is a significant association of the relative cerebral blood volume best cut off value 1.7 with histopathological grading of glioma. This rCBV cut-off is 77.8% sensitive and 88.2% specific with accuracy of 82.9%. Positive predictive value and negative predictive value of 87.5 and 78.9% respectively.

Shoaib et al. in 2018 also found similar findings with keeping rCBV cut-off is (>1.7). The sensitivity of PWI (with relative cerebral blood volume cutoff of 1.7) in the preoperative assessment of high grade gliomas was 82.6% and specificity was 75%, the positive predictive value (PPV) was 90.48%, and the negative predictive value (NPV) was 60%. The overall accuracy was 80.65%.

In our study clearly showed higher accuracy of perfusion weighted MRI in assessment of glioma grade with sensitivity and specificity. This information may help for the operating neurosurgeon in preoperative assessment and surgical planning. Postoperatively, the neuropathologist can also benefit from such information.

Conclusion:

The measurement of relative cerebral blood volume in PW MRI may be utilized as a useful tool to get an idea about the histopathological grading of glioma preoperatively. Thus, it may help the neurosurgeon in planning and providing better management for the glioma patient.

References:

1. Arevalo-Perez, Thomas, A.A, J, Kaley, T, et al. 2015 'Dynamic Contrast Enhanced T1 MRI Perfusion Differentiates Pseudo Progression from Recurrent Glioblastoma'. *Journal of Neuro-Oncology*, 125, 183-190
2. Barres, BA, Barde, YA 2000, 'Neuronal and glial cell biology', *Current Opinion in Neurobiology*, vol.10, no.1, pp.642-648.
3. Sloan,AE, Abdolvahvi,R and Hlatky,R 2004, Gliomas, in *Principles of Neurosurgery*, Rengachary,SS & Ellenbogen, RG(eds.), 2ndedn, Elsevier Mosby, USA, pp. 451-477.

4. Georgiev,R, Balev,B, Kaprelyan,A, Novakova,M 2015, 'Magnetic resonance diffusion and perfusion for differentiation of low grade from high grade glioma', Varna Medical Forum,vol.4,no.1,pp 15-21.
5. Louis, DN, Ohgaki, H, Wiestler, OD, Cavenee, WK, Burger, PC, Jouvet, A, Scheithauer, BW and Kleihues, P 2007, 'The 2007 WHO classification of tumours of the central nervous system',Acta neuropathological,vol.114,no.2, pp.97-109.
6. Verhaak, RG, Hoadley, KA, Purdom, E, Wang,V, Qi, Y, Wilkerson, MD, Miller, CR, Ding, L, Golub, T, Mesirov, JP and Alex, G 2010, 'Integrated genomic analysis identifies clinically relevant subtypes of glioblastoma characterized by abnormalities in PDGFRA, IDH1, EGFR and NF1', Cancer cell,vol.17,no.1,pp.98-110.
7. Ohgaki,H and Kleihues,P 2009, 'Genetic alteration and signaling pathways in the evolution of gliomas', Cancer science,vol.100,no.12,pp.2235-2241.
8. Harpold, H.L, Alvord Jr ,EC and Swanson, KR 2007,'The evolution of mathematical modeling of glioma proliferation and invasion, Journal of Neuropathology and Experimental Neurology,vol.66,no.1, pp.1-9.
9. Ohgaki, H and Kleihues, P 2013, 'The definition of primary and secondary glioblastoma', Clinical Cancer Research,vol.19, pp.764-772.
10. Jain, KK, Sahoo, P, Tyagi, R, Mehta, A, Patir, R, Vaishya, S, N, Prakash, Vasudev, N, Gupta, RK, 2015,'Prospective glioma grading using single-dose dynamic contrast-enhanced perfusion MRI', Clinical Radiology, Elsevier, vol.70, issue.10, pp.1128-1135.
11. Arvinda, HR, Kesavadas,C, Sarma,PS, Thomas,B, Radhakrishnan,VV, Gupta, AK, Kapilamoorthy,TR,2009, Nair, 'Glioma grading: sensitivity, specificity, positive and negative predictive values of diffusion and perfusion imaging', Journal of Neurooncology,vol.94,pp.87-96
12. Hammoud,MA, Sawaya,R, Shi,W, Thall,PF and Leeds,NE 1996, 'Prognostic significance of preoperative MRI scans in glioblastoma multiforme', Journal of neuro-oncology,vol.27,no.1, pp.65-73
13. Iliadis,G, Kotoula,V, Chatzisitiriou,A, Televantou,D, Eleftheraki,AG, Lambaki, S, Misailidou,D, Selviaridis,P and Fountzilas,G 2012, 'Volumetric and MGMT parameters in glioblastoma patients: survival analysis', BMC cancer, vol.12no.1, p.3.
14. Fan,GG, Deng,QL, Wu,ZH, Guo,QY,2006, 'Usefulness of diffusion/perfusion-weighted MRI in patients with non-enhancing supratentorial brain gliomas: a valuable tool to predict tumour grading?',The British Journal of Radiology,vol.79,no.36,pp. 652–658.
15. Shoaib,Y Nayil,K, Makhdoomi,R Asma,A, Ramzan,A Shaheen,F,Wani,A, 2019, 'Role of Diffusion and Perfusion Magnetic Resonance Imaging in Predicting the Histopathological Grade of Gliomas - A Prospective Study', Asian J Neurosurgery,vol.14,no.1,pp. 47–51.
16. Leu,K, Ott,GA, Lai,A, Nghiemphu,PL, Pope,WB, Yong,WH, Liau, LM, Cloughesy,TF, Ellingson,BM 2017, 'Perfusion and diffusion MRI signatures in histologic and genetic subtypes of WHO grade II–III diffuse gliomas',Journal of Neuro-Oncology,vol.134,no.1, pp177–188.
17. Louis, DN, Ohgaki, H, Wiestler, OD, Cavenee, WK, Burger, PC, Jouvet, A, Scheithauer, BW and Kleihues, P 2007, 'The 2007 WHO classification of tumours of the central nervous system',Acta neuropathological,vol.114,no.2, pp.97-109.
18. Leenders,KL, Perani,D, Lammertsma,AA, Heather,JD, Buckingham,P, Healy,MR, Gibbs,JM, Wise,RS, Hatazawa,J, Herold,S, Beaney,RP, Brooks,DJ, Spinks,T, Rhodes,C, Frackowiak,RJ, Jones,T 1990, 'Cerebral blood flow, blood volume and oxygen utilization normal values and effect of age', In "BRAIN" a Journal of neurology,vol.113, issue.1,pp.27-47.
19. Ostrom QT, Gittleman H, Stetson L, Virk S, Barnholtz-Sloan JS. 2018 'Epidemiology of Intracranial Gliomas.' Prog Neurol Surg.,vol 30, pp.1-11
20. Armstrong,TS, Bishof,AM, Brown,PD, Klein,M, Taphorn,MJ and Theodore-Oklota,C 2016, 'Determining priority signs and symptoms for use as clinical outcomes assessment in trials including patients with malignant gliomas', Panel 1 Report.Neuro-oncology,vol.18, (suppl_2),pp.ii1–ii12.