

## Case Report

# Spinal Dural Arteriovenous Fistulas: Surgical Outcome Analysis of Twenty Cases

Salek MAA<sup>1</sup>, Hasan MM<sup>2</sup>, Islam MS<sup>3</sup>, Rana MS<sup>4</sup>, Manik MAH<sup>5</sup>

**Conflict of interest:** There is no Conflict of interest relevant to this paper to disclose.

**Funding Agency:** Was not funded by any institute or any group.

**Contribution to authors:** Prof. (Col). Dr. Md. Al Amin Salek, Dr. Md. Motasimul Hasan

**Manuscript Preparation:** Prof. (Col). Dr. Md. Al Amin Salek, Dr. Md. Sumon Rana,

**Data Collection:** Dr. Abdul Hye Manik

**Editorial formatting:** Prof. Md Shafiqul Islam

**Copyright:** ©2022bang. BJNS published by BSNS. This article is published under the creative commons CC-BY-NC license. This license permits use distribution (<https://creativecommons.org/licenses/by-nc/4-0/>) reproduction in any medium, provided the original work is properly cited and is not used for commercial purposes.

**Received:** 20 July, 2023

**Accepted:** 23 August, 2023

### Abstract:

**Background:** Spinal dural arteriovenous fistulas (SDAVFs) are rare complex spinal vascular shunts, which can inevitably lead to severe disability if remain untreated.

**Methods:** Retrospective analysis of SDAVFs patients in a period of three years (2019 to 2021) who presented with progressive paraparesis, bladder symptoms and/or sensory disturbances. They were evaluated by MRI and localization of the fistula was done by spinal catheter angiogram. Spinal AV fistulas were simply classified as extradural and intradural. They all underwent microsurgical shunt interruption. Neurological function was evaluated by Aminoff-Logue Scale (ALS) consecutively at the day before surgery, 6 months and 1 year after surgery.

**Results:** A total of 20 patients (mean age  $35 \pm 10$  years, 16 (80.0%) are male. The mean interval from onset to diagnosis was  $6 \pm 3$  months. Among the anatomical location of fistulas, 1 (5.0%) was in cervical, 16 (80.0%) were in thoracic, and 3 (15.0%) were in lumbar. Among the angiographic types of fistulas, 18 (90.0%) were intradural and 2 (10.0%) were extradural. Mean pre-treatment ALS was 5.3 and mean last examination ALS was 3.9. There was a significant improvement of the ALS between pretreatment and last examination ALS ( $P = 0.0009$ ). Among 20 surgical procedures there were complications in three cases (15%): epidural hematoma in 1 case, cerebrospinal fluid leakage in 1 case and post-operative wound infection in 1 case

**Conclusions:** In our study, microsurgical interruption of timely diagnosed SDAVF showed good and stable results over time.

**Keywords:** Spinal dural arteriovenous fistula, spinal catheter angiogram

Bang. J Neurosurgery 2023; 12(2): 137-141

### Introduction

Spinal dural arteriovenous fistula (SDAVF) is a rare disease, the etiology of which is not entirely clear. It is the most common vascular malformation of the spinal cord, comprising 60-80 % of the cases.<sup>1</sup> They are defined as direct arteriovenous shunts in the spinal dura mater between a segmental root artery and a perimedullary vein.<sup>2</sup> The etiology of SDAVFs is unknown but they are presumed to be an acquired pathology mainly affecting middle-aged men. The high venous pressure leading to chronic hypoxia is presumed to be the cause of clinical symptoms.<sup>4,5,6</sup> SDAVFs are

commonly located at the thoracic and lumbar levels and are responsible for progressive myelopathies with progressive sensory and motor deficit of the lower limbs associated with sphincter disturbances.<sup>7</sup> There is a male predominance with a sex ratio of almost 5:1.<sup>8</sup> SDAVFs is considered as a curable cause of myelopathy. SDAVFs treatment consists of interrupting the shunt between the artery and the vein either surgically or endovascularly. The main surgical difficulty is locating the origin of the shunting vein.<sup>9</sup>

The main objective of this study was to describe clinical outcome of SDAVFs patients who were treated surgically.

1. Prof. (Col) Dr. Md. Al Amin Salek, Professor & Colonel, Combined Military Hospital, Dhaka.
2. Dr. Md. Motasimul Hasan, Associate Professor, Dhaka Medical College Hospital.
3. Prof. Dr. Md. Shafiqul Islam, Professor & Head, Dhaka Medical College Hospital.
4. Dr. Md. Sumon Rana, Assistant Professor, Dhaka Medical College Hospital.
5. Lt. Col Dr. Md. Abdul Hye Manik, Consultant, Combined Military Hospital, Dhaka.

**Address of Correspondence:** Prof. (Col) Dr. Md. Al Amin Salek, Professor & Colonel, Combined Military Hospital, Dhaka, Email: salek1972@yahoo.com, Phone: 01780373721

Secondary objectives were to find out the failure rate, late recurrence rate and complication rate of surgery.

**Materials and Methods:**

We conducted a retrospective observational study. The medical records of 15 consecutive patients with a SDAVFs treated in 2 academic neurosurgical departments (Combined Military Hospital Dhaka and Dhaka Medical College Hospital) between 2019 and 2021. Inclusion criteria were patients treated for a SDAVFs surgically. Exclusion criteria were SDAVFs that were treated endovascularly and those were not treated.

*Clinical data:* Age at diagnosis, gender, medical history, symptoms were collected for each patient. The neurological status was assessed using the Aminoff-Logue Scale (ALS). This scale evaluates gait (G score) and micturition (M score) disturbances. Pre-operative ALS (G+M score) and ALS at last medical examination were retrospectively calculated.

*Radiological data:* Level of intramedullary hyperintensity and flow voids on T2-weighted MRI was measured using the corresponding number of vertebral bodies. Fistula level was identified by selective catheter spinal arteriography.

*Treatment:* Treatment method of SDAVFs, initial success of treatment, recurrence and complications were reviewed. Recurrence was defined as a

symptomatic re-opening of the fistula after an initial successful exclusion either by surgery or endovascular embolization. The surgical procedure consisted of laminectomy centred on the arteriovenous shunt under guidance of image intensifier, opening of the dura and exclusion of the fistula at the origin of the draining vein.

*Primary endpoint:* The primary objective of the study was to observe the neurological outcome between the pre-treatment ALS and the last examination ALS.

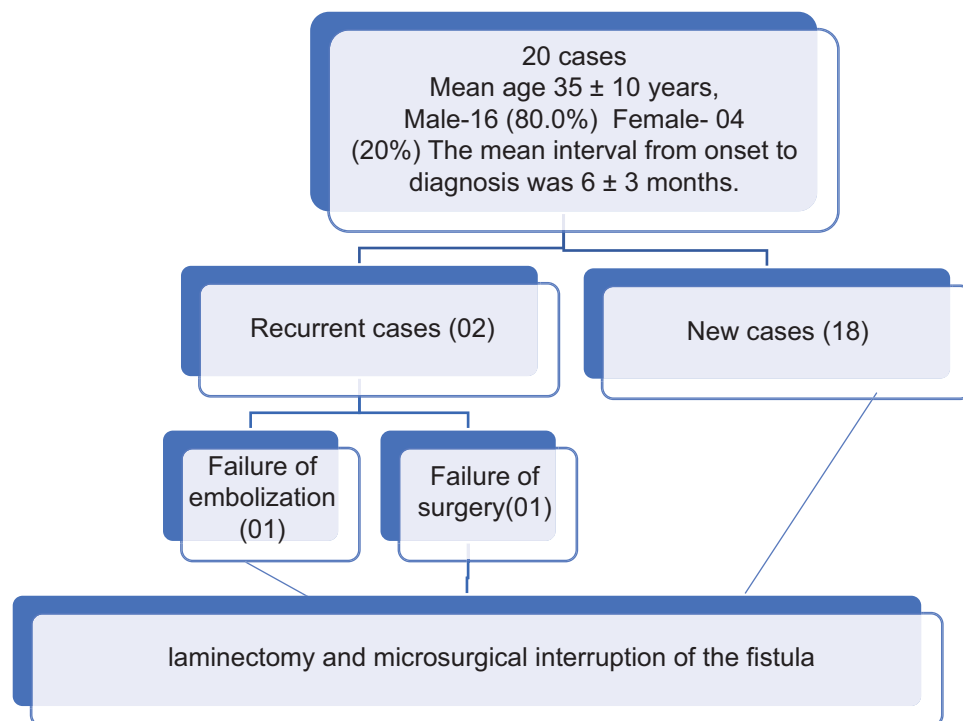
*Secondary endpoints:* Secondary endpoints were to find out the recurrence rate and the complication rate.

*Statistical analysis:* Descriptive statistics were used for age, gender, anatomical location and angiographic typing, pre-treatment and last examination ALS. Linear mixed models were used for the primary objective. Comparisons between pre-treatment and last examination ALS for each subgroup were made using the Tukey Test. The significance threshold was set at  $P \leq 0.05$ .

*Ethical approval:* This study was reviewed and approved by the ethics committee of our institution.


**Results:**

*Patient characteristics and treatment method:* A total of 15 surgical procedures were performed: 13 as an initial treatment, 1 after an initial failed embolization attempt, 1 after failed initial surgery. (Fig-1)



**Fig.-1: Flow chart of patient characteristics and treatment method**

**Anatomical and angiographic findings:** Among the anatomical location of fistulas, 1(05.0%) was in cervical, 16 (80.0%) were in thoracic and 3 (15.0%) was in lumbar region. Among the angiographic types of fistulas, 18(90.0%) were intradural and, 2 (10.0%) were extradural. (Fig-2)



**Fig-2: Anatomical and angiographic findings**

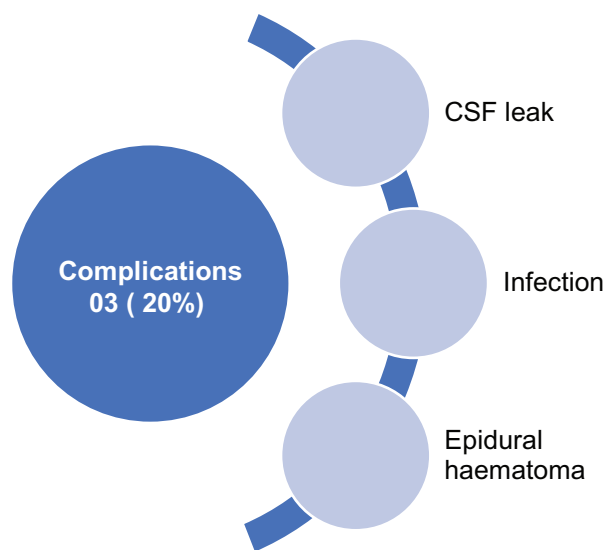
**Clinical outcome:** Mean pre-treatment ALS were 5.3 and mean last examination ALS was 3.9. There was a significant improvement of the ALS between pretreatment and

**Table-I**  
*Clinical outcome after surgery*

Variables	Pretreatment score	Last examination score	P value
ALS	5.3	3.9	P=0.0009
G score	3.6	2.5	P<0.0001
M score	1.6	1.4	Not significant

last examination ALS ( $P = 0.0009$ ). Further analyses were made for the G score and the M score. Mean pre-treatment and mean last examination G score were respectively 3.6 and 2.5. The G score improved significantly after surgery ( $P < 0.0001$ ). Mean pre-treatment and mean last examination M score were respectively 1.6 and 1.4 after surgery. M score did not improve significantly after the treatment. (Table-i)

**Complications:** Among 20 surgical procedures there were complications in three cases (15%): epidural hematoma in 1 case, cerebrospinal fluid leakage in 1 case and post-operative wound infection in 1 case. (Fig-3) A revision surgery was necessary for all 3patients, and they recovered well.



**Fig-3: Complications following surgery**

**Table-II**  
*Aminoff and Logue scale<sup>11</sup>*

Gait (G)	Micturition (M)
G0 Normal	M0 Normal
G1 Leg weakness, abnormal gait or stance, but no restriction of activity	M1 Hesitancy, frequency, urgency
G2 Restricted activity	M2 Occasional urinary incontinence or retention
G3 Requiring one stick for walking	M3 Total incontinence or persistent retention
G4 Requiring two sticks, crutches or walker	
G5 Confined to wheelchair	
G Score =	M score =
G+M score=	

Aminoff-Logue Scale (ALS) is used as a tool for neurological outcome.

**Table-III**  
*Characteristics of patents with clinical presentation*

Variables	Mean ±SD
Age (years)	35±10
Sex	
Male	12 (80%)
Female	03 (20%)
Interval from onset to diagnosis(months)	6±3
ALS	
Pretreatment	5.3±2.2
Last examination	3.9±2.6

### Discussion:

SDAVFs are rare and still underdiagnosed entities. They are the most frequent vascular malformation of the spine and account for approximately 70% of all vascular spinal malformations. They need proper treatment to prevent morbidity with progressive spinal cord symptoms.<sup>10</sup>

In the literature there is a male predominance with a sex ratio of almost 5:1.<sup>12</sup> In our study it was 4:1. There was a significant improvement of the ALS between pretreatment and last examination ALS ( $P = 0.0009$ ). (Table-iii) These results suggest that microsurgical interruption of SDAVFs is an efficient treatment option in achieving a permanent occlusion using a single procedure. Lee, H.S. et al<sup>13</sup> proposed surgical treatment is still the first option when endovascular therapy (EVT) is not feasible after diagnostic spinal angiography. In our setup dedicated endovascular intervention is yet to develop. In this study, the overall complication rate was 15% which was higher than that of other studies.<sup>14</sup> All the complication cases were managed successfully after surgery. Therefore, complication rate should not present an obstacle for the choice of surgery. Surgical technique has improved in recent years, which has raised the occlusion rate and decreased the risk of complications. Operating microscopes have been perfected with fluorescence modules. The use of indocyanine green or fluorescein has been proved to be useful in vascular neurosurgery.<sup>15-17</sup> They can be used in the same way for confirmation of the angioarchitecture of the SDAVFs and to verify its occlusion at the end of the procedure.<sup>18</sup> Furthermore, some authors have reported that pre-operative identification of the level of the SDAVF can be carried out by placing a coil in the feeding artery during the pre-operative spinal arteriography. This technique appears to decrease the risk of error of

vertebral level.<sup>19</sup> Finally, mini-invasive technique with limited surgical exposure could reduce the risk of infection and decrease the length of hospital stay.<sup>20</sup> Our study has some limitations. The patient sample was small due to the rarity of this pathology. Our clinical endpoint (ALS) was calculated retrospectively which was a potential bias.

**Conclusion:** Surgery may be considered as a first-line treatment in SDAVFs considering the straightforward technical aspects and favourable clinicoradiological outcome.

### References:

1. Maimon S, Luckman Y, Strauss I. Spinal Dural Arteriovenous Fistula: A Review. *Adv Tech Stand Neurosurg.* 2016;(43):111-37.
2. Kim LJ, Spetzler RF. Classification and Surgical Management of Spinal Arteriovenous Lesions: Arteriovenous Fistulae and Arteriovenous Malformations. *Neurosurgery.* 2006; 59:195-201.
3. Rosenblum B, Oldfield EH, Doppman JL, Di Chiro G. Spinal arteriovenous malformations: a comparison of dural arteriovenous fistulas and intradural AVMs in 81 patients. *J Neurosurg.* 1987;67:795-802.
4. Aminoff MJ, Barnard RO, Logue V. The pathophysiology of spinal vascular malformations. *J Neurol Sci.* 1974; 23:255-263.
5. Kendall BE, Logue V. Spinal epidural angiomatous malformations draining into intrathecal veins. *Neuroradiology.* 1977; 13:181-189.
6. Hassler W, Thron A, Grote EH. Hemodynamics of spinal dural arteriovenous fistulas. An intraoperative study. *Neurosurg.* 1989; 70:360-370.
7. Cenzato M, Debernardi A, Stefani R, D'Aliberti G, Piparo M, Talamonti G et al. Spinal dural arteriovenous fistulas: outcome and prognostic factors. *Neurosurg Focus.* 2012;32: E11.
8. Ropper AE, Gross BA, Du R. Surgical treatment of Type I spinal dural arteriovenous fistulas. *Neurosurg Focus.* 2012;32: E3.

9. Kirsch M, Berg-Dammer E, Musahl C, Bätzner H, Kühne D, Henkes H. Endovascular management of spinal dural arteriovenous fistulas in 78 patients. *Neuroradiology*. 2013; 55:337-343.
10. Krings T, Geibprasert S. Spinal dural arteriovenous fistulas. *AJNR Am J Neuroradiol*. 2009;30(4):639-648. doi:10.3174/ajnr. A1485.
11. Aminoff MJ, Logue V. Clinical features of spinal vascular malformations. *Brain*. 1974; 97:197-210.
12. Nagata S, Morioka T, Natori Y, Matsukado K, Sasaki T, Yamada T. Factors that affect the surgical outcomes of spinal dural arteriovenous fistulas. *Surg Neurol*. 2006; 65:563-568.
13. Lee, H.S, Kang, HS., Kim, S.M. et al. Treatment strategy to maximize the treatment outcome of spinal dural arteriovenous fistula after initial endovascular embolization attempt at diagnostic angiography. *Sci Rep* 11, 10004 (2021).
14. Muralidharan R, Mandrekar J, Lanzino G, Atkinson JL, Rabinstein AA. Prognostic value of clinical and radiological signs in the postoperative outcome of spinal dural arteriovenous fistula. *Spine*. 2013; 14:1188-1193.
15. Bretonnier M, Henaux PL, Morandi X, Le Reste PJ. Fluorescein-guided resection of brain arteriovenous malformations: A short series. *J Clin Neurosci*. 2018; 52:37-40.
16. Schuette AJ, Cawley CM, Barrow DL. Indocyanine green videoangiography in the management of dural arteriovenous fistulae. *Neurosurgery*. 2010; 67:658-662.
17. Spiotta AM, Bain M, Moskowitz S. Intraoperative indocyanine green angiography as a substitute for conventional angiography in the surgical management of spinal dural arteriovenous fistulae. *J Neurointerv Surg*. 2011; 3:182-185.
18. Zaidi HA, Abla AA, Nakaji P, Chowdhry SA, Albuquerque FC, Spetzler RF. Indocyanine green angiography in the surgical management of cerebral arteriovenous malformations: lessons learned in 130 consecutive cases. *Neurosurgery*. 2014; 10:246-251.
19. Marquardt G, Berkefeld J, Seifert V, Gerlach R. Preoperative coil marking to facilitate intraoperative localization of spinal dural arteriovenous fistulas. *Eur Spine J*. 2009; 18:1117-1120.
20. Patel NP, Birch BD, Lyons MK, DeMent SE, Elbert GA. Minimally invasive intradural spinal dural arteriovenous fistula ligation. *World Neurosurg*. 2013; 80:267-270. <https://doi.org/10.1016/j.wneu.2012.04.003>.