

Case Report

Neglected Spheno-orbital Meningioma Presenting with Unilateral Blindness

Nath HD¹, Razib KO², Halder H³, Rahman MA⁴, Hasan MM², Uddin ANW⁶
Karim MR⁷, Barua S⁸, Munir SKF⁹

Conflict of interest: There is no Conflict of interest relevant to this paper to disclose.

Funding Agency: Was not funded by any institute or any group.

Contribution to authors: Prof. Dr. Haradhan Deb Nath, Dr. Kh. Olinur Razib

Manuscript Preparation: Dr. Abu Naim Wakil Uddin, Dr. Sk. Farhad Munir

Data Collection: Dr. Md. Robiul Karim, Dr. Md. Abdur Rahim, Dr. Mustafizur Rahman, Dr. Sarwar Alam, Dr. Sanjaya Silwal

Editorial formatting: Prof. Dr. Haradhan Deb Nath

Copyright: ©2022bang. BJNS published by BSNS. This article is published under the creative commons CC-BY-NC license. This license permits use distribution (<https://creativecommons.org/licenses/by-nc/4-0/>) reproduction in any medium, provided the original work is properly cited and is not used for commercial purposes.

Received: 2 January, 2023

Accepted: 11 February 2023

Abstract:

Background: Spheno-orbital meningiomas (SOM) constitutes 9% of all intracranial meningiomas and are originated from sphenoid wing dura. They are also called en plaque meningioma. They cause hyperostosis of involved bone and their soft tissue growth may spread the orbit, the infratemporal fossa, and the temporal fossa. Most patients with SOM are middle-aged women and most commonly presents with unilateral, nonpulsating, progressive proptosis. Recently a woman with unilateral progressive proptosis from a remote area of Bangladesh presented to us with blindness of her left eye due to diagnostic delay. After thorough evaluation and imaging studies, she was diagnosed with a large spheno-orbital meningioma with extensive bony involvement of skull base and orbit.

Objective: This report highlights the necessity of creating awareness among optometrists, undergraduate medical students as well as and ophthalmologists who are practicing in remote areas of Bangladesh about clinical presentation of spheno-orbital meningiomas which is a benign lesion but may be a cause of unilateral blindness if remain undiagnosed for long.

Key words: Blindness Early diagnosis, Spheno-orbital Meningioma, Timely referral, Unilateral Proptosis.

Bang. J Neurosurgery 2023; 13(1): 51-54

Introduction:

Spheno-orbital meningiomas (SOM) constitute 9% of all intracranial meningiomas¹. They are originated from sphenoid wing dura. They spread in a carpet-like growth pattern, hence known as en plaque meningioma², and can extend into the cavernous sinus, superior orbital fissure (SOF), orbital apex, and convexity dura³. They cause hyperostosis of involved bone and their soft tissue growth may spread into the orbit through superior orbital fissure or optic canal and

also into the infratemporal and temporal fossae⁴. Most patients with SOM are middle-aged women⁵ and most commonly presents with unilateral, nonpulsating, progressive proptosis. Optic nerve is the most commonly involved cranial nerve which become evident by diminished visual acuity and a constricted visual field. Oculomotor nerve is also involved along with CN IV, V, VI and VIII. Restricted ocular movement occurs due to intraorbital extension of tumour and may sometimes result in diplopia. As a result,

1. Pro. Dr. Haradhan Deb Nath, Professor, Department of Neurosurgery, Bangabandhu Sheikh Mujib Medical University, Dhaka.
 2. Dr. KH. Olinur Razib, Resident, Department of Neurosurgery, Bangabandhu Sheikh Mujib Medical University, Dhaka.
 3. Dr. Rathin Halder, Medical Officer, Department of Neurosurgery, Dhaka Medical College & Hospital, Dhaka.
 4. Dr. Md. Aatur Rahman, Registrar, Department of Neurosurgery, SSMC Mitford Hospital, Dhaka.
 5. Dr. Md. Motasimul Hasan, Assistant Professor, Department of Neurosurgery, Dhaka Medical College & Hospital, Dhaka.
 6. Dr. Abu Naim Wakil Uddin, Medical Officer, Department of Neurosurgery, Bangabandhu Sheikh Mujib Medical University, Dhaka.
 7. Dr. Md Rabiul Karim, Assistant Professor, Department of Neurosurgery, Chittagong Medical College Hospital, Chittagong.
 8. Dr. Sudip Barua, Medical Officer, Department of Neurosurgery, Bangabandhu Sheikh Mujib Medical University, Dhaka.
 9. Dr. SK Farhad Munir, Research Assistant, Department of Neurosurgery, Bangabandhu Sheikh Mujib Medical University, Dhaka.
- Address to Correspondence:** Dr. KH. Olinur Razib, Resident, Department of Neurosurgery, Bangabandhu Sheikh Mujib Medical University, Dhaka. Mobile: 01727374275.

management of sphenoorbital meningiomas remain challenging due to extensive bony involvement at and around optic canal and superior orbital fissure and involvement of cranial nerves¹⁰.

Case Presentation:

A previously healthy 45-year-old woman, presented to our neurosurgery clinic with the complaints of swelling of left side of forehead for 7 years and protrusion of left eyeball for 4 years associated with gradual dimness of vision in left eye that eventually rendered her blind on her left eye for last few months. During this long period of illness, she was taken to several local optometrists and general physicians who failed to refer her timely. Few months ago, she was taken to an ophthalmologist who advised her an orbital protocol MRI and was only then diagnosed as sphenoorbital meningioma (SOM) and was eventually referred to neurosurgeon. Before presenting to our neurosurgical clinic, for last few weeks, she was unable to close her eyelids of left eye that caused watering and redness which resulted in severe pain and ulceration of exposed part of the eyeball. She was diabetic and hypertensive and was on oral medications. Her medical history was otherwise unremarkable, with no significant family history of ocular or neurological disorders.

On examination, she had visual acuity of 6/9 and normal visual field on right eye, whereas left eye showed a complete loss of light perception and projection of rays. External examination revealed proptosis of the left eye edema of eye lids, congestion of conjunctiva, ulceration of exposed part of cornea and mild restriction of eyeball movement in all directions. Neurological examination was otherwise normal except left optic neuropathy and absent corneal reflex on left side. There was associated disfigurement of left frontoparietotemporal region of the head.

Given the significant visual impairment and orbital findings, patient was investigated with skull radiographs, contrast enhanced MRI of brain and contrast CT scan of head with 3D reconstruction of skull base and orbit for planning of surgical approach. Magnetic resonance imaging (MRI) of the brain and orbit revealed a well-defined, heterogeneously enhancing mass lesion involving the middle and anterior temporal fossa centered at the left sphenoid wing and extending into the orbit, compressing the

optic nerve and severely distorting the regional anatomy. Tumor extension was noted into sphenoid and ethmoidal sinuses. Contrast CT revealed extensive hyperostosis of anterior and middle fossa floors and lateral wall, roof of orbit including lateral and inferior walls, sphenoid and zygoma. These findings were consistent with a sphenoorbital meningioma with extensive bone involvement.

After consultation with the department of ophthalmology, the decision was made to sacrifice the nonfunctional left eye by exenteration and pursue aggressive surgical removal of the tumour in a single setting. After exenteration of left eyeball a left fronto-temporo-parietal craniectomy and removal of involved portion of zygoma was performed. Multiple burr holes were made to make involved bone removal quicker and minimize blood loss. Extensive drilling of the involved skull base and orbit was performed in an aim of maximum decompression. Maximal safe resection of the en plaque tumor was ensured while preserving vital structures and vessels. Cranioplasty was not done at the same setting and left for a 2nd look surgery.

Histopathological examination confirmed the diagnosis as meningothelial meningioma, WHO Grade I.

Figures: Preoperative Images. A- Patient presented with painless proptosis and blindness that eventually resulted in painful exposure keratitis followed by corneal ulceration (with kind permission of the patient and her family) B- contrast enhanced MRI showing proptosis of left eyeball and severe compression on of left optic nerve resulting in stretching and elongation. C- CT with contrast and 3D reconstruction of bony window showing large en plaque meningioma in left sphenoorbital region with extensive bony involvement involving left frontal, parietal and temporal bones along with ipsilateral greater and lesser wings, posterolateral wall of orbit and disfigurement of orbital rim and frontal process of zygoma. There is compression on frontal and temporal lobes and midline shift.

Follow-up and Outcome:

Postoperatively the patient had subjective improvement in pain and visible improvement of proptosis. A second look surgery and cranioplasty was planned 3 months later. Regular follow-up visits were scheduled to monitor for tumor progression, neurological symptoms, and complications.

Figures: Post-operative Images. A- Patient at 3 months following surgery having no new neurological deficit and well healed scars of both craniectomy and exenteration of eyeball surgeries (with kind permission of the patient and her family). B – coronal contrast post operative CT scan showing areas of maximal safe tumour resection and removal of bone

along with substantial amount of hyperostotic bone of the skull base left behind during surgery; 3D reconstruction CT showing removal of left frontal, parietal and temporal bones along with partial removal of involved orbital rim, lateral wall and part of zygoma in an aim of preventing further facial disfigurement.

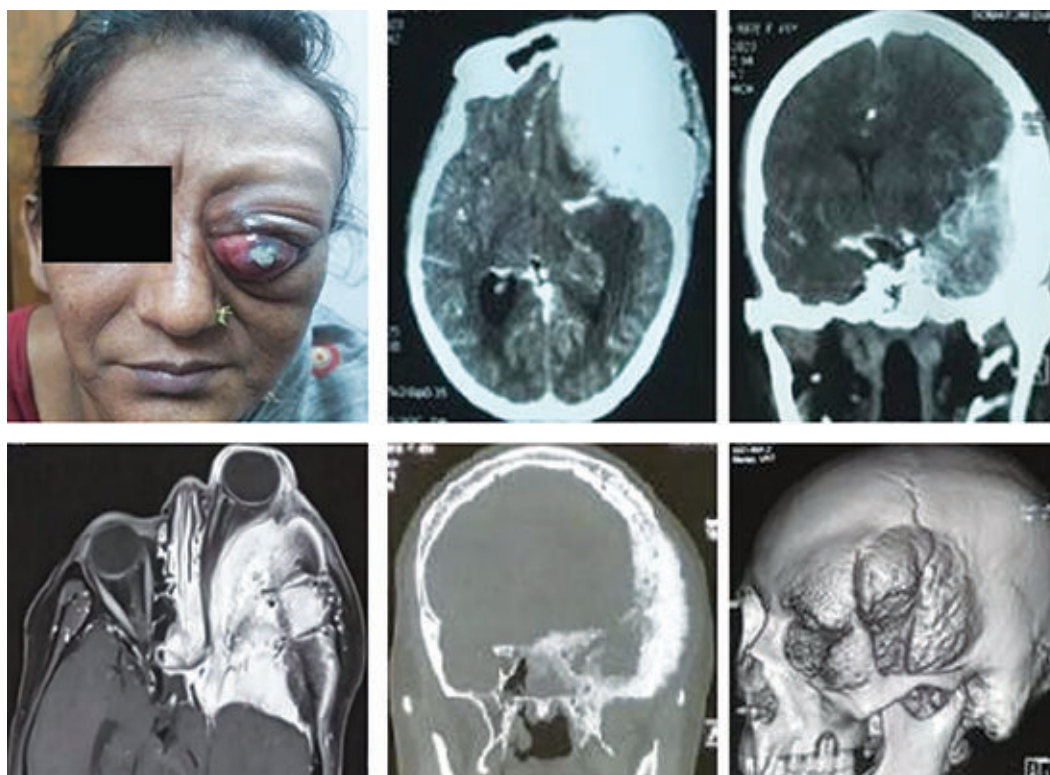


Fig.-1: Preoperative CT scan

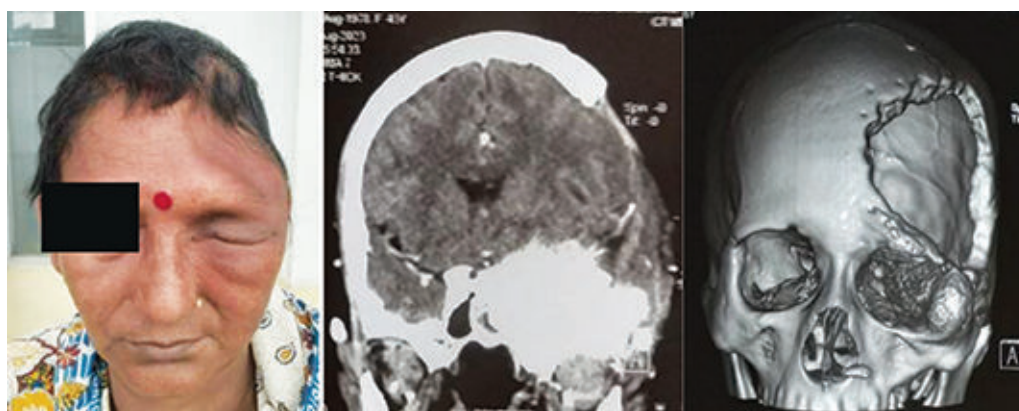


Fig.-2: Postoperative CT scan

Discussion:

SOM is a variety of en-plaque meningioma that arises from the greater sphenoid wing with a distinct periorbital extension and represent 2%–9% of all intracranial meningiomas^{2,6}. Most patients with SOM are middle-aged women whose most common symptom is unilateral, nonpulsating, progressive proptosis (80 to 90%)^{3,5}. 27-80% patients presented with decreased visual acuity, loss of color vision, and a constricted visual field with an enlarged scotoma has been identified in 27 to 80% of patients in published series. They are distinguished by hyperostosis along the sphenoid bone and commonly extend in the skull base involving the lateral and superior orbital walls, the superior orbital fissure (SOF), the optic canal (OC), and the anterior clinoid process. The dural growth is usually widespread, including the basal sphenoid wing, cavernous sinus, and temporal convexity⁷. Hyperostosis and intradural extension can result in the compression of optic nerves or other cranial nerves (CNs), and result in proptosis, visual deterioration, and cosmetic deformity⁶.

Majority of SOMs (92%) present with proptosis often present with visual deficit which results from invasion of the optic canal by the tumor and hyperostosis around the optic canal⁴. Since these tumors have extensive dural and bony involvement, the surgical approach and adequate resection are very challenging. As a result, sphenoorbital meningiomas have a greater recurrence rate and morbidity rate. A single-stage optimal surgery with bone reconstruction is considered the best first-line treatment⁹. In a study of 47 cases of sphenoorbital meningiomas Talachi et al. (2014) recommended that complete tumor resection should not be pursued at the expense of increased morbidity. They emphasized on normalization of proptosis by accurate resection of the superior and lateral orbital walls and careful reconstruction of the frontobasal dura instead of bony reconstruction and considered this as one of the gold standards of surgical treatment.

Although bony reconstruction is thought necessary to prevent pulsatile enophthalmos following surgery in two recent studies by Dos Santos (2022) and Kim et al (2022) recommended that orbital reconstruction was not mandatory to prevent pulsatile enophthalmos. Conclusion:

Spheno orbital meningiomas are rare tumors that can cause significant visual impairment due to optic nerve compression which, if remain undiagnosed for long period, may result in unilateral blindness. Early

diagnosis is the key to avoid the risk of optic nerve compression and subsequent visual disturbances. Timely referral to a neurosurgeon and early intervention are crucial in preventing unwanted visual impairment. Although complete visual recovery may not always be achievable, adequate surgical resection can provide normalization of proptosis and prevent further deterioration in visual function. Long-term follow-up is necessary to monitor for recurrence and manage potential complications associated with the surgery.

References:

1. MacCarty CS, Piepgras DG, Ebersold MJ. Meningeal tumors of the brain. In: Youmans Jr, ed. Neurological Surgery. 2nd ed. Philadelphia, PA: WB Saunders;1982;2936–2966
2. Cushing H, Eisenhardt L. Meningiomas. Their Classification, Regional Behavior, Life History, and Surgical End Results. Springfield, IL: Charles C. Thomas; 1938.
3. Hatiboglu M. A. and DeMonte F. Sphenoorbital Meningiomas. In: DeMonte F., McDermott M. W., Al-Mefty O. ed. AlMefty's Meningiomas. 2nd ed. New York. PA: Thieme; 2001; 248-255
4. Ringel, F., Cedzich, C. and Schramm, J., 2007. Microsurgical technique and results of a series of 63 spheno-orbital meningiomas. Operative Neurosurgery, 60(4), pp.214-222.
5. Honeybul, S., Neil-Dwyer, G., Lang, D.A., Evans, B.T. and Ellison, D.W., 2001. Sphenoid wing meningioma en plaque: a clinical review. Acta neurochirurgica, 143, pp.749-758.
6. Kim, R.B., Fredrickson, V.L. and Couldwell, W.T., 2022. Visual outcomes in spheno- orbital meningioma: a 10-year experience. World Neurosurgery, 158, pp.e726-e734.
7. Mariniello, G., Bonavolontà, G., Tranfa, F. and Maiuri, F., 2013. Management of the optic canal invasion and visual outcome in spheno-orbital meningiomas. Clinical neurology and neurosurgery, 115(9), pp.1615-1620.
8. Talacchi, A., De Carlo, A., D'Agostino, A. and Nocini, P., 2014. Surgical management of ocular symptoms in spheno-orbital meningiomas. Is orbital reconstruction really necessary? Neurosurgical review, 37, pp.301-310.
9. Terrier, L.M., Bernard, F., Fournier, H.D., Morandi, X., Velut, S., Hénaux, P.L., Amelot, A. and François, P., 2018. Spheno-orbital meningiomas surgery: multicenter management study for complex extensive tumors. World neurosurgery, 112, pp.e145- e156.
10. Dos Santos, A.G., Paiva, W.S., da Roz, L.M., do Espírito Santo, M.P., Teixeira, M.J., Figueiredo, E.G. and da Silva, V.T.G., 2022. Spheno-orbital meningiomas: Is orbit reconstruction mandatory? Long-term outcomes and exophthalmos improvement. Surgical Neurology International, 13.