

## Case Report

---

# Exostoses of the external auditory canal

Mani Lal Aich Litu<sup>1</sup>, Abdullah Al mamun<sup>2</sup>, Zahedul Alam<sup>3</sup>, Rojibul Haque<sup>4</sup>, Abu Hanif<sup>5</sup>, Amjad Hossain<sup>6</sup>

### Abstract:

*Auditory exostoses are bone masses located in the external auditory canal. Currently, most researchers agree that the environment (especially water temperature, but also atmospheric temperature and wind action) plays a pivotal role in the development of exostosis. Exostoses are a condition in which the external auditory canal becomes stenotic secondary to hyperplastic bone formation. Also known as "surfer's ear," exostoses are thought to be a reactive process from repeated stimulation by cold water because it occurs commonly in populations such as beach lifeguards and surfers. Exostoses are usually asymptomatic and discovered on routine otoscopy. Rarely, exostoses become sufficiently obstructive to impair hearing or cause recurrent otitis externa. Exostoses are almost always bilateral, symmetric, and occurring in the medial portion of the external auditory canal. The authors report a case of bilateral external auditory canal exostoses in an adult male treated with surgical excision.*

**Key words:** Exostoses, Surfer's ear, otoscopy, hyperplastic.

### Introduction:

External auditory exostoses (EAE) are common in individuals who frequently participate in aquatic activities. They are recognized by otoscopic examination and

characterized by one or more broad-based elevated lesions that protrude into the external auditory canal. New bone growth along the upper edges of the tympanic bone is believed to be the source of these diffuse hyperostotic elevations<sup>1</sup>. Although the cause of EAE has not been firmly established, it has nevertheless been clinically accepted that cold-water exposure is the initiation factor for temporal bone growth<sup>2,3</sup>. With few exceptions, previous clinical studies<sup>1, 4-7</sup> concentrated on the treatment outcomes and consequently were unable to estimate the prevalence of the disorder among persons at risk. Several anthropological studies have tested the cold-water hypothesis by looking at various prehistoric populations. Gregg and Bass<sup>8</sup> reported an EAE prevalence of 3% when examining excavated skulls from inland North American populations, whereas Kennedy<sup>9</sup> showed 30% prevalence among civilizations

1. Assistant professor, ENT-Head & Neck Surgery, SSMCMH, Dhaka, Bangladesh.
2. MS (Thesis) student, ENT-Head & Neck Surgery, SSMCMH, Dhaka, Bangladesh.
3. Professor & Head, ENT-Head & Neck Surgery, SSMCMH, Dhaka, Bangladesh.
4. Associate professor, ENT-Head & Neck Surgery, SSMCMH, Dhaka, Bangladesh.
5. Assistant registrar, ENT-Head & Neck Surgery, SSMCMH, Dhaka, Bangladesh.
6. Registrar, ENT-Head & Neck Surgery, SSMCMH, Dhaka, Bangladesh.

**Address of Correspondence:** Dr. Mani Lal Aich Litu, Asstt. Professor, ENT-Head & Neck surgery, Sir Salimullah Medical College & Mitford Hospital (SSMCMH), Dhaka. E-mail: dr\_mani1234@yahoo.com

known to frequently engage in cold-water activities. A study<sup>10</sup> sought to determine whether EAE is a consequence of habitual fishing in the cold waters of the Pacific Ocean or, rather, a genetically determined malady. They examined more than 1000 crania (dating from 7000 BC to 1500 AD) from 43 sites in northern Chile and found that inhabitants of the coastal regions had the highest prevalence of EAE (30.7%) compared with valley people (2.3%) and highlanders (0%). Furthermore, coastal and valley men had more severe EAE than women of their respective populations. Results of several clinical studies support the cold-water hypothesis. Adams<sup>6</sup> found that, among ten swimming instructors, nine had exostoses. Harrison<sup>11</sup> examined the ears of 2352 freshwater and seawater swimmers and found 1.2% overall prevalence of EAE. Limited research was done on the epidemiological aspects of this topic until 1989, when Umeda and Nakajima<sup>12</sup> examined the ears of 51 professional surfers in Japan and found that 80% of them had exostoses of the external auditory canal. Karegeannes<sup>13</sup> conducted another prevalence study comparing the incidence of EAE in 87 U.S. Navy divers compared with an age matched control group and found that EAE was present in 26% of the divers and in 0% of the controls. He also showed a positive correlation between the severity of exostoses and the extensive history of aquatic activities. The most recently published study that supports a coldwater cause for EAE<sup>14</sup>. After looking at the ears of 21 cold-water Oregon surfers, the investigators concluded that the degree of external ear canal obstruction increases as a function of both the number of years having surfed and the number of sessions surfed per year.

From the 19th century until recently, the cause of auditory exostoses was thought to be genetic. Furthermore, several researchers

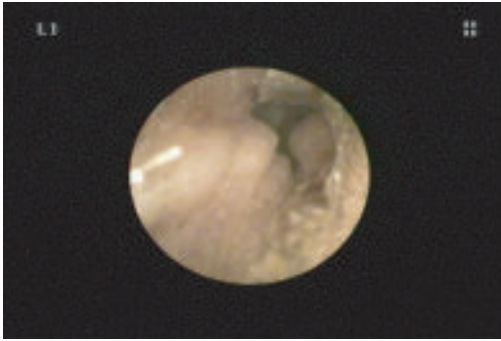
who supported the genetic hypothesis have also cited chemical or mechanical stimuli that lead to irritation of the auditory canal as possible underlying causes of the development of auditory exostoses. Development of auditory exostosis also appears to depend on the use of ear protection in the form of earplugs and/or hoods, which mitigate wind chill or low atmospheric temperatures or both, therefore, preventing the auditory canal to cool off<sup>14</sup>.

#### **Case report:**

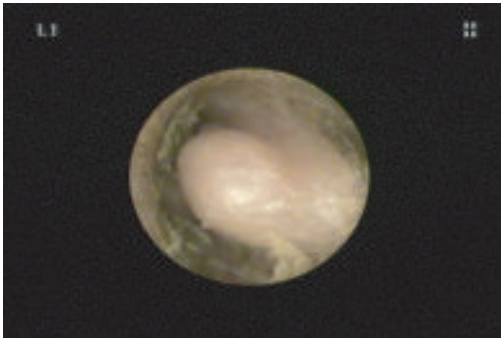
A 40-year-old male presented to our OPD with 4 years history of occasional pain in the left ear, occasional itching of left & right ear for 1 year. Otological examination revealed normal tympanic membranes bilaterally. There was no facial weakness or visual or gait disturbance. The neurological exam was benign. Pure tone audiometry revealed symmetrical mild conductive hearing loss.

Temporal bone computed tomography (CT) revealed bilateral smoothly bordered, broad based bony growths of the EAC. The diagnosis of bilateral EAC exostoses was made. There was no evidence of superior semicircular canal dehiscence. No generalized bony disease or bony tumors were detected. T2 weighted magnetic resonance imaging (MRI) showed right sided exostoses to be more severe than left. The patient opted to proceed with surgery to remove the more severe right sided exostoses. The patient underwent postauricular approach exploration of the right EAC showed significant exostoses posteriorly and superiorly. With use of diamond burrs, the exostoses were removed, revealing "onion skinned" laminated bone. Bone chips were sent for histopathologic exam and showed benign laminated bone consistent with the previous diagnosis .

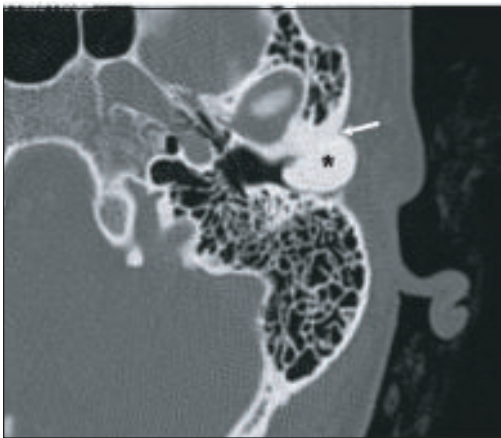
At time of discharge, the patient experienced no immediate relief of his presenting symptoms. In the months of following surgery, he had slow and steady improvement. Thereafter, the patient was advised to follow up every 6 months.



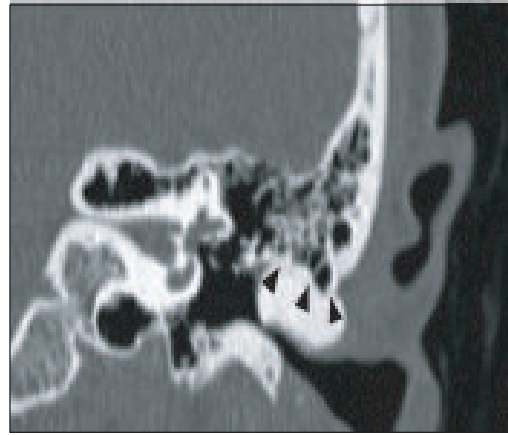
**Figure 1:** Exostosis of right ear



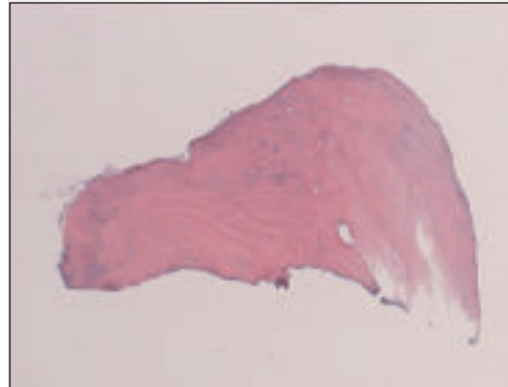
**Figure 2:** Exostosis of left ear.



**Figure 3:** Axial HRCT scan of the temporal bone showing a solitary bony tumor arising from the lateral & anterior part of the EAC.



**Figure 4:** Coronal high-resolution CT scan demonstrating the narrowing of the EAC at the tympano-squamous suture line (arrowhead).



**Figure 5:** Hematoxylin and eosin staining of Temporal bone chip showing onion skinned laminated bone (arrows) Consistent with the diagnosis of exostoses.

#### Discussion:

In some cases, it is likely had exostoses for several years and only experienced significant vertigo in the setting progressive impingement on the nerve bundle, advanced age, and inability to further compensate for vestibular nerve compression. Patient also presented with symptoms secondary to eighth nerve compression, manifested as hearing loss and tinnitus. Some patients are unusual in that only presenting

symptom was tinnitus. In practice, most cases of EAC exostoses are not surgically treated and are not readily accessible for tissue biopsy. In the absence of a tissue diagnosis, radiographic appearance is fundamental in differentiating between various bony lesions of the EAC. The radiographic appearance of an exostosis is that of a smoothly bordered, broad based bony growth protruding into the EAC. Exostoses are often multiple and bilateral. Treatment of EAC exostoses depends on the severity of symptoms occurring due to nerve compression. Observation alone is recommended for asymptomatic individuals. In some cases repeat imaging of the EAC bony growths has not shown any size progression, and their presenting symptoms have remained stable. Surgical excision of the lesion to decompress the nerve complex before irreversible damage is the treatment of choice for severely symptomatic patients, such as those with progressive hearing loss or vertigo, or those at risk of complete canal occlusion. We presented, surgical removal of the exostoses was eventually curative of the patient's presenting symptoms; however, it occurred gradually over a period of one year. The protracted time course required for his recovery likely reflects chronic compression of the neurovascular bundle. Temporal bones from a man who died at 87 years of age as a result of congestive heart failure were studied. The patient was initially evaluated for hearing loss secondary to otosclerosis, and bilateral exostoses were discovered on examination. The patient was from the Los Angeles, California, area, but records were inconclusive as to whether this patient had a history of cold water contact or otitis externa. In addition to the case just described, temporal bones from two other patients were viewed. Exostoses showed a predilection for the medial portion of the

external auditory canal, forming just lateral to the tympanic membrane<sup>15</sup>. The lesions were broad-based and covered by squamous epithelium. Diffuse, bilateral involvement was present in each set of bones. At higher magnification, two distinct types of bone tissue were identified. Superficially, remodeled bone tissue was seen. This densely lamellar bone appeared to be more organized, running parallel to the periosteum. Tightly layered rows of this bone also appeared to contain a lower concentration of fibrovascular channels, especially in areas closer to the periosteum<sup>16</sup>. Bone tissue deep to this appeared loosely compact and more vascular. The layers of this bone were less organized and swirled in random fashion around frequent fibrovascular channels<sup>17</sup>.

#### **Conclusion:**

Anterior exostosis removal by a postauricular route is a safe, rapid, and effective method of relieving patients of occlusive external auditory canal exostosis. By leaving the posterior exostosis intact, patients are not put at risk for injury to the facial nerve, chorda tympani nerve, or ossicles. When the deep ear canal is drilled blind, there are no landmarks to indicate the true path of the external canal.

#### **References:**

1. Sheehy J. Osteoma of the external auditory canal. *Laryngoscope*. 1958; 68: 1667 - 1673.
2. Fowler E Jr, Osmon P. New bone growth due to cold water in the ears. *Arch Otolaryngol*. 1942; 36: 455 - 466.
3. DiBartolomeo JR. Exostoses of the external auditory canal. *Ann Otol Rhinol Laryngol* 1979; 88: 2 - 20.
4. Ayres SC. Exostoses of the external auditory canal. *Arch Otolaryngol*. 1881; 10: 327 - 334.

5. Fabiani M, Filipo B. External ear canal exostosis and aquatic sports. *Otol Rhinol Laryngol*. 1984; 46: 159 - 164.
6. Adams WS. The aetiology of swimmer's exostoses of the external auditory canals and of associated changes in hearing. *J Laryngol Otol* 1951; 65: 133 - 153.
7. Seftel D. Ear canal hyperostosis-surfer's ear. *Arch Otolaryngol* 1977; 103: 58 - 60.
8. Gregg J, Bass W. Exostoses in the external auditory canals. *Ann Otol Rhinol Laryngol* 1970; 79: 834 - 39.
9. Kennedy GE. The relationship between auditory exostoses and cold water: a latitudinal analysis. *Am J Phys Anthropol* 1986; 71: 401 - 15.
10. Standen VG, Arriaza BT, Santoro CM. External auditory exostosis in prehistoric Chilean populations. *Am J Phys Anthropol* 1997; 103: 119 - 29.
11. Harrison D. Exostosis of the external auditory meatus. *J Laryngol Otol* 1951; 65: 704 - 14.
12. Umeda Y, Nakajima M. Surfer's ear in Japan. *Laryngoscope* 1989; 99: 639 - 41.
13. Karegeannes JC. Incidence of bony outgrowths of the external ear canal in U.S. Navy divers. *Undersea Hyperb Med* 1995; 22: 301 - 06.
14. Deleyiannis FW, Cockcroft BD, Pinczower EF. Exostoses of the external auditory canal in Oregon surfers. *Am J Otolaryngol* 1996; 17: 303 - 07.
15. Doan HT, Powell JS. Exostosis of the internal auditory canal *J Laryngol Otol* 1988; 102: 173 - 5.
16. Graham MD. Osteomas and exostoses of the external auditory canal: A clinical, histopathologic and scanning electron microscopic study. *Ann Otol* 1979; 88: 566 - 72.
17. Sheehy JL. Diffuse exostoses and osteomata of the external auditory canal: A report of 100 operations. *Otolaryngol Head Neck Surg* 1982; 54: 77 - 81.