

## Case Report

---

# Primary rhinosporidiosis of parotid duct

Ritam Ray<sup>1</sup>, Rajib Kumar Mondal<sup>2</sup>, Kingshuk Bose<sup>2</sup>, Koushik Dewan<sup>3</sup>, Himel Bera<sup>3</sup>, Ganesh Chandra Gayen<sup>4</sup>

### Abstract:

*Introduction: Rhinosporidiosis is a chronic granulomatous disease. It is commonly seen in Southern Asia specially in India, Bangladesh, Nepal and Sri Lanka and mainly involves the mucosa of the nasal cavity.*

*Case report: We report here an unique case of parotid duct rhinosporidiosis which was incidentally diagnosed by histopathological examination in a 26-year-old male.*

**Key words:** Parotid gland; Rhinosporidiosis; Granulomatous disease

### Introduction:

Rhinosporidiosis is a chronic granulomatous infection which mainly involves the mucous membrane. Though it occurs universally, the disease is endemic in south Asia being mainly reported from southern India, Bangladesh, Nepal and Sri Lanka. It manifests as vascular friable polyps that arises from the nasal mucosa or mucosal surfaces including nasopharynx, larynx, pharynx, trachea, conjunctiva etc. and less commonly involves the skin,

conjunctiva, lachrymal sac, epiglottis, tongue, palate, vagina, bronchi etc.

### Case report:

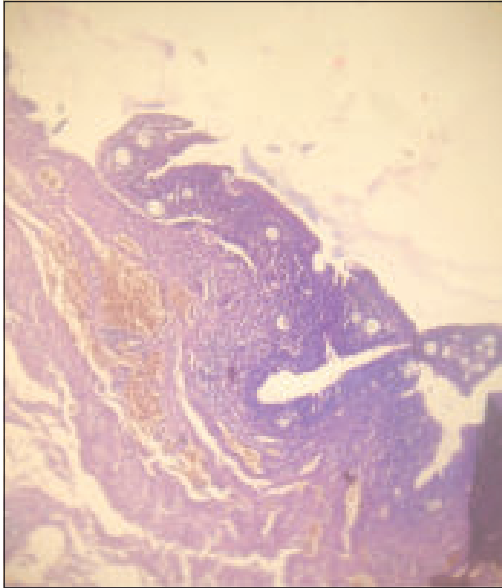
A 26-year-old male presented with painless swelling of left cheek for four months. The patient was a farmer by occupation and had a history of bathing in a pond. On examination a round fluctuant discrete swelling, 3x3 cm in diameter was palpated over the left cheek. Apparently the parotid gland seemed not to be involved. Skin overlying the swelling was unremarkable and freely mobile. Any other swelling or lymphadenopathy was not found. Overall systemic examination was normal.

Intra-oral examination revealed no abnormality. On compression the contents of the swelling were expressed which was colourless with a sour odour. Examination of ear and nose revealed no abnormality.

Under local anaesthesia, the mass was excised and duct was ligated. The mass was sent for histopathological examination [figure I & II].

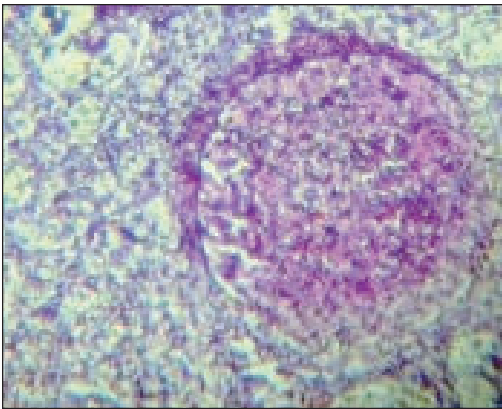
1. Senior Resident, Department of ENT, Burdwan Medical College, West Bengal, India.
2. Assistant Professor, Department of Pathology, B S Medical College, Bankura, West Bengal, India.
3. MD Pathology Postgraduate trainee, Department of Pathology, Calcutta Medical College, 88 College Street, Kolkata, West Bengal, India.
4. RMO-cum-Clinical Tutor, Department of ENT, Burdwan Medical College, West Bengal, India.

**Address of Correspondence:** Dr. Ritam Ray, 193, B.C. Road, Uttar Fatak, P.O. Rajbati, Dist: Burdwan: 713104, West Bengal, India. Phone: 919475854916. email: drritamray@gmail.com



100 X (Hematoxylin and Eosin)

**Figure 1:** Photomicrograph showing parotid duct with multiple sporangia.

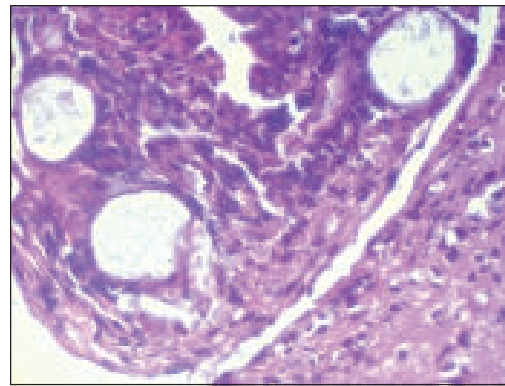


400 X (Hematoxylin and Eosin)

**Figure 2:** Photomicrography showing parotid duct lined by columnar epithelium and sporangia containing spores with adjacent stroma with chronic inflammation.

Histopathological examination revealed ducts of the parotid gland lined by columnar epithelium with sporangia of varying sizes containing numerous spores in the

underlying stroma surrounded by dense chronic inflammatory infiltrate. Subsequently, mucicarmine stain [figure III] was done which came to be positive for rhinosporidiosis spores. The patient was followed up for a period of six months which is uneventful and he is now maintaining his daily life normally.



400 X (Mucicarmine)

**Figure 3:** Photomicrograph showing positivity for mucicarmine staining.

#### Discussion:

Traditionally rhinosporidiosis has been considered to be caused by a fungus. It was first described by Guillermo Seeber from Argentina in 1900. Ashworth described the life cycle of the organism in 1923. Previously it was said that rhinosporidiosis is caused by *Rhinosporidium seeberi*. But, recently it has been proved that the causative organism is a Cynobacterium, *Microcystis aeruginosa*<sup>1</sup>. Rhinosporidiosis is endemic in south Asia, notably in southern India, Bangladesh, Nepal and Sri Lanka<sup>2</sup>.

It is commonly seen in young males. It is thought to occur through contact with stagnant water<sup>3</sup>. Bathing in infected ponds with local trauma resulting in abrasion to mucous membrane and skin may

precipitate the initiation of the disease<sup>4</sup>. Transepithelial infection through traumatised epithelium is the presumed mode of infection from the natural aquatic habitat of the organism<sup>5</sup>.

Usually it presents with epistaxis, nasal obstruction and a mass inside in nasal cavity. The mass is leaf like, pinkish, granular with strawberry like appearance and the surface studded with whitish spots. The mass is pedunculated, friable, and bleeds on touch.

Histopathologically, it is composed of vascular fibromatous structure with sporangia in various stages of maturation containing refractile spores. The Sporangium has a thick chitinous eosinophilic wall with an apical pore. Nuclear division gives rise to about 16,000 spores in a sporangium (300 mm in diameter)<sup>6</sup>.

Excision with cauterisation of base is the treatment of choice. Dapsone can be tried<sup>7</sup>.<sup>8</sup>. Recurrence is common. Most recurrences occur due to spillage of endospores on the adjacent mucosa<sup>7, 8</sup>.

#### References:

1. Ahluwalia KB, Maheshwari N, Deca RC. Rhinosporidiosis: A study that resolves etiologic controversies. *American Journal of Rhinology* 1997; 11: 479 – 83.
2. Arseculeratne SN. Recent advances in rhinosporidiosis and *Rhinosporidium seeberi*. *Indian J Med Microbiol* 2002; 20: 119 – 31.
3. Mandalik GS. A record of Rhinosporidial polyp: with some observation on mode of infection. *Indian Med. Gaz* 1937; 72: 143 – 7.
4. Satyanarayana C. Rhinosporidiosis with a record of 255 cases. *Acta Otolaryngol.* Mar 1960; 51: 348 – 66.
5. Lupi O, Tyring SK, McGinnis MR. Tropical dermatology: Fungal tropical diseases. *J. Am. Acad. Dermatol* 2005; 53: 931 – 51.
6. Al-Shehry A, Hussein MR. Rhinosporidiosis of the nose in southern region of the kingdom of Saudi Arabia *J Oral Maxillofac Pathol* 2007; 11: 83 – 5.
7. Harissi-Dagher M, Robillard N, Coriveav C, Mabon M, Allaire GS. Histopathologically confirmed ocular rhinosporidiosis in two Canadians. *Can J Ophthalmol* 2006; 41: 226 – 9.
8. M. Alamgir Chowdhury, Naseem Yasmeeen, MA Yousuf Talukder et al. Oculosporeidiosis and rhinosporidiosis in the same patient - a case report. *J Med Coll Women Hosp* 2008, 6: 47-50.