

Case Report

Bilateral Langerhans Cells Histiocytosis in the Temporal Bone: A case report

Kanu Lal Saha¹, Bishnu Pada Dey², Md. Abul Hasnat Joarder³, Mohammad Anamul Haque⁴, Bishwajit Bhowmik⁵

Abstract:

Langerhans cells histiocytosis (LCH) or histiocytosis-X is a rare group diseases that includes three overlapping diseases of Hand-Schuller-Christian disease (HSC), Letterer-Siwe disease (LS) and Eosinophilic granuloma (EG). It results from clonal proliferation of histiocytes having similar morphology and immunophenotype to Langerhans cells in skin and mucosa. Though head and neck manifestation is common, isolated simultaneous bilateral temporal bone Langerhans Cell Histiocytosis is an extremely rare presentation. Having same otological manifestations, high resolution CT scan is advocated for early identification and differentiation of LCH from other common conditions such as mastoiditis, otitis externa, chronic suppurative otitis media. Diagnosis of LCH is confirmed by biopsy and immunohistochemical staining of S-100 protein and or CD1a antigen. Chemotherapy is main mode of treatment. The prognosis is worse when presenting age of children is younger than 2 years.

-
1. Associate Professor, Department of Otolaryngology and Head-Neck Surgery, Bangabandhu Sheikh Mujib Medical University, Dhaka, Bangladesh.
 2. Professor, Department of Otolaryngology and Head-Neck Surgery, Bangabandhu Sheikh Mujib Medical University, Dhaka, Bangladesh
 3. Assistant Registrar, Department of ENT, Shaheed Tajuddin Ahmed Medical College, Gazipur, Bangladesh.
 4. Associate Professor, Department of Radiology and Imaging, Bangabandhu Sheikh Mujib Medical University, Dhaka, Bangladesh
 5. Assistant Professor, Department of Pathology, Bangabandhu Sheikh Mujib Medical University, Dhaka, Bangladesh

Address of Correspondence: Dr. Kanu Lal Saha, Associate Professor, Otolaryngology Division, Department of Otolaryngology and Head-Neck Surgery, Bangabandhu Sheikh Mujib Medical University, Dhaka, Bangladesh, Room no.702, Block-C, BSMMU, Email: drklsaha@gmail.com

Introduction:

Langerhans cells histiocytosis (LCH) or histiocytosis-X is a rare group diseases that includes Hand-Schuller-Christian disease (HSC), Letterer-Siwe disease (LS) and Eosinophilic granuloma (EG). It results from clonal proliferation of histiocytes which has similarity in morphology and immunophenotype to Langerhans cells located in the skin and mucosa.^{1,2} The Writing Group of the Histiocyte Society recommended the term LCH in 1987.³

The incidence of LCH is 5.4 per million.⁴ It may present any age but average onset of age is between 1-3 years with a male predominance.^{5,6} Though it may involve any organ head and neck is affected in about 55-73% cases.⁷

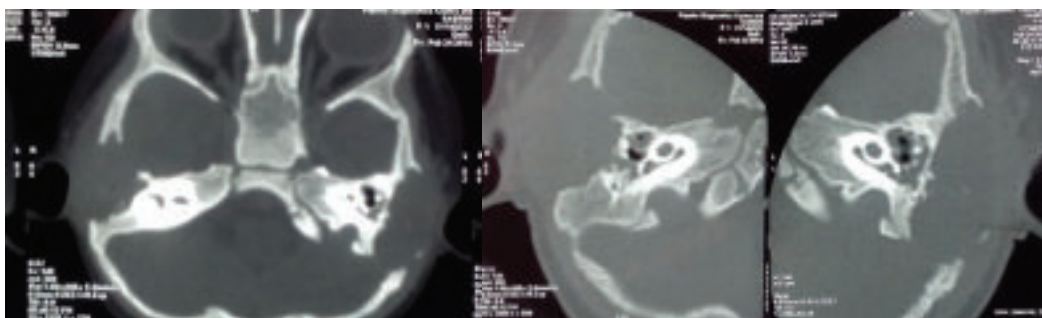
Temporal bone involvement in LCH is variable ranging from 4-61%. Bilateral

involvement is about 25-45% cases.⁸ Isolated involvement of temporal bone with SOL otologic presentation may occur. But as a component of multisystem involvement is most common in children. Bilateral simultaneous presentation of LCH in temporal bone is a rare entity. Near about 20 such cases have been reported.⁹ Here we report a another case of bilateral Langerhans' Cells Histiocytosis in the Temporal Bone.:

Case Report:

A 14 months-old girl presented in Department of Otolaryngology, Bangabandhu Sheikh Mujib Medical University, Dhaka ,Bangladesh with blood stained discharge from both ear for 4 months and swelling in both external auditory canal for same duration. Otomicroscopic examination revealed sagging of posterior meatal wall with breached surface. But tympanic membrane of both ear was visible after compressing the swelling. Both facial nerves were intact. Before attending our institution she visited in another ENT center where biopsy was taken from the external auditory canal swelling which histopatology revealed inflammatory tissue. She was anaemic but

had no other systemic illness like lymphadenopathy, hepatosplenomegaly, exophthalmous, diabetes insipidus. Her haematological testing revealed Hb% 9.8 gm /dl, erythrocyte sedimentation rate (ESR)-35 mm, Platelet – 650x10⁹/L. Computed tomography (CT) scan showed bilateral destruction of cortical temporal bone with erosion of tegmen and sigmoid sinus with soft tissue density in both middle ear and external auditory canal but inner ear appeared normal. Biopsy was taken from the right mastoid by post auricular incision under general anaesthesia. Histopathological examination demonstrated numerous histiocytic cells with grooved and lobulated nuclei. Eosinophils are also present. Histiocytes were immunohistochemically positive for S-100 protein and CD1a which is pathognomonic for LCH. Patient was referred to a paediatric haemato-oncologist. Treatment started with intravenous etoposide and oral prednisolone. Unfortunately after one month of treatment her conditions became fatal and she died. The autopsy could not be performed. Therefore the cause of death remained unclear.



a.

b.

c.

Fig.1(a),(b),(c): Shows soft tissue density lesion with punched –out bony destruction of both temporal bone causing destruction of tegmen in right and erosion of left sinus plate

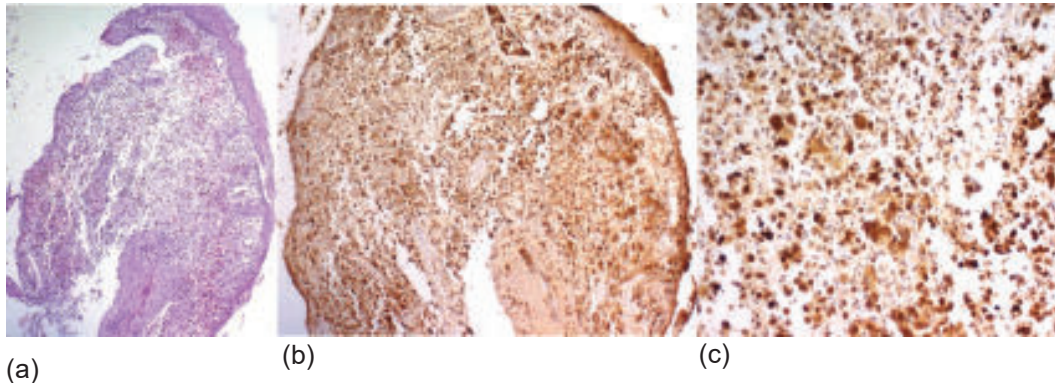


Fig. 2: (a) Low-power hematoxylin and eosin stain demonstrating numerous histiocytic cells with grooved and lobulated nuclei. Eosinophils are also present (x100). (b) Immunohistochemical stain with S-100 positivity (x100). (c) Immunohistochemical stain with CD1a positivity (x200).

Discussion:

Being a rare disease, LCH is of less Otolaryngological interest. Though head and neck presentations manifestations are common with multisystem involvement, isolated temporal bone involvement is very rare.^{9,10}

The early symptoms of LCH involving temporal bone are ear discharge occasionally mixed with blood, otalgia, hearing impairment, dizziness and postauricular swelling. The commonest local sign include granulation tissue or aural polyp in the external auditory canal. In our case the baby girl presented with ear discharge mixed with blood, post auricular swelling and granulation tissue polyp seemed to arise from posterior meatal wall.

Clinical findings in LCH of temporal bone very frequently create confusion with other common otological conditions such as otitis externa, otitis media, cholesteatoma, acute mastoiditis, malignancy of EAC etc. Temporal bone lesion is initially silent and presentation is delayed until it erodes cortical bone or posterior bony meatal wall¹¹. So early diagnosis may be missed without high index of suspicion.

The gold standard for identification and monitoring of bony LCH is high resolution computed tomography of temporal bone which elucidates characteristic lytic or punched lesion.¹² MRI is more useful in delineating soft tissue and intracranial extension. In our case CT scan showed soft tissue density lesion with punched-out type bony destruction at bilateral temporal bone. MRI was not done.

But truly no focused clinical and or radiological sign exists to confirm the definitive diagnosis of LCH⁹. Biopsy is always mandatory.¹¹ Biopsy through transmastoid approach achieves definite tissue collection for examination. Confirmed diagnosis is made on histopathological assessment and immunohistochemical detection of S-100 and or CD1 antigen.^{6,13} In this case initial biopsy from external ear canal polyp revealed inflammatory tissue. This might be due to collection error or false reporting. We collected tissue from mastoid bone through post auricular incision and histopathology revealed eosinophilic granuloma variety of LCH. Immunohistochemical staining of S-100 protein and CD1a confirmed the diagnosis of LCH.

No clear guideline for treatment is established for the treatment of LCH due to rarity of disease as well as its variable presentation.^{4,6,11} Treatment modalities include surgery, radiotherapy, chemotherapy and steroid injection. Every case is individually managed with single or combination modality depending on the extension and severity.^{4,9} Different protocols were applied between 1984 to 2007 in a center of Canada. LCH I protocol (Prednisolone and Vinblastine or Etoposide) was used in most of the cases.¹³ In our case same protocol was used. Duration of treatment varies between 6 weeks to 2 years depending upon the severity of the tumor. The worse outcome is reported when presenting age of children is younger than 2 years.^{13,14} In our case presenting age was 1 year.

Conclusion:

Simultaneous bilateral temporal bone Langerhans Cell Histiocytosis is a very rare disease. High resolution CT scan is advocated for early identification and differentiation of LCH from other otological conditions having same presentation. A definitive diagnosis of LCH is confirmed by biopsy and immunohistochemical staining of S-100 protein and or CD1a antigen. The prognosis depends chiefly on age at presentation, involvement of multiple organ systems, organ dysfunction and the patient's response to chemotherapy

References:

1. Favara BE, Feller AC, Pauli M, et al. Contemporary classification of histiocytic disorders: the WHO Committee on Histiocytic/Reticulum Cell Proliferations. Reclassification Working Group of the Histiocyte Society. *Med Pediatr Oncol* 1997;29: 157-166.
2. Jones RO, Pillsbury HC. Histiocytosis X of the head and neck. *Laryngoscope* 1984;94:1031–5.
3. Writing group of the Histiocyte Society. Histiocytosis syndromes in children. *Lancet* 1987;24(1):208–9.
4. Y Bayazit, Sirikci A, Bayaram M, Kanlikama M, Demir A, Bakir K. Eosinophilic granuloma of the temporal bone. *Auris Nasus Larynx* 2001; 28: 99–102.
5. Nicholson HS, Egeler RM, Nesbit ME. The epidemiology of Langerhans cell histiocytosis. *Hematol Oncol Clin North Am.* 1998;12:379-384.
6. Bezdjian A, Alarfaj AA, Varma N, Daniel SJ. Isolated Langerhans Cell Histiocytosis Bone Lesion in Pediatric Patients: Systematic Review and Treatment Algorithm. *Otolaryngology–Head and Neck Surgery* 2015;153:751-757.
7. Nicollas R , Rome A , Belaich H, Roman S, Volk M, Gentet JC, Michel G, Triglia JM. Head and neck manifestation and prognosis of Langerhans' cell histiocytosis in children. *Int J of Pediatr Otorhinolaryngology* 2014;78:1874–1876.
8. Majumder A, Wick C C, Collins R, Booth TN, Isaacson B, Kutz JW. Pediatric Langerhans cell histiocytosis of the lateral skull base. *Int J of Pediatr Otorhinolaryngology* 2017; 99:135–140.
9. Kleinjung T, Woenckhaus M, Batchthaler M, Wolf JEA, Wolf SR. Langerhans' Cell Histiocytosis with Bilateral Temporal Bone Involvement. *Am J Otolaryngol* 2003, 24: 265-270.
10. McCaffrey TV, McDonald TJ: Histiocytosis -X of the ear and temporal

- bone: Review of 22 cases. *Laryngoscope* 1979; 89:1735-1742.
11. Yetiser S, Karahatay S, Deveci S. Eosinophilic granuloma of the bilateral temporal bone. *Int J Pediatr Otorhinolaryngol* 2002;62:169-173.
 11. Coleman MA, Matsumoto J, Carr CM, Eckel LJ, Rao AAN. Bilateral Temporal Bone Langerhans Cell Histiocytosis: Radiologic Pearls. *The Open Neuroimaging Journal* 2013; 7:53-57
 12. Saliba I, Sidani K, El Fata F, et al. Langerhans' cell histiocytosis of the temporal bone in children. *Int J Pediatr Otorhinolaryngol* 2008;72: 775-86.
 13. Postini AM, Andreacchio A, Boffano M, et al. Langerhans cell histiocytosis of bone in children: a long-term retrospective study. *J Pediatr Orthop B* 2012; 21(5): 457-62.