

## Original Article

---

# Outcome of Interlay Type 1 Tympanoplasty for Large Central Perforation

Md. Mahmudul Huq<sup>1</sup>, S.M. Mostofa Qaiyoum<sup>2</sup>, Md. Saifullah Ibne Mannan<sup>3</sup>,  
Md Kamruzzaman<sup>4</sup>

### Abstract:

**Background:** Perforation of the tympanic membrane may occur from various reasons. Most of these perforations heal spontaneously, whereas the remaining long-standing perforations that lead to recurrent ear discharge need tympanoplasty. Interlay Type 1 Tympanoplasty, a newer technique has shown promising results with higher success rate in terms of hearing gain and graft uptake.

**Objective:** To analyze the results of interlay Type 1 Tympanoplasty in terms of graft uptake and hearing improvement in cases of inactive mucosal chronic otitis media (COM) with large central perforation.

**Methods:** This is a prospective study of 24 months (January 2018 to December 2019) duration conducted in department of E.N.T, Khulna medical college, Khulna and data was collected from the 60 patients admitted for tympanoplasty. Results were calculated in terms of graft accepted or rejected and decrease in air bone gap.

**Result:** The graft uptake rate in the present study was found to be 91.67% and the patients reported an improvement in terms of hearing. Pre operatively mean air bone gap was 26.5dB and post operatively after 12 weeks mean air bone gap improved to 17.58dB.

**Conclusion:** Interlay Type 1 Tympanoplasty is an effective technique over conventional methods in terms of both graft uptake as well as hearing improvement in large central perforation

**Keywords:** Chronic Otitis Media, Interlay, Type 1 Tympanoplasty, Graft uptake.

1. Assistant Professor, Department of Otolaryngology and Head-Neck Surgery, Khulna Medical College, Khulna.
2. Assistant Registrar, Department of Otolaryngology and Head-Neck Surgery, Khulna Medical College, Khulna.
3. DLO Course Student, Khulna medical college, Khulna
4. Professor & Head, Department of Otolaryngology and Head-Neck Surgery, Khulna Medical College, Khulna.

**Address of Correspondence:** Dr. Md. Mahmudul Huq, Assistant Professor (ENT), Department of Otolaryngology and Head-Neck Surgery, Khulna Medical College, Khulna, Email: mahmudent72@gmail.com Contact: 01912544807

### Introduction:

Chronic otitis media (COM) is a major health problem in a developing country like Bangladesh, especially in low socio economic strata (prevalence >10%). COM has a major impact on the social life of a person in the form of hearing disability<sup>1</sup>. The discharge from the ear is also troublesome causing great discomfort to the patient.

Perforation of the tympanic membrane primarily results from middle ear infections, trauma or iatrogenic causes. Up to 80% of these perforations heal spontaneously<sup>2</sup> For the remaining, surgical repair, known as tympanoplasty, is usually proposed.

Tympanoplasty is a procedure done to repair the defect in the tympanic membrane after eradicating all the disease in the middle ear cleft with or without reconstruction of ossicular chain<sup>3</sup>. Type I tympanoplasty is a surgical technique that involves the repair of the tympanic membrane in cases where the only existing lesion is a tympanic membrane perforation. It is the most common otological procedure after myringotomy<sup>4</sup>.

Tympanoplasty is one of the most commonly done otological procedure. It was introduced by Berthold and further developed by Wullstein and Zollner<sup>5-7</sup>.

Many techniques of myringoplasty are described in the literature. A few of the numerous techniques include Underlay<sup>8</sup>, Overlay<sup>9</sup>, Inlay<sup>10</sup>, and Interlay<sup>11</sup>.

It is classified based on the placement of graft in relation to the remnant tympanic membrane as:

- a. Underlay technique—graft is placed medial to the mucosal layer.
- b. Overlay technique—graft is placed lateral to the fibrous layer of tympanic membrane after elevating all squamous epithelium.
- c. Interlay technique—graft is placed between fibrous and the endothelial (mucosal) layer of the drum remnant<sup>12</sup>.

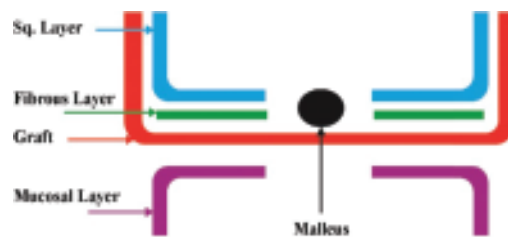
Each technique has its advantage as well as disadvantage. Some of the workers are of the view that overlay technique is more useful in repairing large and anterior perforation while Underlay technique is ideal for posterior perforation<sup>13</sup>.

Underlay technique is considered technically easier, less time-consuming and has shown to be having higher success rate<sup>14</sup>.

Interlay technique has many advantages upon the underlay and overlay technique. In it the

graft is kept in between the mucosal and the fibrous layers which eventually grow on the inner and the outer surface of the graft leading to closure of the perforation. Thus this mucosal and fibrous layer plane is the most physiological plane for keeping the graft layer thus contributing to the following advantages:

- a. There is no blunting, as the anterior sulcus is skin lined.
- b. No lateralization, as the graft is placed medial to malleus and fibro-squamous layer.
- c. No epithelial cyst formation.
- d. No medialization.
- e. Can clear tympanosclerosis from anterosuperior quadrant easily.
- f. Myringitis due to endothelium overgrowth on the graft is avoided.
- g. No reduction in middle ear space.
- h. The Interlay approach has shown promising results with success rates higher than 90%<sup>15-17</sup>.



#### Aims and Objectives:

- 1) To evaluate the results of type 1 tympanoplasty by interlay technique
- 2) To assess the uptake of graft
- 3) To assess the hearing improvement
- 4) To study complications associated with interlay technique

#### Methods:

##### Study design and setting

The present study is a randomized prospective study of 24month duration from

January 2018 to December 2019 in 60 patients of chronic otitis media inactive mucosal type with large central perforation admitted in the E.N.T department at Khulna Medical College and Hospital, Khulna. The study was conducted after getting ethical clearance from the Ethical committee. Patients and the attendants were informed and counselled regarding the disease process, surgical procedure involved and the expected outcomes, complications and alternative treatments available. Written and informed consent was taken from the patient as well as the attendant.

**Study period:** The duration of study was two years from January 2018 to December 2019. The follow up period was 3 months.

**Sample size:** 60 patients from the outpatient department of E.N.T at the Khulna Medical College and Hospital, Khulna. Results were calculated in terms of graft take up rate and hearing improvement.

**Inclusion criteria:** Cases of chronic otitis media with inactive mucosal disease with a large central perforation and pure conductive hearing loss were included in the study. The ear was dry for at least 6 weeks. Both males and females in the age group of 15 to 60 years of age were included in the study.

**Exclusion criteria:** Following patients were excluded from the study- Patients with active mucosal disease; patients with squamous disease; patients with ossicular discontinuity/necrosis; patients with sensorineural and mixed hearing loss; patients below 15 years and above 60 years were excluded from the study; patients with diabetes mellitus, patients with active focus of infection in throat, nose and oral cavity; patients with recurrent disease (revision cases); patients who fail to follow-up for at least 3 months.

**Procedure:** All cases of Chronic Otitis Media with large central perforation and conductive

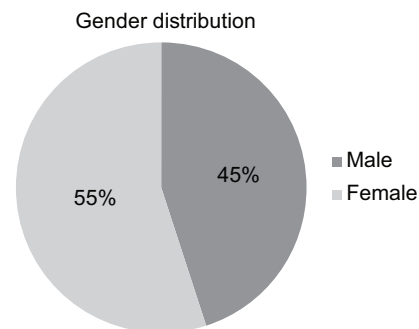
hearing loss (After diagnosing by Pure Tone Audiometry and Otomicroscopy) were admitted in the E.N.T. ward, relevant history, clinical findings, tuning fork tests, routine investigations along with X-Ray mastoid and Diagnostic Nasal Endoscopy (DNE) were carried out. Pre-operatively all patients had a Pure Tone Audiogram with an average of four frequency (0.5/1/2/4 Khz) calculated for both air conduction and bone conduction. Post auricular approach and temporalis fascia was used as a graft material in techniques of tympanoplasty under local Anesthesia.

### Results:

The present study comprised of total 60 patients of which 27(45%) were male and 33(55%) were female patients. The age of the patients ranged from 17 to 60 years, with the mean age group 32.53 years with standard deviation 9.37. Maximum number of patients were in the age group of 21 to 30 years.

**Table-I:**  
Age distribution of the patients.

Age group (years)	Number of patients	Percentage (%)
17-20	6	10
21-30	24	40
31-40	20	33.33
41-50	8	13.33
51-60	2	3.33
Total	60	100

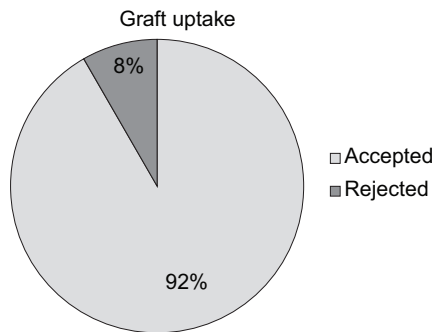


The preoperative air-bone gap (ABG) was between 11-20 dB in 10(16.67%) patients, 21-30 dB in 35(58.33%) patients and 31-40 dB in 15(25%) patients, with the mean ABG being 26.5dB with standard deviation of 6.98 as shown in table II.

**Table-II :**  
*Preoperative air bone gap of the patients*

Pre operative ABG(dB)	Number of patients	Percentage (%)
<10	0	0
11- 20	10	16.67
21-30	35	58.33
31- 40	15	25

Post operatively graft accepted in 55(91.67%) patients while graft rejection was observed in 5(8.33%) patients at the end of 12 weeks as shown in figure-1.

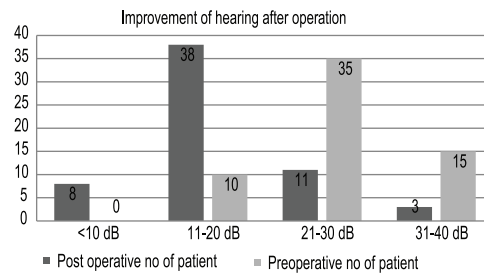


**Figure 1**

At the end of 12 weeks the post-operativemean ABG was reduced to 17.58dB with standard deviation6.88and the postoperative ABG changing to less than 10 dB in 8(13.33) patients, between 11 and 20 dB in 38(63.33) patients and between 21 and 30dB in 11(18.33%) patients andno improvement in 3(5%) patients, all of which were statistically significant.

**Table-III :**  
*Postoperative air bone gap of the patients.*

ABG(dB)	Number of Post-operative patients	%
<10	8	13.33
11-20	38	63.33
20-30	11	18.33
31-40	3	5



**Figure 2**

**Table-IV :**  
*Complications*

Complications	Number of patients	Percentage (%)
Graft medialization	0	
Graft lateralization	0	
Perforation	5	8.33
Post aural wound infection	1	1.66
Partial flap necrosis	1	1.66
Granular myringitis	0	
Alteration of test	0	
<b>Total</b>	<b>7</b>	<b>11.66</b>

**Discussion**

Bangladesh is one of the countries with highest load of chronic otitis media<sup>18</sup> It is important being a curable cause of deafness. It is mostly the end result of acute otitis media and is characterized by deafness and

persistent discharge from the middle ear through a tympanic membrane perforation.

Tympanoplasty is the operative procedure performed to repair the perforation in ear drum by repairing the tympanic membrane<sup>6</sup>. It is a beneficial procedure to protect the middle ear and inner ear from future damage. Improvement in hearing sensitivity is also observed<sup>19</sup>.

Tympanoplasty has come a long way after it was first introduced by Wullstein and Zollner in the early 1950s<sup>20</sup> as there was a constant desire to improve the technique as well as outcomes. In the past few years, interlay technique of tympanoplasty has gained a lot of popularity and has emerged as the preferred approach because of its low incidence of complications and promising results.

In the present study, the graft uptake rate was found to be 91.67% which is in accordance with study by Kawatra et al<sup>21</sup> who reported success rate of 93.3% and is slightly better than study conducted by Hay et al<sup>22</sup> on 116 ears who found success rate of 91%.

Jain S et al<sup>23</sup> studied 500 cases and reported the success rate of 96.6 and Patil et al<sup>12</sup> reported 96% which is slightly better than our results. Komune S et al<sup>11</sup> studied interlay myringoplasty in 69 ears and achieved success rate of 94.2%.

In the present study mean ABG changed from 26.5 dB preoperatively to 17.58 dB post operatively at the end of 12 weeks.

In study by Subramanya et al<sup>24</sup> mean ABG changed from 28.5 dB preoperatively to 15.83 dB post operatively. In study by Jain S et al<sup>23</sup> the mean ABG was  $26.08 \pm 8.32$  dB and mean postoperative ABG reducing to  $10.12 \pm 5.84$  dB. In the study by Kawatra et al<sup>21</sup> ABG improved from 27.50 dB preoperatively to 13.67 dB postoperatively after 16 weeks and in study by Patil et al<sup>12</sup> the mean preoperative

ABG was  $36.42 \pm 12.01$  dB which improved to  $9.7 \pm 6.71$  dB at the end of 3rd month.

In the present study Only 5 (8.33%) patients had graft failure. There was no improvement in hearing in 3(5%) patients. Complication Occur in 7(11.66%) patients which is consistent with the study by Patil et al<sup>12</sup>.

### Conclusion:

Although interlay Type 1 tympanoplasty technique requires additional expertise in surgery, it is an effective technique over conventional methods like overlay or underlay for graft uptake and hearing gain in large central perforation. The complications associated with this are less as compared to other techniques. This study indicates interlay is the best approach for chronic otitis media with large central perforation of mucosal variety.

### References:

1. Matsuda Y, Kurita T, Ueda Y, Ito S, Nakashima T. Effect of tympanic membrane perforation on middle-ear sound transmission. *J Laryngol Otol*, 2009;123:81–89.
2. Galdstone HB, Jackler RK, Varav K. Tympanic Membrane Wound Healing. An Overview. *Otolaryngol Clin North Am*, 1995;28:913–932.
3. Castro-Sismanis A. Tympanoplasty: tympanic membrane repair. *Glasscock-Shambaugh Surgery of the ear*, 6th edn. Peoples Medical Publishing House, Shelton. 2010;465-488.
4. Castro O, Pérez-Carro AM, Ibarra I, Hamdan M, Meléndez JM, Araujo A, Espina G. Myringoplasties in children: our results. *Acta Otorrinolaringologica (English Edition)*, 2013 Mar 1;64(2): 87-91.
5. Berthold E. Overlay myringoplasty. *Wier Med Bull*. 1878;1:627.

- 6 Wullstein H. Theory and practice of tympanoplasty. *Laryngoscope*, 1956; 66:1076-1093.
- 7 Zollner F. The principles of plastic surgery of the sound-conducting apparatus. *J Laryngol Otol*, 1955;69: 637-652
- 8 Shea JJ Jr. Vein graft closure of eardrum perforation. *J Laryngol Otol*, 1960;74: 358-362.
- 9 House WF. Myringoplasty. *Arch Otolaryngol*, 1960; 71: 399-404.
- 10 Eavey RD. Inlay tympanoplasty: cartilage butterfly technique. *Laryngoscope*, 1998; 108:657-661.
- 11 Komune S, Wakizono S, Hisashi K, Uemura T. Interlay method for myringoplasty. *AurisNasus Larynx*, 1992 Jan;19(1):17-22.
- 12 Patil BC, Misale PR, Mane RS, Mohite AA. Outcome of interlay grafting in type 1 tympanoplasty for large central perforation. *Indian Journal of Otolaryngology and Head & Neck Surgery*, 2014 Dec 1;66(4):418-424.
- 13 Kartush JM, Michaelides EM, Becvarovski Z, LaRouere MJ. Over under tympanoplasty. *The Laryngoscope*, 2002 May;112(5):802-807.
- 14 Singh M, Rai A, Bandyopadhyay S, Gupta SC. Comparative study of the underlay and overlay techniques of myringoplasty in large and subtotal perforations of the tympanic membrane. *The Journal of Laryngology & Otology*, 2003 Jun;117(6):444-448.
- 15 Guo M, Huang Y, Wang J. Report of myringoplasty with interlay method in 53 ears perforation of tympani. *Lin chuanger bi yanhoukezazhi. Journal of clinical otorhinolaryngology*, 1999 Apr;13(4):147.
- 16 Vishal US. A one-year prospective study to evaluate the results of superiorly based tympanomeatal flap in endoscopic myringoplasty conducted in district hospital, belgaum and KLES hospital and MRC, Belgaum during july 2003 to june 2004. Dissertation, MS(ENT), 2006.
- 17 Hay A, Blanshard J. The anterior interlay myringoplasty. outcome and hearing results in anterior and subtotal tympanic membrane perforations. *Otology & Neurotology*, 2014 Oct 1;35(9):1569-1576.
- 18 Acuin J. Chronic Suppurative Otitis Media, Burden of illness and management options, WHO Child and Adolescent Health Department, Geneva, 2004.
- 19 Hussain A, Yousaf N, Khan AR. Outcome of Myringoplasty. *J Postgrad Med Inst*, 2004;18:693-696.
- 20 Primrose WJ, Kerr AG. The anterior marginal perforation. *ClinOtolaryngol Allied Sci*, 1986;11:175 176.
- 21 Kawatra R, Maheshwari P, Kumar G. A comparative study of the techniques of myringoplasty Overlay, underlay & interlay. *IOSR J Dent Med Sci*, 2014; 13:12-16
- 22 Hay A, Blanshard J. The anterior interlay myringoplasty: Outcome and hearing results in anterior and subtotal tympanic membrane perforations. *Otol Neurotol*, 2014 Oct;35(9):1569-1576.
- 23 Jain S, Gupta N, Gupta R, Roy A. Interlay Type I tympanoplasty in large central perforations: Analysis of 500 cases. *Indian J Otol*, 2017; 23:32-35
- 24 Subramanya BT, Lohith S, Sphoorthi B. Interlay myringoplasty: hearing gain and outcome in large central tympanic membrane perforation. *Tropical journal of ophthalmology and otolaryngology*, 2018;3(3):51-56.