



Article info

Received : 05-07-2022
Accepted : 03-03-2023
No. of Tables : 03
No. of Figure : 03
No. of References : 12

Original Article

Comparative Study of Temporalis Fascial Graft Medial or Lateral to Handle of Malleus in Tympanoplasty

Debnath TK¹, Hazari A², Arefeen S³, Rahman W⁴, Datta AK⁵, Abdus Sama A⁶

Abstract:

Objective: To compare the hearing outcome and healing of Temporalis fascia graft in both groups by placing the graft medial (underlay technique) or lateral to the handle of malleus (over- underlay technique).

Method: This retrospective study conducted for a period January, 2018 to December 2019- Two years period in Specialized ENT Hospital (SENTH) of SAHIC (Society for assistance to hearing impaired Children), Dhaka. It includes 104 patients, Group-A 59 patients (Underlay technique) and Group-B 45 patients (Over-underlay technique).

Result: Graft success rate overall 84.62%, Group-A- 84.75% (Medial to malleus) and Group-B- 84.44% (lateral to malleus). Pre- and post- operative air- bone gap of two groups were compared.

Conclusion: Both techniques (medial or lateral to malleus handle) has a high rate of success for the closure of TM perforation with significant improvement in air-bone gap.

Key words: Tympanoplasty, Graft placement, Temporalis fascia.

Bangladesh J Otorhinolaryngol 2023; 29(1): 17-23

Cite the Article: Debnath TK, Hazari A, Arefeen S, Rahman W, Datta AK, Abdus Sama A. Comparative Study of Temporalis fascia graft medial or lateral to handle of malleus in Tympanoplasty in Specialized ENT Hospital (SENTH) of SAHIC. Bangladesh J Otorhinolaryngol 2023; 29(1): 17-23

Introduction:

Chronic Otitis media (COM) with perforation of tympanic membrane is a common cause of hearing loss and ear discharge. A large

proportion of the patients in our country have safe (mucosal) variety. It leads to otorrhea and deafness which hampers productivity of many individuals. Otolaryngologist play an

1. Dr. Timir Kumar Debnath, Consultant, Specialized ENT Hospital (SENTH) of SAHIC, Mohakhali, Dhaka.
2. Dr. Aslam Hazari, Associate Consultant, SENTH of SAHIC.
3. Dr. Shahinur Arefeen, Associate Consultant, SENTH of SAHIC.
4. Dr. Wakilur Rahman, Junior Consultant, SENTH of SAHIC.
5. Dr. A.K. Datta, Consultant, SENTH of SAHIC.
6. Abdus Samad, Senior Consultant, SENTH of SAHIC, Mohakhali, Dhaka.

Address of Correspondence: Dr. Timir Kumar Debnath, Consultant, SAHIC, Mohakhali, Dhaka. E mail- debnathtimir56@gmail.com.

important role in correction and amelioration by conservative or operative procedures. One such procedure is Tympanoplasty. Tympanoplasty refers to any operation involving reconstructions of the Tympanic membrane and/or the ossicular chain. Myringoplasty is a Tympanoplasty without ossicular reconstruction.¹

The two classic techniques that have been developed are the underlay and overlay technique procedures. The most widely used is the relatively simple underlay technique in which the graft is placed entirely medial to the remaining drum and malleus. In the overlay technique the graft is placed lateral to the annulus and any remaining fibrous middle layer after the squamous layer has been carefully removed. A new technique that has evolved from the two classical techniques of overlay and underlay and aimed at eliminating the disadvantages of these techniques is over-underlay myringoplasty. In these technique, graft is placed lateral (over) the handle of malleus but medial (under) the Tympanic membrane remnant and annulus⁴. Various graft materials are used for Tympanoplasty, Temporalis fascia is most commonly used.²

Prevalence of COM is estimated to be 0.5-30% in different population and there are about 120 million patients with COM around the world. Essential treatment of COM is by surgical procedures to eliminate disease, prevention of recurrence and maintain or improve hearing. About 70,000 "Tympanoplasty" and "Mastoidectomy" operations have been performing annually in USA.³

In this study the two methods of Tympanoplasty (graft placed to medial and lateral to malleus handle) were compared.

Aims and objectives:

To compare the graft success rate and hearing improvement by the temporal fascia graft medial (underlay technique) or lateral to handle of malleus (over-underlay technique).

Materials & Methods:

A retrospective study conducted for a period of January, 2018 to December, 2019. It included 104 patients which was conducted at Specialized ENT Hospital (SENTH) of SAHIC (A tertiary care medical Centre) in Dhaka, Bangladesh. All patients underwent preoperative & postoperative audiogram. They were randomly allocated into two groups, Group- A 59 patients and Group-B 45 patients. In group-A- the temporalis fascia graft was placed medial to the handle of malleus (underlay technique) while in group –B the graft was placed lateral to the handle of malleus but medial to the remnants of the tympanic membrane or fibrous annulus (over-underlay technique). The two groups were followed up for 6 months post-operatively.

Intervention: Medial or Lateral to malleus underlay Tympanoplasty.

Patients:

All the patients assigned to informed consent. The study was approved by SAHIC (Society for assistance to Hearing impaired Children) Ethics committee. There was no financial conflict of interest.

At the beginning demographic data (age, sex, past medical illness) clinical exam. and Otoscopic feature were registered in a form. The main outcome measures were drum status (full take, perforation, or atelectasis), change in hearing and the incidence of complication. A review of graft take and delayed TM problem (later perforation or atelectasis was recorded). Graft take was defined as full, intact healing of the TM graft at least 6 months post operatively. Delayed TM problems were defined as perforation or atelectasis that occur after 6 months. Changes of air-bone gap revised pre & post operatively. Air-bone gap was calculated as the average difference between air conduction & bone conduction at 0.5, 1, 2 & 4 KHz. Hearing result were based on the most recent audiograms available at least 6 months post operatively. Data enter in to SPSS version

24...an analyzed and statistical test has been performed.

Inclusion criteria:

- a. Intact & mobile ossicular chain were evaluated
- b. 15- 60 yrs. old
- c. Mucosal type COM

Exclusion criteria:

- a. Ossicular discontinuity/ fixation
- b. Ossicular chain reconstruction
- c. Less than 15yrs & more than 60 yrs. old
- d. Presence of SNHL
- e. CSOM with cholesteatoma
- f. Traumatic perforation
- g. Neoplastic perforation

Main outcome measures:

1. Change in air- bone gap and bone conduction thresholds.
2. Tympanic membrane lateralization
3. Primary to delayed graft failure.

Surgical technique (Intervention):

The procedure was performed under local anesthesia with intravenous sedation or general anesthesia (few cases).

Incision—postauricular.

Graft—Temporal fascia.

Freshening of perforation margin.

Posterior tympanomeatal flap elevated and the entire drum remnant was elevated off the long process of the malleus using micro dissection.

- The anterior annulus was not elevated in all cases.
- When clinically indicated canal wall up mastoidectomy was performed.

Pure tone audiometry (PTA) was done after 3 months post- operative period.

Results:

Group A- medial to malleus (underlay technique) in 59 patients and Group-B – lateral to malleus (over-underlay technique) in 45 patients.

1. The patient ages ranged from 15 to 60 years, with an average 26.26 ± 9.73 years.
2. 63 patients (52%) were females and 41 patients (48%) were males
3. 38.46% (40) had perforation size ($\leq 50\%$) while 61.54% (64) had perforation size ($> 51\%$). In Group- A 24 patients had ($\leq 50\%$) perforation and 35 patients had ($> 51\%$) perforation. In Group- B 16 patients had ($\leq 50\%$) perforation and 29 patients had ($> 51\%$) perforation. (Table- 2).
4. The mean pre-operative average air-bone gap was 18.96 ± 2.62 dB in Group- A(medial to malleus) and post-operative AB gap 7.81 ± 2.04 Db, AB gap closure was 11.15 ± 2.33 dB In the Group- B (lateral to malleus) the mean pre-operative average AB gap 21.36 ± 3.6 dB and post-operative AB gap 9.38 ± 1.56 dB, post-operative AB gap closure 11.31 ± 2.70 dB There is no statistically significant difference between two groups medial or lateral to malleus about graft success & Hearing improvement
5. Graft success rate in our study, was 84.62% with total graft success rate. Overall success rate in Group- A in 84.75% and 15.25% failure (6.78% not intact, 3.39% myringitis, 5.08% retraction) . Success rate in Group- B 84.44% and 15.56% failure (6.67% not intact, 2.22% myringitis, 6.67% retraction).

Table-I : Distribution of patient age by group

Age in years	Group-A		Group-B		All	
	#	%	#	%	#	%
<18 years	17	28.81	8	17.78	25	24.04
18-30 years	22	37.29	20	44.44	42	40.38
31 and above	20	33.90	17	37.78	37	35.58
Total	59	100.00	45	100.00	104	100.00
Mean (SD)	25.37 (9.79)		27.42 (9.64)		26.26 (9.73)	
Minimum	9		13		9	
Maximum	45		51		51	

Table-II: Distribution of perforation size by group

Size	Group-A		Group-B		All	
	#	%	#	%	#	%
<=50 %	24	40.68	16	35.56	40	38.46
>51%	35	59.32	29	64.44	64	61.54
Total	59	100.00	45	100.00	104	100.00
Mean (SD)	64.15 (19.96)		62.33 (15.24)		63.37 (18.01)	

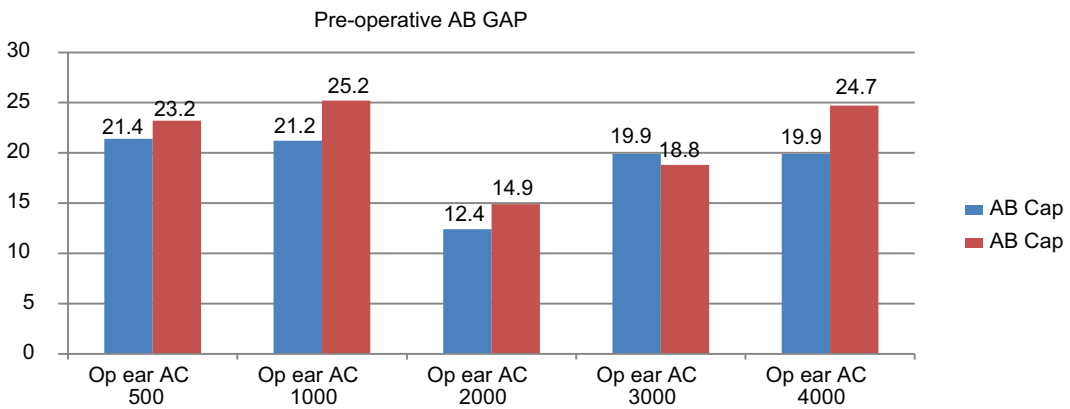


Fig.-1: Pre- operative air- bone gap among study groups :

Table-III : Distribution of otoscopic appearance by group

Status	Group-A		Group-B		All	
	#	%	#	%	#	%
Intact	50	84.75	38	84.44	88	84.62
Not intact	4	6.78	3	6.67	7	6.73
Myringitis	2	3.39	1	2.22	3	2.88
Anterior blunting	0	0.00	0	0.00	0	0.00
Atelectasis	0	0.00	0	0.00	0	0.00
Retraction	3	5.08	3	6.67	6	5.77
Lateralization	0	0.00	0	0.00	0	0.00
Meatal stenosis	0	0.00	0	0.00	0	0.00
Complete collapse	0	0.00	0	0.00	0	0.00
OME	0	0.00	0	0.00	0	0.00
Not assessed	0	0.00	0	0.00	0	0.00
Normal	0	0.00	0	0.00	0	0.00
Total	59	100.0	45	100.0	104	100.0

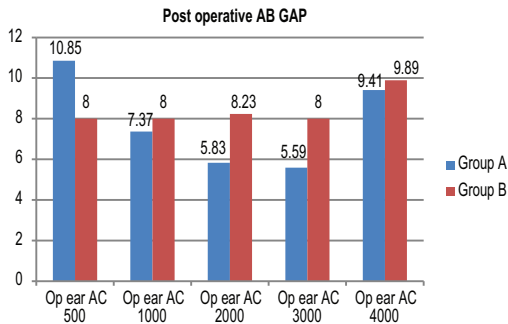


Fig.-2: Post-operative air-bone gap among study groups

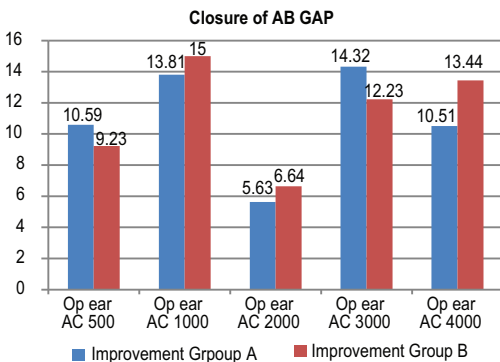


Figure-3: Post-operative air-bone gap closure among study groups

Discussion:

Repair of TM defects aims to achieve anatomic and functional success and to maintain these properties over time. The absence of an adequate residual TM in subtotal or total TM perforation remains a challenge to Otolaryngologist⁵. Karela reported on a series of 211 patients who underwent underlay myringoplasty for perforations of any size and site, achieving a 91.5% success rate and a 14.67dB mean improvement in hearing function in 91.5% of the patients. These authors stated that myringoplasty can improve hearing independent of the site and size of perforation, and suggest that the hearing improvement can be used as an indication for myringoplasty⁶. In a study of 100 patients with dry central perforation have been chosen for Tympanoplasty type- 1 by underlay technique. Exclusion criteria were strictly followed, only patients with unilateral dry central perforation were included in the study and surgery was

carried out to maintain uniformity. The patients have been divided into two groups of equal numbers. The perforation was closed by placing the graft medial to malleus in Group-A and lateral to malleus in Group-B. The mean hearing improvement in dB among the two groups was 6.34 dB among medial to malleus technique group and 6.8dB in lateral to malleus technique group ⁷. In another retrospective study in Turkey, 104 patients, underwent Tympanoplasty (via underlay technique in 46 patients and over- under technique in 58 patients). In the first group of patients with underlay technique (the graft was placed medial to the remaining drum and manubrium), the success rate was 91.5%. In the second group with over-under technique (the graft was placed over the malleus and under the remaining drum), the success rate was 94.9%. In the patients operated by the underlay technique, the air bone gap decreased by 16.55dB. This rate was 16.96 dB in those operated via the over- under technique ⁸.

In another study in Michigan Ear institute, the chosen technique had been over-under Tympanoplasty which was performed by placing the graft over the malleus and under the annulus. All their 120 patients had successful grafts, there was no lateralization of the grafted drum. Seventeen patients had late atelectasis, and 12 patients had late perforations; nearly all of these were noted more than 1 year after surgery and were attributed to persistent Eustachian tube dysfunction or infections. Average improvement in air-bone gap for all patients was 5.3 dB, where as speech reception threshold improved by 5.9dB ⁴.

The study of Jung concluded medial graft Tympanoplasty is suitable for posterior TM perforation, and medio-lateral graft method is excellent for the reconstruction of large anterior or subtotal perforation ⁹.

In study by Fiorino in Italy, 78- umbo-anchored over- under myringoplasties were done. They used a large graft with radial slit distended under the TM and annulus, and the two tongues were positioned to surround the umbo area and overlapped under a non-perforated portion of the TM. Graft take was obtained in 91% of cases and the auditory result showed an average residual air- bone gap of 6.7dB.¹⁰

In a Egyptian study, Graft success rate was 83.33% with total graft success . 86.7% with under- underlay technique with only 13.3% graft failure rate . Comparing this with over-underlay technique, 80.0% of patients had full graft take whereas only 20.0% had graft failure¹¹. In another study, the graft success rate of tympanoplasty performed using the underlay technique was 89.1 % in 61 patients. Seven (10.9 %) patients had graft failure. The graft success rate with the over-underlay technique in 53 patients was 90.5 %. Five (9.5 %) patients had graft failure in this group. Three graft lateralization (5.6 %) and two retractions (3.8 %) at 12 months postoperatively in the over-underlay group were observed; however, in the underlay group, no graft lateralization were identified, but five retractions (8.2 %) were observed at 12 months postoperatively. The audiometric tests performed at 12 months postoperatively revealed that the ABG was 12.1 ± 5.5 dB HL in underlay group and Mean ABG was 13.3 ± 6.4 dB HL in over-underlay group ¹².

In our study graft success rate was 84.62% with total graft success rate. Overall success rate in Group- A in 84.75% and 15.25% failure (6.78% not intact, 3.39% myringitis,5.08% retraction) . Success rate in Group- B 84.44% and 15.56% failure (6.67% not intact, 2.22% myringitis,6.67% retraction). Post-operative audiometric test revealed AB gap closure in Group-A– 11.15 ± 2.33 dB (medial to malleus) and Group- B 11.31 ± 2.70 dB (

lateral to malleus). The difference between this two groups was not statistically significant among graft success rate and PTA result.

Conclusion:

Outcomes of both techniques were successful and consistent with in the literature. The technique of Tympanoplasty with graft placed lateral to malleus give same result as those placed medial to malleus (Classic technique).

References:

1. George G. Browning, Chronic otitis media. Scott-brown's Otolaryngology, head & neck surgery, 7th edition 2008; 237: 3421-22.
2. Tos Mirko, Manual of middle ear surgery; Approaches, Myringoplasty, Ossiculoplasty and Tympanoplasty, 3rd edition, 1993; 107-10.
3. Merchant SN. Ossiculoplasty and Tympanoplasty in chronic otitis media. In: Nadol JB Mckenna MJ surgery of the Ear and Temporal Bone. 2nd ed.USA: Lippincort Williams and wilkins: 2005: 306-25.
4. Kartush JM, Michaledes EM, Becvarovskiz, LaRuere M. Over-under Tympanoplasty. Laryngoscope 2002; 112: 802-807.
5. Adkins WY, White B. Type I tympanoplasty: influencing factors, laryngoscope. 1984; 94: 916-918.
6. Karela M, Sandeep B, Watkins A et al. Myringoplasty : Surgical outcomes and hearing improvement ; is it worth performing to improve hearing? Ear Arch Otorhinolaryngol., 2008; 265:1039-1042.
7. Durga Prasad VN, Kaz Ap. Underlay technique of Myringoplasty- Easier and Faster method of placing lateral to handle of malleus- How effective and successful? Ear Arch Otorhinolaryngol 2018; Doi: 10.9790/0853-1711085188.
8. Yigit O, Alkan S, Topuz E, Uslu B, Unsal O, Dadas B : Short- term evaluation of over-under Myringoplasty technique , Ear Arch Otorhinolaryngol 2005 ; 262:400-403.
9. Jung T, KimYH,Park SK, Martin D. Medial or medio-lateral graft tympanoplasty for repair of tympanic membrane perforation. Int. J Paed. Otorhinolaryngol, 2009 ;73: 941-943.
10. Fiorino F, Barbien F. Over- under' myringoplasty with umbus- anchored graft . J laryngogol otol. 2008;122: 854-857.
11. W.H. Abo, El waf, I.I. El Dooks. Comparison of Temporalis fascia graft medial and lateral to handle of malleus in Dry central Tympanic membrane perforation. The Egyptian Journal of Hospital medicine (April 2019); 75(2): 2241-2244.
12. E. Kulduk, R. Dunder, F. Kemalsay, O. K. Yudias. Treatment of large Tympanic membrane perforation : medial to malleus versus lateral to malleus : Indian J. Otol. June 2015; 67(2),173-174.