



Article info

Received : 03-06-2023
Accepted : 07-10-2023
No. of Tables : 45
No. of Figure : 01
No. of References : 18

Original Article

Outcome of Management of Impacted Foreign Body in Upper Aero-digestive Tract

Karim MR¹, Noor-E-As Sayed AHM², Siddiqui MM³, Anwar RT⁴, Hossen MI⁵, Kazi MM⁶

Abstract:

Background: Foreign body ingestion is a serious health problem in pediatric patients causing significant morbidity and mortality. A high index of suspicion and timely intervention can reduce morbidity as well as mortality especially in the pediatric age group. Time lag between the aspiration and expert attention is very important with regard to overall morbidity and mortality. Complications depend on its type, its localization and the duration of impaction. Large objects in the laryngotracheobronchial tree can cause obstruction to air passage leading to life threatening complications.

Methods: This Prospective study was conducted at the department of ENT & head neck surgery, Dhaka Medical College Hospital for six months from December 2020 to May 2021. Patients attending in the study site with complaints of H/O ingestion of foreign body for inclusion of the study and final selection were done in according to the selection criteria inclusion was confirmed following signing written informed consent.

Results: Hundred patients were seen at the study center during the period. All were emergencies patients with foreign bodies in upper aerodigestive tract come to ENT & HNS dept. Majority of the patients of impacted esophageal foreign bodies represent pain, drooling of saliva. Females (38%) and males (62%), with a male to female ratio of 1.6:1. Sixty five (65%) patients had X-ray of the soft tissue neck (B/V), which was the main diagnostic tool. Ninety five (95%) patients were discharged after an uneventful postoperative recovery except post-operative pain, laceration of mucosa causes mild bleeding, erosion of nasal turbinate, vestibule, septal perforation & pyrexia from either the impacted foreign body or the procedure performed, which were managed by NG tube feeding, I/V antibiotic, medicated nasal pack conservatively. In this study, complication rate of 5% was recorded, about 50% of which was from impacted coin (in GIT). There were no cardiac arrest and death were recorded. Hospital stay ranged from a day to 7 days.

Conclusion: FBs in the aero-digestive tract constitute a constant hazard in all age groups especially in children and elderly, which demands immediate action and management, delayed treatment with observation is not recommended.

Cite the Article: Outcome of Management of Impacted Foreign Body in Upper Aero-digestive Tract. Karim MR, Noor-E-As Sayed AHM, Siddiqui MM, Anwar RT, Hossen MI, Kazi MM. Bangladesh J Otorhinolaryngol 2023; 29(2): 96-103.

1. Mohammad Rezaul Karim, Registrar of ENT, Green Life Medical College, green Road, Dhaka
2. AHM Noor-E-As Sayed, Associate Professor of ENT, Dhaka Medical college, Dhaka
3. Mohammad Mamun Siddiqui, Assistant registrar of ENT, Dhaka Medical college, Dhaka
4. Rahat Tanvir Anwar, Assistant registrar of ENT, National Institute of ENT, Dhaka
5. Md. Iqbal Hossen, Assistant Professor of ENT, Anwar Khan Modern Medical college, Dhaka
6. Md. Milon Kazi, Registrar of ENT, Bangladesh Medical College, Dhaka

Correspondence: Md. Mohammad Rezaul Karim, Registrar, Otolaryngology & head neck surgery department, Green Life Medical College, Dhaka. Mobile: 01682827560, 01814483224. E-mail: hmrk18@gmail.com

Introduction:

Foreign bodies (FBs) in Aero-digestive tract are frequent occurrence and may lead to life threatening situation due to obstruction caused in respiratory passages. In adults, food is the most common foreign body of the Aero-digestive tract. Young children exploring their environments with their mouths are at risk for the ingestion and aspiration of small not-edible objects. The types of the FB appear to be closely related to age, and depend on the seasons and each population eating habits. About 75% to 85% of all FBAs occur in children younger than 15 years old; however, most of them are younger than 3 years. Failure of airway protective mechanisms is the most frequent reason of FBAs in adults which is seen mostly in the sixth or seventh decade of life¹. The most commonly ingested foreign bodies by children include coins, screws, buttons, and toys². Bones and food (especially meat), malffitted artificial denture are found almost exclusively in patients of other age groups. According to the localization, coins, foods and sharp objects are the most common FB lodged in the esophagus, vegetables (especially peanuts and seeds) in the airway and bones in the pharynx². The ratio of pediatric patients is high in the cases of tracheobronchial FB¹. For pharyngeal and esophageal FB, the patients involved are from all the age groups. Different types of foreign foodies are founds such as fish bone, coins, peanuts, seeds, toys, plastic, rubber, foam, button, magic ball, chicken bone, food bolus. Accidental sharp object (needles, pins), corrosive containing battery, artificial denture, small lock and key, bobbin, covering of tablet etc. Most esophageal FB were encountered in adults. Esophageal foreign bodies may cause a lot of symptoms ranging from odynophagia or dysphagia to complete esophageal obstruction with overflow of secretions and aspiration. Sometimes respiratory distress or stridor occurs due to compression of the trachea wall by large objects lodged in the esophagus.

Foreign body (FB) aspiration and ingestion occurs frequently in children and the

elderly³causing significant morbidity and mortality. A high index of suspicion and timely intervention can reduce morbidity as well as mortality especially in the pediatric age group. Time lag between the ingestion/aspiration and expert attention is very important with regard to overall morbidity and mortality. Complications depends on its type, its localization and the duration of impaction. Large objects in the laryngotracheobronchial tree can cause obstruction to air passage leading to life-threatening complications. Fatal complications such as esophageal perforations, mediastinitis and aorto-oesophageal fistula can occur if ingested FB get impacted in the esophagus as well as during removal of FB². Sharp objects can cause lacerations to the luminal wall, penetrate the mucosa and migrate extra luminal. Batteries contain corrosive substances and may cause necrosis of the mucosa in case of leakage and chronic impaction can lead to atelectasis, infection, ulceration and necrosis of the mucosa, So delayed treatment with observation is not recommended. During the time, many treatments for removal of airway and esophageal foreign bodies have been proposed but rigid endoscopy has proven to be the safest and most efficient therapy².

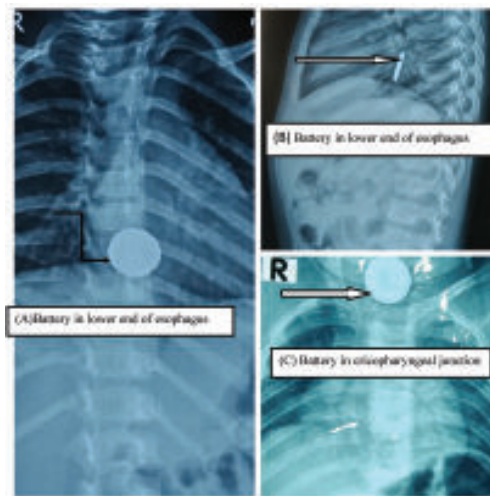
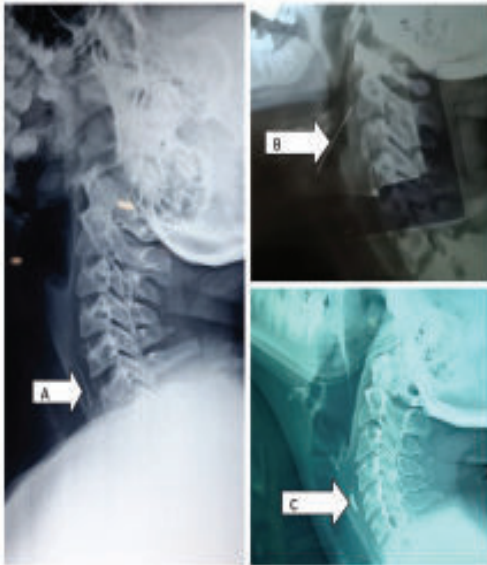
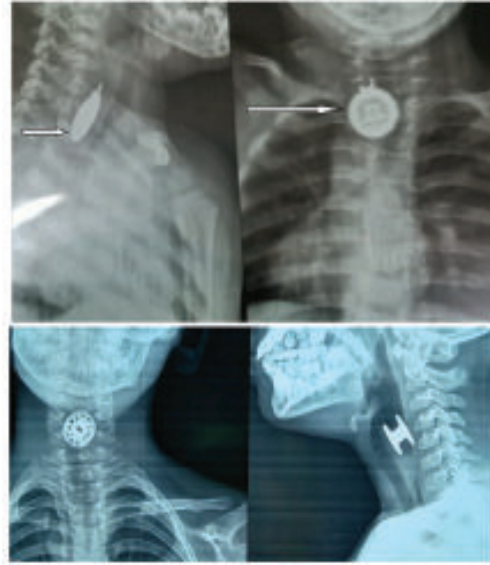

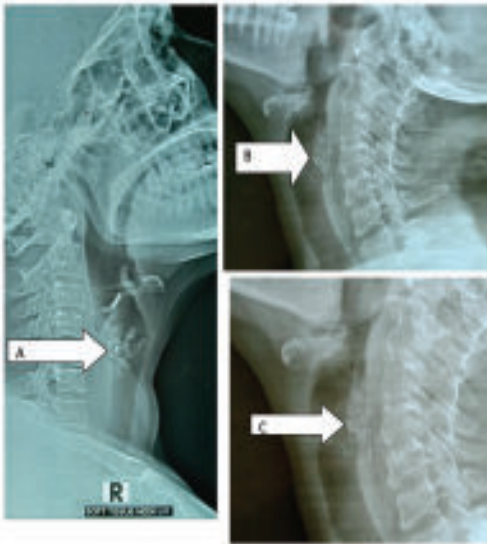
Fig.-1: Fig-A & B, FB (Battery) in lower end of esophagus just above the diaphragm, Fig-C FB (Battery) in upper esophagus.



Picture 2: Fig-A FB (Fish Bone) in cervical vertebrae C6 & C7 regions. Fig-B FB (Pin) in cervical vertebrae C3 to C5 regions, Fig-C, FB (Meat Bone) in cervical vertebrae C6 & C7 regions.



Picture 4: Fig-Above FB (Metallic object) in cervical vertebrae C6 & C7 regions. Fig-Below FB (Bobbin) in cervical vertebrae C3 to C5 regions.



Picture 3: Fig-A FB (artificial denture) in cervical vertebrae C3 & C4 regions. Fig-B FB (Meat bolas) in Cervical vertebrae C3 to C4 regions, Fig-C, FB (Meat bolas) in Cervical vertebrae C3 to C4 regions.

Aims and objectives:

This study was carried out to see the site of impaction, nature of foreign body in the aero-digestive tract and complications during and after management of such FB.

Materials and Methods:

The study has been conducted at Department of ENT & Head-Neck Surgery, Dhaka Medical College Hospital, Dhaka, from December 2020 to May 2021. All the patients who were present with FB in upper aero digestive tract admitted in Department of ENT & Head-Neck Surgery, DMCH fulfilling both inclusion and exclusion criteria have been enrolled by purposive sampling. After admission, written informed consent have been taken from parents or legal guardians in a prescribed form. A thorough history has been taken from each and every study subjects about age,

sex, occupation, personal habits, residence, socioeconomic status and detail symptoms. Also history of past illness, family history, medical history, drug history etc. have been recorded in every study subjects. Thorough examinations of the general conditions of the study subjects have been done. Every case has been subjected to meticulous examination of head-neck region. Site, size, types of foreign body, time of ingestion. Examination of oropharynx, oral cavity, throat, ear, and nose have been done in every cases. Radiological assessment (X-ray soft tissue neck and chest), Complete blood count, ECG, blood sugar and other necessary investigations have been done (If needed).

Statistical Analysis:

Data were collected, compiled and tabulated according to key variables. The analysis of different variable was done according to standard statistical analysis.

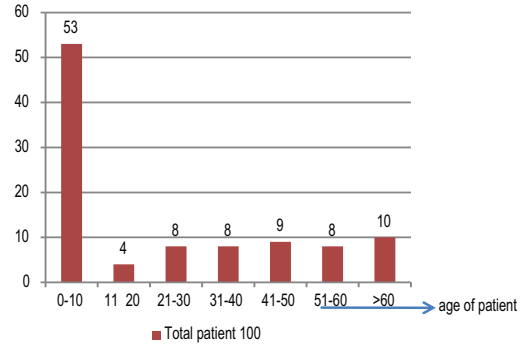


Figure 1 : Different age groups where aero-digestive foreign bodies were seen. (n=100)

Fifty three percent of those presented with aero-digestive foreign bodies to our center were children under 10 years of age. It shows another peak at >60 years age group (10%).

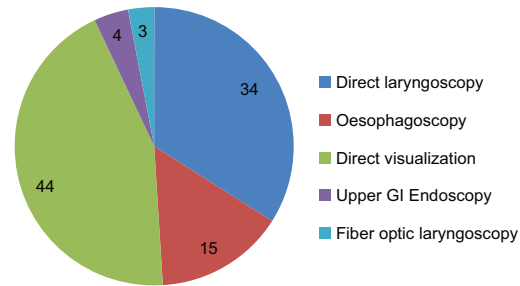


Figure 2: Procedures performed for retrieval of aerodigestive foreign bodies

Types of Foreign Bodies	Frequency	Percentage (%)
Fish Bones	28	28
Coins	21	21
Peanuts, Seeds, Beans	9	9
Rubber, foam, Button, magic ball	8	8
chicken Bones & meat bolas	11	11
Battery	6	6
Sharp objects (needles, pins...)	3	3
Toy parts, plastic objects	2	2
Metallic objects	1	1
Artificial danture	7	7
Miscellaneous	4	4
Total	100	100

Table II: Relationship between age of the patient and site of impaction of foreign bodies (n=100)

Table III: Relation between different types of foreign bodies and site of impaction (n=100)

Types of Foreign Bodies	Nose & Nasopharynx (20)	Oral Cavity & Oropharynx (24)	Larynx (upto-supraglottis) (7)	Cricopharyngeal junction (CPJ) (40)	Mid oesophagus (3)	lower end of oesophagus (6)
Fish Bones(28)	0	21	4	3	0	0
Coins (21)	0	0	0	20	0	1
Peanuts, Seeds, Beans(9)	9	0	0	0	0	0
Chicken Bones & meat bolus(11)	0	0	0	8	0	3
Battery(6)	3	0	0	2	0	1
Sharp objects (needles, pins(3)	0	3	0	0	0	0
Toys, Plastic, rubber, foam, Button, magic ball(10)	8	0	0	2	0	0
Metallic objects(1)	0	0	0	1	0	0
Artificial denture(7)	0	0	0	4	2	1
Miscellaneous(4)	0	0	3	0	1	0

Table IV: Relation between Duration of time and complications

Duration of time (H/O ingestion and presentation)	Number of patients	Ulceration of nasal mucosa & perforation of nasal septum	Retro-pharyngeal abscess	Mild bleeding, laceration of luminal wall (pharynx & esophagus)	esophageal perforation	Tracheo-esophageal fistula, mediastinitis, stricture, mortality
within24hours	91	0	0	0	0	0
24hour-3days	6	1	0	2	1	0
>3days-7days	2	0	0	1	0	0
>7days	1	0	1	1	0	0

Esophageal foreign bodies, majority of the patients presented with pain, drooling of saliva, difficulty in swallowing and respiratory difficulty. Fatal complications due to impaction as well as during removal of FB such as esophageal perforations occur in 1 (one) patient, which managed conservatively and recover. Another patient developed retropharyngeal abscess due to late presentation. Incision and drainage and i/v antibiotic was given and recover. There was no tracheoesophageal fistula, mediastinitis, stricture, mortality in our study.

Table V: Distribution of the studied cases according to radiological finding

	Number	Percentage
Radio opaque FB	46	46
Non Radio opaque FB	19	19

Discussion:

Foreign body in upper aero digestive tract causes serious health problem. A high index of suspicion and timely intervention can reduce morbidity as well as mortality

especially in the pediatric age group. Time lag between the aspiration/ingestion and expert attention is very important with regard to overall morbidity and mortality. All patients were randomly selected, total 100 patients were included and they were subjected to details history taking, physical examination and necessary investigations. Fifty three percent of those presented with aero digestive foreign bodies to our center were children under 10 years of age. It shows another peak at >60years age group (10%)². Nigeria where the most common age group at presentation was 9 months to 3 years^{4,5,6,7} in Turkey found the most affected age group to be under 3 years of age. Fifty-nine per cent of patients presenting with foreign bodies in Benin Nigeria were under 10 years of age⁸. It is not surprising that children under 10 years constitute the majority of our patients bearing in mind that children are so adventurous and usually do want to explore their facial orifices by inserting objects. However, fish bone were the most common (28 patients, 28%) followed by coins (21 patients, 21%) Peanuts, Seeds, Beans (9 patient 9%), Toys, Plastic, rubber, foam, Button, magic ball (10 patient 10%) & then chicken bone & food bolus (11patients, 11%). Accidental sharp object (needles, pins) ingestion was present in 3 patients. Button battery were found in six patients (in nasopharynx & GIT) each, (6%), followed by artificial denture in 7 patients. Small lock and key, bobbin, covering of tablet were present in 4 patients for each (4%).The second peak seen among those in the >60 years age bracket could be explained possibly by the increasing benign and or malignant esophageal conditions seen in the age bracket, especially in the developing world where malignancy age is observed to be about 10 years less than what is obtainable in the developed world. As regards types of FB ingestion Sixty two patients were males (62%) and thirty eight patients were females (38%),

showed male preponderance, with a male to female ratio of 1.6:1. This finding is similar with the work of Kaduna Nigeria showed male to female ratio of 2.2:1^{2,9,10,11,12}. However, did not find significant gender difference in some studies^{3,5,6,7}. The male preponderance found in this study could be attributed to the aggressiveness of the males. Thirty six (36%) of our patients had esophageal foreign bodies. Anatomically, the esophagus has its narrowest part at the region of the cricopharyngeous, demarcating the hypopharynx and the esophagus; the narrowing makes the area susceptible for foreign body impaction. In Port Harcourt Nigeria who found 66% in their series being esophageal foreign bodies⁹, where over 50% of the aerodigestive foreign bodies were impacted in the pharyngo-esophageal region². However, in Benin Nigeria found only 8.3% of ENT foreign bodies in the esophagus⁸. The low number of esophageal foreign bodies could be the inclusion of nasal foreign bodies within the study population. Ninety two (91%) of the patients presented to the health facility within the first 24 h of ingestion of the foreign body, that was quite impressive while (6%) patients presented after the first 24 h, probably due to the distance from the facility. Time of presentation of an esophageal foreign body after about 3 days of ingestion, associated with mortality as a complication. The maximum duration of 7 years from impaction of esophageal foreign body to presentation^{10,11}. However, in Calabar Nigeria reported 7 weeks period from ingestion of foreign body to presentation for care^{12,13}. Complications may arise from late presentation. However, due to awareness campaign on the services of the study center, majority of the patients enrolled for the study presented to the facility within the first 24 h of ingestion. Esophageal foreign bodies, it is worthy of note that the majority of the patients presented with impacted esophageal foreign

bodies, with associated pain, drooling of saliva, difficulty in swallowing and respiratory difficulty^{9,14}.

Sixty five (65%) patients had X-ray of the soft tissue neck (anteroposterior and lateral views) and the chest X-ray including upper abdomen was suggestive of aero digestive foreign body in (19%) of the patients. Plain radiographs proved very useful in the evaluation of patients with suspected aero digestive foreign bodies, especially in developing countries where the full radiologic facilities are not usually available in health centers. The sensitivity and specificity of plain radiographs in evaluating esophageal foreign body to be 54.8% and 100%, respectively¹⁵.

Direct laryngoscopy and foreign body removal was done in (34%) patients, esophagostomy and foreign body removal was performed in (15%) patients. Rigid scopes, though not encouraged for removal of aero digestive foreign bodies are found handy in Nigeria. Fiberoptic scopes are the only acceptable intervention for objects that have been impacted for more than a few hours, sharp objects such as flange of dentures, button batteries, and those that are not smooth or inert^{14,16}. Thus, flexible scopes are superior to rigid scopes in the setting of distally wedged foreign bodies; however, the scopes are in most instances, not available in most healthcare facilities in the developing countries. In this study, fish bone accounted for a larger proportion of the aero digestive foreign bodies, followed by impacted coin (21%), meat bolus (11%). In Pakistan where coins (55.6%) and meat bolus (20.7%) accounted for the foreign bodies^{5,6,7,10,11}, where found coins, peanuts, toys among the most commonly ingested foreign bodies. Reason for Fish bone being a significant contributor of impacted foreign bodies in our series could be because our study population consisted of both the adults and pediatric age groups.

Retrieval of aero digestive foreign bodies could be with complications. In this study, complication rate of 5% was recorded, about 50% of which was from impacted denture material. This appears to be slightly higher than other study^{5,17}, reported 2-6%. & did not report any complication¹⁰. However, complication rate of 14%⁸, which was attributed to late presentation. There is increased the incidence of complications with advancing age over 10 years of age¹⁸. Ninety five (95%) patients were discharged after an uneventful postoperative recovery except post-operative pain, laceration of mucosa or luminal wall causes mild bleeding, erosion of nasal turbinate, vestibule, septal perforation & pyrexia from either the impacted foreign body or the procedure performed, which were managed by NG tube feeding, I/V antibiotic, medicated nasal pack conservatively. In this study, complication rate of 5% was recorded, about 50% of which was from impacted coin & battery in pediatric age group and impacted denture material & meat bolas in case of adult. Removal through the rigid endoscope (Direct Laryngoscopy) is the most reliable method for esophageal foreign bodies. Thirty six patients (36%) of esophageal foreign bodies were present in cricopharyngeal junction. Fatal complications due to impaction as well as during removal of FB such as esophageal perforations occur in 1 patient, which manage conservatively and recover. Another patient develop retro-pharyngeal abscess due to late presentation, incision & drainage given and i/v antibiotic and patient recover. There was no tracheo-esophageal fistula, mediastinitis, stricture, cardiac arrest, and death were recorded.

Hospital stay ranged from a day to 7 days; mean duration was 4 ± 4.08 days, reported the maximum period of hospitalization as 32 days, with a mean of 9.4 days¹².

Conclusion:

FBs in the aero-digestive tract constitute a constant hazard in all age groups especially in children and elderly, which demands immediate action and management. Aero digestive foreign bodies pose a serious challenge in the setting of a poor resource country with death of diagnostic and interventional facilities. Late presentation and advancing age are associated with complications..

References:

1. Dikensoy, C., Usalan, C., and Filiz, A. Foreign body aspiration: clinical utility of flexible bronchoscopy. *Postgrad Med J.* Jul.2002; 78(921): 399–403.
2. Kirfi AM, Mohammed GM, Abubakar TS, Labaran AS, Samdi MT, Fufore MB. Clinical profile and management of aerodigestive foreign bodies in North - western Nigeria. *Sudan Med Monit.*2014;9:39-43
3. Hariga, I., Khamassi, K., Zribi, s., Amor, M., B. Gamra, O., B. Mbarek, C., and Khedim, A., E.Management of Foreign Bodies in the Aerodigestive Tract. *Indian J Otolaryngol Head Neck Surg.*2012 38
4. Higo R, Matsumoto Y, Ichimura K, Kaga K.Foreign bodies in the aerodigestive tract in pediatric patients. *Auris Nasus Larynx* 2003;30:397-401.
5. Mahafza T, Batiha A, Suboh M, Khrais T. Esophageal foreign bodies: A Jordanian experience. *Int J Pediatr Otorhinolaryngol.*2002;64:225-7.
6. Fatma O, Agop C, Emin U, Sidal M. Airway foreign bodies in childhood. *Int J Pediatr Otorhinolaryngol.*2000;52:11-6.
7. Al-Qudah A, Daradkeh S, Abu-Khalaf M. Esophageal foreign bodies. *Eur J Cardiothorac Surg.*1998;13:494-8
8. Onyegwara N, Okhahku A, Emokpaire E, Ogisi F.Dynamics in the trend of foreign bodies in ENT practice in Nigeria: Any change? *Internet J Otorhinolaryngol* 2012;14:2
9. Onotai LO, Ibekwe MU.A Survey of upper aerodigestive tract emergencies seen in a Nigerian tertiary hospital. *Int J Med Med Sci* 2012;2:92-6. 39
10. Iseh KR, Oyedepo OB, Aliyu D. Pharyngo-oesophageal foreign bodies: Implications for health care services in Nigeria. *Ann Afr Med.*2006;5:52-5.
11. Gulshan H, Mahid I, Ihsanulla H, Mohammed H, Sharafat A. Esophageal foreign bodies: An experience with rigid esophagoscope. *Gomal J Med Sci.*2010;8:218-20
12. Nwaorgu OG, Onakoya PA, Sogebi OA, Kokong DD, Dosumu OO.Esophageal impacted dentures. *J Natl Med Assoc.*2004;96:1350-3.
13. Umana AN, Offiong ME, Atana UE, Francis P, Adekanye GA, Mgbe RB. Foreign body (Disk Battery) in the oesophagus mimicking respiratory problem in a 13 months old baby–delayed diagnosis. *J Med Med Sci.*2011;2:714-7.
14. Majori M, Fecci L, Monica M, Casalini AG. Airway foreign bodies. *Monaldi Arch Chest Dis.*2011;75:86-8.
15. Akazawa Y, Watanabe S, Nobukiyo S, Iwatake H, Seki Y, Umehara T.The management of possible fishbone ingestion. *Auris Nasus Larynx.* 2004; 31:413-6
16. Keith MR. Esophageal foreign bodies. *Am Fam Physician.* 2014;44:824-31.
17. Singh B, Kantu M, Har E, Lucente FE. Complications associated with 327 foreign bodies of the pharynx, larynx and esophagus. *Ann Otol Rhinol Laryngol.*1997;106:301-4.
18. Alabi BS, Oyinloye OI, Omokanye HK, Afolabi OA, Dunmade AD, Akande HJ. Foreign bodies in the upper aerodigestive tract of Nigerian children. *Niger J Surg.* 2011;17:78-81.