

## **Original Article**

---

# **Endoscopic transnasal repair of CSF rhinorrhea: Techniques and out come**

Forhad Hossain Chowdhury<sup>1</sup>, Md. Raziul Haque<sup>2</sup>, Md. Shafiqul Islam<sup>3</sup>  
Khandkar Ali Kawsar<sup>4</sup>, Mainul Haque Sarkar<sup>5</sup>

### **Abstract:**

*Background: Endoscopic transnasal repair of CSF (Cerebro Spinal Fluid) fistula is safe, effective and widely accepted minimally invasive procedure. We describe our experience of techniques and result of endonasal CSF fistula repair along with its safety and effectiveness as well as low complications.*

*Method: All patients who underwent endonasal CSF fistula repair from July '07 to September '09 in the department of Neurosurgery, Dhaka Medical College Hospital & Islami Bank Central Hospital, Dhaka, Bangladesh were prospectively analyzed. Patients were followed up for average period of 10.2 months (Range: 3 to 30 months).*

*Results: The age range was 12 years to 55 years; male -female ratio was 5:8. Clinical features were single nose rhinorrhea, double nose rhinorrhea, anosmia, history of trauma, history of transsphenoidal pituitary surgery, recurrent meningitis, aspiration pneumonia and insomnia, obesity and skeletal dysplasia. Etiology of CSF Fistula were idiopathic-06, congenital hydrocephalus-01, post head injury (traumatic)-05 and post surgical-01 case. Anatomical sites of fistula that we found in our series were cribriform plate-06, posterior ethmoidal-04, planum sphenoidale-02 and sellar-01. Post operatively, 2 patients complained of foul smelling within nose and 1 case had persistent CSF rhinorrhoea, where we over looked a frontal sinus fistula and was closed transcranially later on. There was partial nasal obstruction in 01 case that resolved after a year. New anosmia developed in 01 case after operation. Mortality was nil. Out of 13 transnasal endoscopic repair of CSF fistula 12 cured and 01 persisted (that was retreated by transcranial approach)*

*Conclusion: Endoscopic transnasal CSF fistula repair is associated high success rate of fistula closure along with very few complications; at the same time it is minimally invasive, less traumatic and patient-friendly. So it is our notion that it should be the preferred approach to CSF fistula due to defect in anterior skull base and sellar floor.*

**Key Words:** Endoscopic Transnasal; CSF fistula; CSF rhinorrhea.

- 
1. Neurosurgeon, Department of Neuro-surgery, Dhaka Medical College Hospital, Dhaka, Bangladesh.
  2. Associate Professor, Department of Neurosurgery, Dhaka Medical College Hospital, Dhaka, Bangladesh.
  3. Neurosurgeon, Department of Neurosurgery, Dhaka Medical College Hospital, Dhaka, Bangladesh.
  4. Neurosurgeon, Department of Neurosurgery, Dhaka Medical College Hospital, Dhaka, Bangladesh.
  5. Professor, Department of Neurosurgery, Dhaka Medical College Hospital, Dhaka, Bangladesh.

**Address for correspondence:** Dr. Forhad Hossain Chowdhury, Neurosurgeon, Department of Neuro-surgery, Dhaka Medical College Hospital, Dhaka, Bangladesh. E-mail- forhadchowdhury@yahoo.com

### Introduction:

CSF (Cerebro Spinal Fluid) rhinorrhea and otorrhoea occurs after breakdown of all the barriers that separate the CSF from the nose, paranasal sinuses and the middle air<sup>1</sup>. Ommaya<sup>2</sup> classified CSF rhinorrhea as idiopathic, congenital (meningocele, meningoencephalocele, skull base defect, congenital hydrocephalus), postsurgical (paranasal sinus surgery, skull base surgery), non surgical traumatic (Closed head injuries, open or penetrating injuries, post traumatic hydrocephalus) and secondary due to inflammatory, infective or neoplastic lesions invading the skull base. Often conservative measures, such as bed rest, rising of head, avoiding strenuous activities, drug treatment or lumbar subarachnoid drain may lead to improvement in CSF rhinorrhea.<sup>3</sup> Surgical treatment is indicated when a CSF fistula do not respond to this procedures, when a CSF leak is identified during endonasal surgery and infective meningitis is found to be secondary to a fistula.<sup>1</sup> In this article, we describe our experience of techniques and result of endonasal CSF fistula repair along with its safety and effectiveness as well as we want to bring to light its less complications.

### Method:

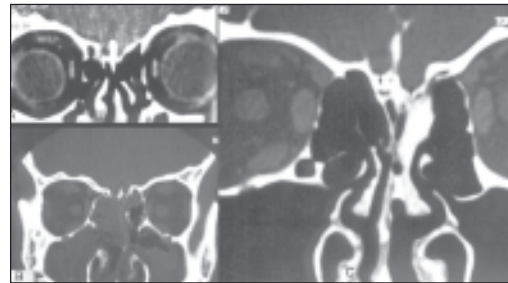
All patients who underwent endonasal CSF fistula repair from July '07 to September '09 in the department of Neurosurgery, Dhaka Medical College Hospital & Islami Bank Central Hospital, Dhaka Bangladesh were prospectively analyzed for clinical features, investigations, causes (aetiology), results and complications.

### Operative techniques:

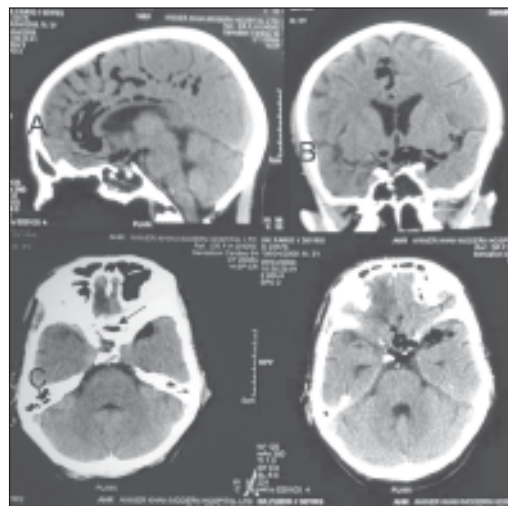
Preoperative Details:

Preoperative CT (Computed Tomogram) scans in the coronal plane were thoroughly

reviewed prior to the start of the case. A review of critical anatomy should be performed. This includes identifying areas of the skull base prone to injury and spontaneous defects: posterior table of the frontal sinus near the frontal recess, the cribriform plate and fovea ethmoidalis, the planum sphenoidale, and, if present, the lateral recess of the sphenoid sinus (Figure-1 & 2).

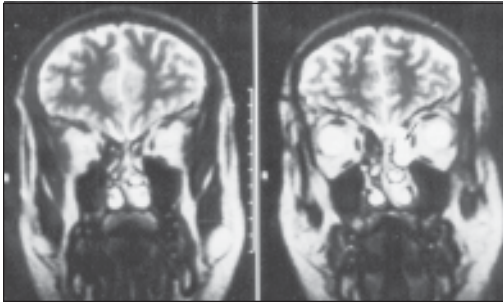


**Figure-1:** A, B & C Coronal CT scan (Bony window) showing bony defect site through the cribriform plate of ethmoid in a CSF rhinorrhea patient.



**Figure-2:** CT scan of Brain A-Sagittal section, B- Coronal Section, C-axial section showing bony defect in planum sphenoidale in CSF rhinorrhea patient with pneumoencephalus.

We investigated with MRI (Magnetic Resonance Imaging) of brain in all cases. After careful study of T1 and T2 images we could trace the CSF fistula in all cases (Figure-3).

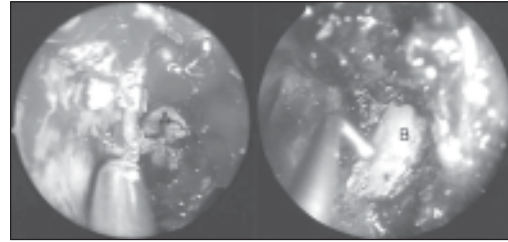


**Figure-3:** MRI of brain coronal section T2 weighted image showing CSF fistulas tract through cribriform plate.

#### Peroperative details:

Patient is positioned in supine position with head turned to surgeon and head end is elevated for 20°. 0° 3 mm neuroendoscope is introduced into nasal cavity for inspection and placement of cotton for decongestion of mucosa. Nasal cavity is decongested by placing a topical oxymetazoline and 1% lidocaine with 1:100,000 epinephrine soaked cotton at the root of the middle turbinate for 10 minutes after endotracheal intubation and placement of nasopharyngeal pack. It helps to vasoconstriction in these areas and helps to minimize bleeding.

For CSF fistula, through cribriform plate we only go for middle turbinectomy on the respective side but for more posteriorly placed fistula we routinely do respective ethmoidectomy. For planum sphenoidale or sellar fistula we do ethmoidectomy and sphenoidotomy. After identification and skeletonization of bony gap (Figure-4A) we skeletonize the dural gap by separating its margins from bone and some time from glottic brain. Then we place a well prepared fascia lata graft in the gap as an inlay graft followed by spongostan film layer along with free middle turbinate graft or sometime bone from nasal septum (excised middle turbinate; Figure-4B).



**Figure-4:** An Endoscopic endonasal view showing bony defect of the CSF fistula, B- Bone graft at bony defect of CSF fistula.

Finally we place a fairly large fat graft harvested from thigh. All layers are supported by inflation of balloon of Foley's catheter in the nasal cavity for 96 hours. A lumbar drain is introduced at the end of operation for continuous CSF drainage for 96 hours and it is kept at bed level, so that it can drain 10-15ml CSF hourly. Postoperatively the patient's bed is elevated 15° at the head end.

#### Results:

Age range were 12 years to 55 years, male female ratio was 5:8.

#### Clinical features were:

Single nose rhinorrhea - 11 cases,  
 Double nose rhinorrhea - 02 cases,  
 Anosmia - 02 cases,  
 History of trauma in 05 cases,  
 History of transsphenoidal pituitary surgery - 01 cases,  
 Recurrent meningitis- 03 cases,  
 Aspiration pneumonia and insomnia - 01 case,  
 Obesity - 03 cases and  
 Skeletal dysplasia - 01 case.

#### Investigations:

CT scan of brain (with thin cut coronal bone window)-12 cases  
 MRI of brain-13 cases

**Etiology of CSF Fistula-**

Idiopathic-06  
 Congenital hydrocephalus-01  
 Post traumatic head injury - 05  
 Post surgical-01

**Anatomical sites of fistula-**

Cribriform plate-06  
 Posterior ethmoidal-04  
 Planum sphenoidale-02  
 Sellar-01

**Complications:**

Complaint of foul smell within nose - 02 cases  
 Persistent CSF rhinorrhoea - 01 case (here we over looked a frontal sinus fistula, which was closed transcranially, later on)  
 Partial nasal obstruction-01 case (disappeared after one year)  
 Anosmia - 01 case (developed postoperatively)  
 Mortality - Nil

**Final results of closure of fistula:**

Closed-12 cases (92.3%)  
 Failed-01 cases (7.7%)

**Table-I***Details of individual cases of the series:*

Case No.	Age (years)	sex	Clinical features & etiology	Anatomical sites of fistula	Investigation	Complication	Result of closure
01	29	F	Rt. N. rhinorrhea. Idiopathic	Posterior. ethmoidal	CT,MRI	Partial nasal obstruction	Closed
02	55	F	Lt. N. rhinorrhea, obesity. Idiopathic	Cribriform plate	CT, MRI	None	Closed
03	12	M	Rt. N. rhinorrhea. Traumatic	Cribriform plate & frontal sinus	CT,MRI	Recurred	Failed (Transcranial repair done)
04	35	M	Binasal rhinorrhea. Traumatic	Planum sphenoidale	CT,MRI	Anosmia	Closed
05	42	F	Rt Nrhinorrhea , obesity. Idiopathic	Posterior ethmoidal	CT, MR	Foul smelling in nose	Closed
06	28	M	Rt N rhinorrhea, meningitis, skeletal dysplasia. Idiopathic	Cribriform plate	CT,MRI	None	Closed
07	49	M	Lt N rhinorrhea , H/O Trauma. Traumatic	Cribriform plate	CT,MRI	None	Closed
08	37	F	Bilateral rhinorrhea, obesity, recurrent meningitis. Idiopathic	Cribriform plate	CT,MRI	None	Closed
09	44	F	Rt N rhinorrhea, Aspiration pneumonia, Insomnia. Idiopathic	Posterior ethmoidal	CT,MRI	None	Closed

[F-female, M-male, Rt-right, Lt-left, N-nasal, H/O-history of, V-P-ventriculo peritoneal, CT-computed tomography of brain, MRI-magnetic resonance image of brain]

**Discussion:**

In spite of the fact that CSF leaks are relatively uncommon, and though it seems to be a straightforward problem, it remains to be one of the most challenging issues to the neurosurgeons.<sup>4</sup>

The actual risk for a patient with CSF leak to develop meningitis ranges from 4-50% as reported by various series.<sup>5,6</sup> Post-meningitic sequelae can be devastating to the patient and the use of prophylactic antibiotics to reduce its risk has not been effective.<sup>6,7</sup> Thus, faced with a persistent leak it becomes of paramount importance to confirm the leak and localise the defect in the skull base. In our series we found that Female is relatively common sufferer and most of the time the cause is idiopathic whereas in male traumatic cause is common. Radiologic diagnostic testing is very important in mapping CSF fistula in the skull base. Thin cut coronal CT scans of the paranasal sinuses and the cribriform plate is used to map the fistula in our 12 cases where it successfully demonstrates the bony defect. In one case where post pituitary surgery CSF fistula developed we had not gone for CT scan. Nabawi, was successful in demonstrating the site of CSF leak by CT - metrizamide in approximately 70 to 85% of his cases.<sup>8</sup> MRI was performed in all of our cases. After careful study of all images we successfully delineated CSF fistulous tract that helped us in planning of surgery a lot.

Currently, intracranial, extracranial and endoscopic transnasal approaches are used to repair nasal CSF leak. Intracranial approach with bifrontal craniotomy is today, limited to those cases with large bony defects or when posterior frontal sinus wall is damaged. The success rate of this technique ranges from 50% to 73%. Anosmia, post operative intracerebral haematoma, cerebral edema, epilepsy, frontal lobe dysfunction and

osteomyelitis of the frontal bone flap are the main complications. The success rate of the extracranial approach, generally used in repairing frontal sinus leak, ranges from 75% to 86%, the main drawback being facial scarring.<sup>1</sup>

First extracranial approach for repair of CSF fistula was reported by Dohlman in 1984.<sup>9</sup> The optimal surgical technique should achieve a high success rate with minimum complication. For this reason, endoscopic transnasal repair of CSF fistula gained popularity during the last few years. In this series all fistulas were closed using transnasal endoscopic techniques.

We confirmed suspected intra-operative leak by elevating the head of the patients by asking the anaesthesiologist to perform the valsalva manoeuvre (increasing intrathoracic pressure) that would cause a transient elevation of intracranial pressure, and may thereby accelerate CSF leakage. We did not use intrathecal fluorescein injection for identification of the leak.

Fibrin glue is used by some neurosurgeon to hold the graft in position. But we did not use it in any of our case. We had a high success rate in this series from the first attempt (12/13). None had a second endoscopic trial at closure of a recurrent leak. In the unsuccessful case, where the leak persisted (Due to missed frontal sinus fistula) we closed the fistula through transcranial rout. Success rate of repair rate at first attempt of 92.3% compares favourably with other reported series.<sup>10,11</sup> Variable success rates from craniotomies to repair such fistulae have been reported low as 60% by another study.<sup>12,13</sup> Arabi and Hubbard have demonstrated that management of CSF leaks using intracranial routes might be associated with failure rate ranging between 20-40%.<sup>12,13</sup> High success rate has been reported using other extracranial

non-endoscopic techniques.<sup>10,14,15</sup> Another study reported on the largest series of endoscopic repairs, achieving control of CSF leak in 75.9% after the first endoscopic attempt and up to 86.2% after a second attempt.<sup>16</sup>

Autologous tissues, such as fascia lata, excised middle turbinate, thigh fat were used in our patients. Stored, processed, radiated or otherwise commercially prepared tissues were not used. Vascularised tissues such as septal and middle turbinate mucosal flaps were not used in our series. Transnasal endoscopic repair of CSF fistula associated with high success rate and minimal degree of morbidity compared to intracranial approaches.<sup>4</sup> In our series, we found transnasal endoscopic CSF fistula repair is associated with high success rate with negligible complication. We feel, it should be the preferred approach to all patients with anterior skull base defect and sellar defect.

#### Conclusion:

Endoscopic transnasal CSF fistula repair is associated high success rate of fistula closure along with very few complications; at the same time it is minimally invasive, less traumatic and patient-friendly. So it is our feeling that it should be the preferred approach to CSF fistula due to defect in anterior skull base and sellar floor.

#### References:

1. Paludetti G, Sergi B, Rigante M, Campioni P, Galli J. New techniques and technology to repair cerebrospinal fluid rhinorrhea. *Acta Otorhinolaryngol Otol* 2004; 24:130-134.
2. Ommaya AK. Spinal fluid fistulae. *Clin Otolaryngol* 1983; 8: 317 - 27.
3. Schlosser RJ, Bogler WE. Nasal cerebrospinal fluid leak. *J Otolaryngol* 2002; 31: 28-37.
4. Hadi U, Kahwagi G, Hamdan AL, Shreif J, Haddad G. Endoscopic management of cerebrospinal fluid leak-A viable alternative. *Panarab Journals* 2000; 4: 12 - 16.
5. Brisman P, Hughes JEO, Mount LA. Cerebrospinal fluid rhinorrhea. *Arch Neurol* 1970; 22: 245 - 252.
6. MacGee EE, Cauthren JC, Brackett CE. Meningitis following acute traumatic cerebrospinal fluid fistula. *J Neurosurg* 1970; 33: 312 – 316.
7. Klustersky J, Sadeghi M, Brihaye J. Antimicrobial prophylaxis in patients with rhinorrhea or otorrhea: A double blind study. *Surg Neurol* 1976; 6: 111 - 114.
8. Nabawi P, Mafree M, Philips J, et al. The success rate of metrizamide CT cisternography in the evaluation of cerebrospinal fluid (CSF) rhinorrhea. *Comput Radiol* 1982; 6: 343 - 354.
9. Kundu I. Cerebrospinal fluid rhinorrhea-transnasal endoscopic repair. *Indian Journal of Otolaryngology -Head and Neck Surgery* 2005; 57: 296 – 297.
10. Burns JA, Dodson EE, Ross CW. Transnasal endoscopic repair of cranionasal fistulae: A refined technique with long-term follow up. *Laryngoscope* 1996; 106: 1080 - 1083.
11. Papay FA, Maggiano H, Dominquez S, Hassenback SJ, Levine HL, Lavertu P. Rigid endoscopic repair of paranasal sinus cerebrospinal fluid fistulas, *Laryngoscope* 1989; 99: 1195 - 1201.
12. Hubbard JL, McDonald TC, Pearson BW, et al. Spontaneous cerebrospinal fluid rhinorrhea: evolving concepts in diagnosis and management based on the Mayo Clinic experience from 1970 to 1981. *Neurosurg* 1985; 16: 314 - 321.

13. Park JI, Strelzow V, Friedman WH. Current management of cerebrospinal fluid rhinorrhea. *Laryngoscope* 1983; 93: 1294 - 1300.
14. Calcaterra TC. Extracranial surgical repair of cerebrospinal rhinorrhea. *Ann Otol* 1980; 9: 108 - 116.
15. Persky MS, Rothstein SG, Breda SD, Cohen NL, Cooper P, Ransohoff J. Extracranial repair of cerebrospinal fluid otorhinorrhea. *Laryngoscope* 1991; 101: 134 - 136.
16. Dodson EE, Gross CW, Swerdloff JL, et al. Transnasal endoscopic repair of cerebrospinal fluid rhinorrhea and skull base defects. A review of twenty-nine cases. *Otolaryngol Head & Neck Surg* 1994; 111: 600 - 605.