

Original Article

Histopathological pattern of malignancy in solitary thyroid nodule

SM Nazmul Huque¹, Mohammad Idrish Ali², Md. Mahmudul Huq³, Sk. Nurul Fattah Rumi³, Md. Abdus Sattar⁴, AF Mohiuddin Khan⁵

Abstract:

Objective: To find out relative frequency and type of malignancy in solitary thyroid nodule (STN).

Methods: This cross sectional study done in the Department of Otolaryngology Head & Neck Surgery, Dhaka Medical College Hospital (DMCH), Dhaka and Bangabandhu Sheikh Mujib Medical University (BSMMU), Dhaka during the period of July 2008 to June 2009. For this study, 118 patients who were admitted a case of solitary thyroid nodule for operation. Diagnosed the case by detailed history, clinical examination, investigations, analyzed data presented by various tables, graphs and figures. Total 118 patients were selected as per described criteria from the Department of otolaryngology and head-neck surgery DMCH & BSMMU, Dhaka from July 2008 to July 2009.

Results: In this study of 118 patients of STN, majority of the patients were within 21-40 years age group with female predominance. In thyroid malignancy male and female ratio was 1:1.75. Among 118 cases of solitary thyroid nodule 22 cases were malignant. Out of 22 malignant cases, 16(73%) were papillary carcinoma, 4(18%) were follicular carcinoma and 2(9%) were anaplastic carcinoma. Thyroid swelling was the common presentation in all cases (100%), some patients also presented with other symptoms like cervical lymphadenopathy in 6 (5.08%) cases, dysphagia 2(1.69%) cases and hoarseness of voice 1(0.85%) case. Study showed very significant difference ($p < 0.01$) between papillary and follicular carcinoma, highly significant difference ($p < 0.001$) between papillary and anaplastic carcinoma. So, papillary carcinoma was more common among all thyroid malignancies in patients with solitary thyroid nodule.

Conclusion: Significant proportion of solitary thyroid nodule (18.65%) was malignant. So, careful assessment of thyroid nodule is important for early diagnosis.

Key words: Solitary thyroid nodule, papillary carcinoma.

1. OSD, DGHS, Dhaka Medical College, Dhaka, Bangladesh.
2. Medical Officer, Department of Otolaryngology - Head & Neck Surgery, BSMMU, Dhaka.
3. OSD, DGHS, BSMMU, Dhaka, Bangladesh.
4. Assistant Professor, Department of Otolaryngology - Head & Neck Surgery, BSMMU, Dhaka, Bangladesh.
5. Professor, Department of ENT, Head & Neck Surgery, DMCH, Dhaka, Bangladesh.

Address for Correspondence: Dr. SM Nazmul Huque, OSD, DGHS, Dhaka Medical College, Dhaka, Bangladesh.

Introduction:

Clinically recognized thyroid carcinoma constitutes less than 1% of human malignant tumours¹. Among them differentiated thyroid carcinomas are the common variety. There are two types of differentiated thyroid carcinoma, papillary and follicular carcinoma.

True solitary thyroid nodule (STN) occurs in 4-7% of the adult population. They are

present in 5% of persons at an average of 60 years. They are more common in female (6.4%) as compared to male (1.5%) and this predisposition exists throughout all age groups^{2,3,4}. In general, a nodule of 1.5 cm diameter is detectable by palpation. Thyroid nodule could be adenoma or malignant neoplasm. Most thyroid nodules are benign hyperplastic lesions, but 10-23% of these are malignant neoplasm in nature^{5,6}.

The incidence of thyroid carcinoma varies in different series⁷. The presence of a solitary thyroid nodule is a risk factor for malignancy. The incidence of malignancy within a clinically solitary thyroid nodule varied widely in the literature i.e. from 10-23.7%^{5,6}.

FNAC is highly sensitive for diagnosis in most cases and plays a crucial role in the selection of patients for operation. It is simple, quick to perform, readily repeated, an excellent patient compliance⁸.

The importance of solitary thyroid nodule lies in the significant risk of malignancy compared with other thyroid swelling. So, proper diagnosis and appropriate treatment of thyroid nodule is mandatory.

The attending patients of these hospitals are from all the corners of the country (both endemic and non endemic area) which are more or less representative of all the head-neck cancer population of Bangladesh.

This study try to correlate the pattern of malignancy in solitary thyroid nodule along with socio-demographic and influence of defined risk factors.

Methods:

This cross sectional study was done in the Department of Otolaryngology - Head &

Neck Surgery, Dhaka Medical College, Dhaka and Bangabandhu Sheikh Mujib Medical University (BSMMU), Dhaka during the period of July 2008 to June 2009. This study included 118 patients who were admitted as a case of solitary thyroid nodule for operation. Diagnosis of the case was done by detailed history, clinical examination, investigations. Data analyzed and presented by various tables and graphs.

Results:

Table I

*Age distribution in relation to sex
(n = 118)*

Age (Year)	No of Patients	Male	Female	Male: Female
<30	46	13	33	1:2.53
30-40	54	13	41	1:3.15
>40	18	12	06	2:20

Table II

*Presenting symptoms of STN
(n = 118)*

Symptoms	No. of Patients	Percentage (%)
Swelling in front of neck	118	100
Cervical lymphadenopathy	6	5.08
Dysphagia	2	1.69
Hoarseness of voice	1	0.85

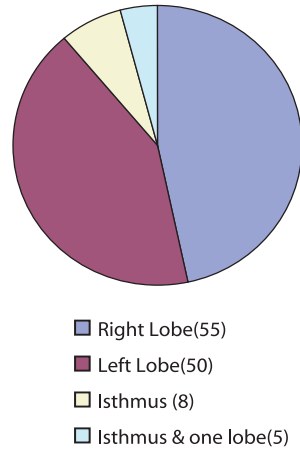


Figure 1: Side of solitary nodule in the thyroid gland (n = 118).

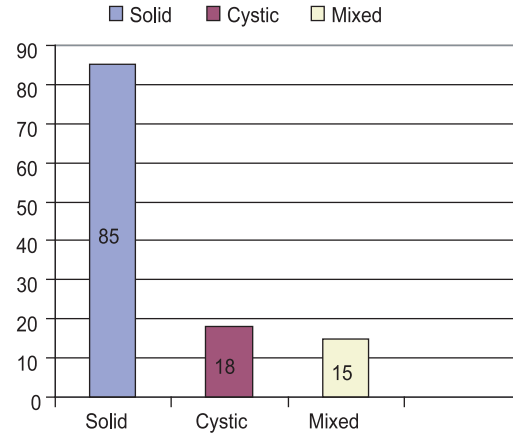


Figure 2: Findings of Ultrasonography (n=118).

Table III
Fine needle aspiration cytology (n=118)

Diagnosis		No of patients	Percentage (%)
Non neoplastic	Colloid nodule	52	44.00
	Colloid degeneration	5	4.24
	Thyroiditis	3	2.54
Neoplastic	Papillary carcinoma	15	12.71
	Anaplastic carcinoma	2	1.69
Cellular follicular lesion		35	29.66
Non conclusive		6	5.08

Table IV
Operation performed (n=118)

Type of surgery	Benigncases	Malignantcases	Percentage(%)
Hemi-thyroidectomy	96	2	83.05
Total thyroidectomy	0	13	11.02
Total thyroidectomy + Neck dissection	0	6	5.08
Completion thyroidectomy	0	4	3.38

Table V
Histopathological diagnosis of STN (n = 118).

Diagnosis		No of patient	Percentage	
Non neoplastic	Nodular goiter	62	52.54	
	Nodular goiter with Thyroiditis	3	2.54	
Neoplastic	Benign	Follicular adenoma	31	26.27
	Malignant	Papillary carcinoma	16	13.55
		Follicular carcinoma	04	3.38
		Anaplastic carcinoma	02	1.69

Table VI*Histopathological correlation between non malignant and malignant lesion (n=118).*

Histopathological diagnosis	No. of Patient	Percentage (%)
Non malignant	96	81.35
Malignant	22	18.65
Total	118	100

Table VII*Pattern of malignancy (n=22).*

Type	No of cases	Percentage
Papillary	16	72.72
Follicular	4	18.18
Anaplastic	2	9.10

Table VIII*Carcinoma in solitary thyroid nodule in relation to age and sex (n=22).*

Age group	Male (n=8)		Female (n=14)	
	No of cases(n)	Percentage(%)	No of cases(n)	Percentage(%)
0-10	0	0	0	0
11-20	0	0	2	9.09
21-30	1	4.55	2	9.09
31-40	3	13.64	5	22.73
41-50	3	13.64	4	18.18
51-60	1	4.55	1	4.55

Discussion:

Carcinoma of the thyroid is the most common malignancy of endocrine system comprises 0.6% and 1.6% of all cases of malignant neoplasm in men and women respectively⁵.

Mean age of the patients of solitary thyroid nodule was 32.54±2.97 years and the highest frequency 54(45.76%) was in 31-40 years. This is similar with the other studies^{2,3,4}. The youngest patient in this study was a girl of 12 years with a papillary carcinoma and the oldest patients was a lady of 65 years with anaplastic carcinoma.

In this series, out of 118 patients, male were 38(32%) and female were 80(68%). Male female ratio is 1: 2.1. This ratio was shown 1:3 by other series^{6 - 10}. The female preponderance is reflected in all studies including the present.

Regarding presenting complaints we have found that all of the patients with neck swelling presents within variable durations. Some patient also presented with other symptoms like cervical lymphadenopathy 6(5.08%), dysphagia 2(1.69%), metastatic bony swelling (sternum) 1(.85%) and hoarseness of voice 1(.85%). Among 22 malignant cases, 20(91%) cases were presented within 2 years. It is well supported by others studies^{11, 12}.

In this series we have seen that right lobe is slightly more affected than left lobe. There is yet no reported predilection for any specific site and no reason has been put forward for such a predilection. We found 55 nodules in right lobe, 50 nodules in left lobe, 8 nodules in isthmus and 5 nodules involving the isthmus and one lobe.

All patients of this study have done thyroid hormone profile and show value within normal

limit. Isotopes scanning of the thyroid gland were done to see the functional status of the nodule. Most of the nodules were cold (66.10%). The incidence of cancer in cold nodule is highly variable; a review of 400 cases found 10% to be cancer¹³.

Firm nodules are the commonest form of solitary thyroid nodule. In this series of solitary thyroid nodules constituted 72.03% firm, 16.95% hard and 11.02% cystic. Malignancy was found more in hard nodule 14(63.63%). It is almost similar to another study 65%⁹. Here hardness of nodule was due to malignancy and inflammatory conditions.

Fine needle aspiration cytology (FNAC) is very important, highly sensitive and minimally invasive preoperative diagnostic tool. In this study 6 FNAC report were not conclusive. 112 FNAC reports were conclusive. FNAC can not distinguish between follicular adenoma and follicular carcinoma. FNAC diagnosis of this series was supported by postoperative histopathological report.

Final diagnosis in this study was on the basis of histopathological confirmation. Out of 118 cases, 65 cases (55.08%) were proven as nodular goitre which is compatible with other studies 54.5% and 53.4%^{11, 14}.

Neoplastic lesion was found in 53 cases (44.92%) out of 118 cases. Out of all neoplastic cases 31(58.41%) was benign (follicular adenoma) and 22 (41.51%) cases were malignant. Malignancy was about 18.65% of all thyroid swelling. Incidence of cancer in solitary thyroid nodule was 23.7%⁶. In this study among 22 malignant cases 16 (72.73%) were papillary carcinoma, 4(18.18%) were follicular carcinoma and 2(9.09%) cases were anaplastic carcinoma. It shows a clear predominance of papillary over follicular and anaplastic carcinoma. According to Watkinson, frequency of papillary carcinoma

is 80% and follicular carcinoma is 10%⁵. It was reported in a study that papillary carcinoma comprises about 60% of all thyroid cancer and follicular carcinoma comprises 18% of all malignant thyroid neoplasm¹⁵⁻¹⁸.

This study showed significant difference ($p < 0.01$) between papillary and follicular carcinoma, highly significant difference ($p < 0.001$) between papillary and anaplastic carcinoma. So, papillary carcinoma was more common among all thyroid malignancies in patients with solitary thyroid nodule.

Conclusion:

Significant proportion of solitary thyroid nodule (18.65%) was malignant. So, careful assessment of thyroid nodule is important for early diagnosis.

References:

1. Alauddin M, Joarder MAH. Management of thyroid carcinoma. Bangladesh J Otorhinolaryngol 2003; 9: 33 – 37.
2. Rahman TM. Study on incidence of malignancy in cold nodule of thyroid in 40 cases. Dissertation, Bangladesh College of Physicians & Surgeons, Dhaka, 2000; 9 – 10.
3. Rains AJH, Charles VM. Bailey and Love's short practice of surgery, Twenty third ed. London, ELBS, 2004; 707 – 733.
4. Sattar MA, Alam MR & Haider A. Clinico-pathological study of solitary cold thyroid nodule, Bangladesh J Otorhinolaryngol. 2003; 9(1): 24 – 27.
5. Watkinson JC, Gaze MN, Wilson JA. Tumours of the thyroid and parathyroid gland, Stell and Maran's Head Neck Surgery, 4th edn. Butterworth Heinemann, 2000; 458 – 484.
6. Inder JC, David HS. Thyroid function test and there alteration by drugs. Thyroid

- nodules clinical nuclear medicine 1977; 2(9): 324 – 333.
7. Block MA, Dailey GE, Robb JA. Thyroid nodule indeterminate by needle biopsy. *Am J Surg* 1983; 20: 113 - 23.
 8. Russell RCG, William NS, Balstrode CJK. Bailey and Love's, Short Practice of Surgery, 24th ed. London, ELBS. 2004; 776 – 804.
 9. Ashraf SA, Matin ASM. 'Review of thyroid diseases in Bangladesh'. *Journal of Bangladesh College of Physicians & Surgeons, Dhaka*, 1994; 2: 5 – 10.
 10. Dudley H, Pories WJ. General Principles, Breast and Extra-cranial endocrines in Rob and Smith's Operative Surgery. 4th London. Butterworth Scientific, 1986; 332 – 386.
 11. Kendel LW, London RE. Prediction of malignancy in a solitary thyroid nodule. *Lancet*, 1969; 1: 1071 – 73.
 12. Harmo J, Clark OH. Significance of lymph node metastasis in differentiated thyroid cancers, *Cancer* 1979; 10(6): 230 – 37.
 13. Santacroce L, Tommaso L. Follicular thyroid carcinoma, last updated 1 State University at Bari, Italy, 2005; 257 – 260.
 14. Browse NL. An Introduction to the Symptoms and Signs of Surgical Disease, 3rd ed. London. ELBS, 1998; 3: 266 – 268.
 15. Shaheen OH. The Thyroid Gland, Scott-Brown's Otolaryngology, 6th ed., vol. 5, Butterworth Heinemann, 1997; 18/1 – 18/24.
 16. Krukowski ZH. The thyroid gland and thyroglossal tract; Baily and love's short practice of surgery; 24th edn. London, 2005; 797 – 98.
 17. Ameer J. Critical evaluation of the test of radio-iodine (¹³¹I) uptake in the thyroid gland (English Abstract). *Vnitřní Lek* 1969; 25(7): 680 – 684.
 18. Robins SL, Cotran US, Kumar V. Pathological Basis of Disease, 6th ed. Philadelphia, WB Saunders Company 2004; 1201 – 1225.